

## CLINICOPATHOLOGICAL STUDY AND MANAGEMENT OF LARGE GUT VOLVULUS WITH REFERENCE TO PRIMARY RESECTION AND ANASTOMOSIS

Siba Prasad Dash<sup>1</sup>, Sekh Ansar Alli<sup>2</sup>

<sup>1</sup>Associate Professor, Department of General Surgery, MKCG MCH, Berhampur.

<sup>2</sup>Resident, Department of General Surgery, MKCG MCH, Berhampur.

### ABSTRACT

#### BACKGROUND

Large gut volvulus is a common surgical emergency in many regions of the world with significant morbidity and mortality. Delay in the diagnosis and treatment can lead to serious complications such as like bowel gangrene, perforation, peritonitis and sepsis. Emergency operation is needed in acute large gut volvulus. The purpose of our study was to analyse the mode of presentations and evaluate the outcome of various methods used in surgical management with reference to primary resection and anastomosis of large gut volvulus, mainly sigmoid volvulus, as it is the commonest type encountered.

#### MATERIALS AND METHODS

This study was conducted in 52 patients with acute sigmoid volvulus randomly out of 214 cases of intestinal obstruction admitted to M.K.C.G. Medical College in the Department of General Surgery from July 2015 to June 2017. Laparotomy were carried out in all 52 patients, primary resection of the affected sigmoid colon with anastomosis in single layer (n=21) and double layer (n=31) were done. Outcome of the two procedures analysed in terms of mortality, postoperative complications and hospital stay.

#### RESULTS

The maximum number of cases were found in between 41 to 60 years of age and male-to-female ratio was 2.7:1. Distention of abdomen (96%) followed by constipation in 90% were common mode of presentation. Postoperative mortality rate of 6%. Common postoperative complication found to be wound infections and a chest infection. It was 27% and 25%, respectively. Mortality and morbidity associated with single layer anastomosis was lower (14.29%) compared with conventional double layer technique (22.58%).

#### CONCLUSION

This study demonstrated that resection and anastomosis should be done in acute sigmoid volvulus safely. Single layer extra mucosal technique is safe and desirable in clinical practice with significant advantages than standard two layer technique.

#### KEYWORDS

Large Gut Volvulus, Primary Resection and Anastomosis.

**HOW TO CITE THIS ARTICLE:** Dash SD, Alli SA. Clinicopathological study and management of large gut volvulus with reference to primary resection and anastomosis. J. Evid. Based Med. Healthc. 2017; 4(88), 5188-5191. DOI: 10.18410/jebmh/2017/1036

#### BACKGROUND

Volvulus of the bowel refers to a condition in which a segment of bowel becomes twisted on its own attachments (mesenteric axis) resulting in complete or partial obstruction of the lumen of both the proximal and distal loops of the segment. Compromised blood supply along with increase in intraluminal pressure leads to ischaemia and gangrene.<sup>1</sup>

The first record of colonic volvulus is found in the Papyrus Ebers 1550 B.C. from ancient Egypt described that

*Financial or Other, Competing Interest: None.  
Submission 19-10-2017, Peer Review 26-10-2017,  
Acceptance 02-11-2017, Published 04-11-2017.*

*Corresponding Author:  
Dr. Sekh Ansar Alli,  
C/o. Dr. S. P. Dash, Lingaraj Nagar,  
Near New Bus Stand, Berhampur,  
District Ganjam, Odisha-760001.  
E-mail: drsibapdash@gmail.com  
DOI: 10.18410/jebmh/2017/1036*



the natural course of volvulus would be spontaneous reduction or "rotting" of the intestine.<sup>2</sup> Sigmoid volvulus, first described by German pathologist Von Rokitsansky in 1836, who described rotation with occlusion of colon.

Worldwide, colonic volvulus is the 3<sup>rd</sup> leading cause of large bowel obstruction.<sup>3</sup> The disease is more prevalent in the "volvulus belt", which includes Middle East, Africa, India, Turkey and South America.<sup>4</sup> In these region, the average age is younger (40-50 yrs.) than western countries (>80 yrs.).<sup>5</sup> In India, it is more common in the states like Bihar, MP, UP and Maharashtra.

In a study of cases of colonic volvulus, it was found that volvulus of sigmoid colon is the most common site (80%), followed by the caecum (15%), the transverse colon (3%) and splenic flexure (2%).<sup>6</sup>

Aetiology of the disease is multifactorial, high fibre and long sigmoid loop with a narrow mesentery leading to a predisposition to torsion and chronic constipation are some of the causes.<sup>7</sup> Acute sigmoid volvulus mainly presented with

abdominal distension, pain abdomen, no bowel movement, and vomiting.

On x-ray of abdomen showing typical coffee bean sign, an inverted ahaustral dilated sigmoid in the shape of an inverted "U" extending into the right upper quadrant is specific to sigmoid volvulus. The appearances have been described as resembling a "bent inner tube."<sup>8</sup>

Simple operative detorsion and various non-respective methods of sigmoid fixation like simple sigmoidopexy, mesocoloplasty and extra peritonealisation have been advocated in the past, but all are associated with high recurrence rate and complications. Blow-hole colostomy without anastomosis (Hartmann's procedures) may play a protective role in avoiding anastomotic leakage particularly when colon is unprepared and grossly infected in elderly patients and haemodynamically unstable patients, but it has disadvantages like multiple stage surgery, high morbidity (5-57%), multiple admissions and social disruptions.<sup>9</sup> Resection and Primary Anastomosis (RPA) has emerged as the treatment of choice for large gut volvulus over the past two centuries.<sup>10</sup> There are many experimental evidence against two layer method suggesting single layer technique to be ideal as it has advantages being less time taking, wide lumen and reduced obstruction to blood flow.

### Aims and Objectives

1. To analyse the epidemiological factors and clinic pathological presentations of large gut (sigmoid) volvulus.
2. Evaluate the outcome of various methods used in surgical management with reference to primary resection and anastomosis of large gut volvulus, mainly sigmoid volvulus, as it is the commonest type encountered.

### MATERIALS AND METHODS

This study was conducted in 52 patients with acute sigmoid volvulus randomly, out of 214 cases of intestinal obstruction admitted to M.K.C.G. Medical College in the Department of General Surgery, from July 2015 to June 2017 as diagnosed by clinically and x-ray of abdomen and ultrasounds of abdomen and pelvis and routine blood investigations. The aetiological factors, which predispose to the sigmoid volvulus, the clinical features, modes of surgery and the postoperative outcomes was observed.

The following scheme was followed in recording the cases.

#### Inclusion Criteria

- Patients with signs and symptoms suggesting of large gut volvulus in cases of intestinal obstruction.

#### Exclusion Criteria

- Patients with chronic large gut obstructions due to malignancy.
- Traumatic perforation of colon.
- The patients who refused to give consent for surgery.
- Paediatrics group, patients unfit for surgery and dropout cases.

All patients at first received adequate fluid resuscitation, broad-spectrum antibiotics and Ryle's tube aspiration decompression. Then, laparotomy were carried out in all 52 patients, primary resection of the affected sigmoid colon with anastomosis. Single layer extra mucosal anastomosis was done in 21 cases, while the rest, 31 cases were managed with conventional double layer anastomosis.

Outcome of the two methods of anastomosis after primary resection analysed in terms of mortality, postoperative complications and hospital stay.

### RESULTS

In this study, majority of patients were predominantly male 38 (73.08%), whereas female 14 (26.92%) and male:female ratio = 2.7:1 (Table 1). Most common affected age group were 41-60 years, 33 cases (63.46%) and least in 71-80 age group, 1 case (1.92%) and 20-30 age group, 2 cases (3.85%) each group.

Most of our patients belonged to low socioeconomic status 37 cases (71.15%) and mainly consumed diet rich in roughage and bulky in quantity. 67.31% of our patients consumed mainly vegetarian diet, 23.08% consumed mixed and the remaining consumed non-vegetarian diet (Table 2).

Out of 52 cases of sigmoid volvulus, distention and constipation were significant symptoms and seen in 50 cases (96.15%) and 47 cases (90.38%) respectively, while pain presented in 38 cases (73.07%). Vomiting, guarding, rigidity and fever symptoms were noticed less (Figure 1).

According to imaging, plain x-ray abdomen detected 46 cases (88.46%) by typical dilated ahaustral sigmoid loop extending upward from pelvis.

In this series, 28 cases were having length of sigmoid colon 40-45 cm and 3 cases were having 25-30 cm length of sigmoid colon, which indicates more the sigmoid colon is elongated, more was the incidence of volvulus.

Intraoperative findings were in RA (resection and anastomosis) group viable bowel 43 cases, gangrene in 9 cases.

Regarding postoperative complications, wound infection was predominant postoperative complication in as many as 26.92% followed by chest complication (i.e., respiratory tract infection), which was 25% and anastomotic leak (19.61%), which increase morbidity and long hospital stay. Other complications, which added longer hospital stay was wound gapping, prolonged paralytic ileus and electrolyte imbalance (Table 3).

Severe leaks lead to death, which occurred in 2 (6.46%) cases of double layered anastomosis due to spreading peritonitis, sepsis (i.e., septicaemia, renal shutdown). In case of single layer anastomosis, it was in the form of 1 case (4.76%) of death in severe leakage. In present study, mortality and morbidity associated with single layer anastomosis was lower, i.e. 5 out of 21 cases (23.81%) compared with conventional double layer technique, i.e. 10 out of 31 cases (32.26%).

Age in Years	Male		Female	
	No. of Cases	%	No. of Cases	%
21-30	2	3.85	0	0
31-40	5	9.61	2	3.85
41-50	15	28.85	5	9.61
51-60	9	17.31	4	7.69
61-70	6	11.54	2	3.85
71-80	1	1.92	1	1.92
<b>Total</b>	<b>38</b>	<b>73.08</b>	<b>14</b>	<b>26.92</b>

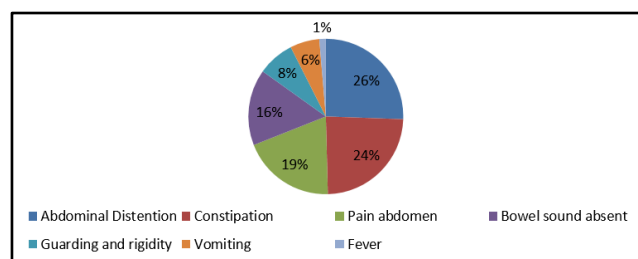
**Table 1. Age and Sex Distribution (n=52)**

Diet	Sigmoid Volvulus	
	No. of Cases	Percentage
Vegetarian	35	67.31
Non-Vegetarian	5	9.61
Mixed	12	23.08

**Table 2. Effect of Nature of Diet on the Occurrence of Volvulus**

Postop Complications	No. of Patients	%
Wound infection	14	26.92
Chest complication (infection)	13	25
Anastomotic leakage	10	19.61
Wound gapping	6	11.54
Prolonged paralytic ileus	3	5.77
Urinary tract infection	1	1.92
Electrolyte imbalance	5	9.61
Mortality	3	5.88

**Table 3. Different Postoperative Complications**



**Figure 1**

**DISCUSSION**

In this study, age of presentation were 41-60 age groups with a male and female ratio 2.7:1. The same observation also reported by De et al (2002), Atamanalp (2013), M. Ramula Durai (2017) and Khanna et al (1999).

In our study, the incidence of sigmoid volvulus is more common in low income group (71.15%), which was in conformity with series of Sinha et al (1969) and Bantu Rajsiddharth et al (2016).

The majority of patients in this series were reported to take vegetarian diet, 4-5 times a day with history of constipation. As per Wuepper et al, large bulky vegetarian diet has been blamed for loading the colon and its elongation.<sup>11</sup>

Patients present with most commonly abdominal distension, pain abdomen, vomiting and constipation. X-ray abdomen can detect 57-90% cases. We also found plain x-ray abdomen detected 88.46% cases.

The mainstay of operation is relieving the obstruction and prevention of complication. To achieve this goal, resection

of the sigmoid colon with anastomosis is treatment of choice as many studies previously failed to show efficacy, prevention of recurrence and complications of conservative and other non-resection surgery such as sigmoidopexy and mesosigmoidoplasty.<sup>12</sup>

In present study, double layer anastomosis is associated with comparatively higher postoperative complication (32.26%) as compared to single layer extra mucosal layer anastomosis (23.81%). This study came out in support of single layer anastomosis in sigmoid volvulus and the same has also been reported by Martin J. Loeb et al in 1967 and T.T. Irvin et al in 1973 and Burch et al in 2000.<sup>13,14</sup>

Anastomotic leak is the most important and dreadful complication in case of primary resection and anastomosis. In our study, postoperative leakage were found to be more in double layer anastomosis (22.58%) as compared with single layer technique (14.28%). Similar study result was evidenced by Goligher et al 1977, Ordorica et al (1998),<sup>15</sup> Garude et al in 2013, Pravin P, Dandi et al (2015).<sup>16</sup>

Mean hospital stay in double layer anastomosis and single layer extra mucosal anastomosis group was accordingly 12 days and 8 days, respectively. It is similar to studies by Oren D et al and Akcan et al.

The overall mortality in our study was 3 cases (5.77%) The mortality was high in double layer anastomosis because of high anastomotic leak, wound infection and absorption of toxins leading to septicaemia and multiorgan failure. However, poor nutritional status, poverty, lack of transport coupled with lack of health consciousness of people and performing surgery in an unprepared gut with faecal loading were possible factors to be blamed.

**CONCLUSION**

In surgery for volvulus, there is no common agreement for procedure. Some prefer two-stage procedures, other advocate primary resection and anastomosis.

Preoperative bowel preparation, the use of intraperitoneal drain, the role of faecal contamination and peritoneal sepsis, blood loss and poor general condition of the patient play important role for anastomotic disruption.

Primary resection and anastomosis reduces the hospital stay and avoid recurrence. Single layer anastomosis is easier, faster, avoid vascular compromise and provide wide lumen and is associated with lesser anastomotic leak resulting less morbidity and mortality.

Though conventional double layer provides inversion technique and good serosal anastomosis, but there is chances of mucosal strangulation due to damage of submucosal vascular plexus, increase luminal narrowing, tissue necrosis and postoperative adhesions.

Today, many surgeons recommend single layer extra mucosal technique, however, the standard two layer technique still remains the popular method among surgeons and gradually there has been a changing trend towards single layer extra mucosal anastomosis technique.

**REFERENCES**

- [1] Bolt DE. The management of volvulus of the sigmoid colon. *British Journal of Surgery* 1956;44(184):172-175.
- [2] Ballantyne GH. Review of sigmoid volvulus: history and results of treatment. *Dis Colon & Rectum* 1982;25(5):494-501.
- [3] Lal SK, Morgenstern R, Vinjirayer EP, et al. Sigmoid volvulus an update. *Gastrointestinal Endoscopy Clinics of North America* 2006;16(1):175-187.
- [4] Gingold D, Murrell Z. Management of colonic volvulus. *Clinics in Colon and Rectal Surgery* 2012;25(4):236-244.
- [5] Heis HA, Bani-Hani KE, Rabadi DK, et al. Sigmoid volvulus in the Middle East. *World Journal of Surgery* 2008;32(3):459-464.
- [6] Halabi WJ, Jafari MD, Kang CY, et al. Colonic volvulus in the United States: trends, outcomes, and predictors of mortality. *Annals of Surgery* 2014;259(2):293-301.
- [7] Margolin DA, Whitlow CB. The pathogenesis and etiology of colonic volvulus. In *Seminars in Colon and Rectal Surgery* 2007;18(1):79-86.
- [8] Rakinic J. *Colonic volvulus*. 2nd edn. New York: Springer 2011:395-406.
- [9] Yassaie O, Thompson-Fawcett M, Rossaak J. Management of sigmoid volvulus: is early surgery justifiable? *ANZ Journal of Surgery* 2013;83(1-2):74-78.
- [10] Foster ME, Leaper DJ, Williamson RC. Changing patterns in colostomy closure: the Bristol experience 1975-1982. *British Journal of Surgery* 1985;72(2):142-145.
- [11] Wuepper KD, Otteman MG, Stahlgren LH. An appraisal of the operative and nonoperative treatment of sigmoid volvulus. *Surgery, Gynecology & Obstetrics* 1966;122(1):84-88.
- [12] Smith SR, Connolly JC, Gilmore OJ. The effect of faecal loading on colonic anastomotic healing. *Br J Surg* 1983;70(1):49-50.
- [13] Irvin TT, Edwards JP. Comparison of single-layer inverting, two-layer inverting, and everting anastomoses. *British Journal of Surgery* 1973;60(6):453-457.
- [14] Burch JM, Fanciose RJ, Moore EE, et al. Single layer continuous versus double layer interrupted intestinal anastomosis. *Ann of Surg* 2000;231(6):832-837.
- [15] Ordorica-Flores RM, Bracho-Blanchet E, Nieto-Zermeño J, et al. Intestinal anastomosis in children: a comparative study between two different techniques. *Journal of Pediatric Surgery* 1998;33(12):1757-1759.
- [16] Dandi PP, Audichya AS, Juneja IA, et al. A prospective comparative study of intestinal anastomosis, single layer extra mucosal versus double layer. *International Journal of Research in Medical Sciences* 2017;3(8):2099-2104.