

Feasibility of Laparoscopic Intraoperative Cholangiogram in Patients with Intermediate Risk for Choledocholithiasis

Adithya G.K.¹, Satya Prakash Jindal², Varun Madaan³, Vachan Hukkeri⁴,
Rigved Gupta⁵, Vivek Tandon⁶, Deepak Govil⁷

^{1, 2, 3, 4, 5, 6, 7} Department of Surgical Gastroenterology, Indraprastha Apollo Hospital, New Delhi, India.

ABSTRACT

BACKGROUND

Intra-Operative Cholangiogram (IOC) is a procedure carried out during cholecystectomy with the primary objective of clearly delineating the biliary anatomy. Over decades, routine IOC became selective IOC and now it is being overtaken by less invasive investigations like MRCP and EUS. Role of IOC remains only to intraoperatively confirm or rule out bile duct injury in difficult cases. Laparoscopic IOC is a skilful procedure which requires training and extra added time during laparoscopic cholecystectomy. Once mastered it can be used in many situations for either anatomical reasons or to detect CBD pathology.

METHODS

All patients getting admitted for laparoscopic cholecystectomy with intermediate risk for choledocholithiasis were enrolled in the study from 2016 to 2019. Procedure was carried out with all necessary consents and precautions. All cases were performed by an experienced GI surgeon and followed up with proper protocol.

RESULTS

Fifty patients with known intermediate risk for choledocholithiasis underwent laparoscopic cholecystectomy with laparoscopic IOC. Procedure was successfully done in all patients except two, where cystic duct was very thin and cannulation was not possible. Forty-one (82%) patients had deranged liver function test and 9 patients (18%) had history of acute pancreatitis in the past as indications for the procedure. Two patients had dilated CBD (>6 mm) on ultrasound along with deranged liver function tests. An average of 12 minutes was taken to perform the procedure (range: 8 - 15 min). In cases where IOC took longer time was mainly due to technical issues (operability of C-arm). No IOC related complications occurred in any of the patients. Hospital stay was not prolonged in any of the patients due to IOC. None of the patients had any filling defect in CBD. All cases followed till date are asymptomatic.

CONCLUSIONS

It is a technically feasible procedure that can be performed with limited addition to OT time, minimal failure rate, and complications. All patients with limited criteria for intermediate risk of choledocholithiasis had a normal IOC with no evidence of biliary obstruction in follow up.

KEYWORDS

Laparoscopic Intraoperative Cholangiogram, Intermediate Risk, CBD Stones

Corresponding Author:

*Dr. Adithya G. K.,
Department of GI Surgery,
Indraprastha Apollo Hospital,
Mathura road, Sarita Vihar,
New Delhi - 110076, India.
E-mail: adi3anny@gmail.com*

DOI: 10.18410/jebmh/2021/21

How to Cite This Article:

*Adithya GK, Jindal SP, Madaan V, et al.
Feasibility of laparoscopic intraoperative
cholangiogram in patients with
intermediate risk for choledocholithiasis.
J Evid Based Med Healthc
2021;8(02):108-114. DOI:
10.18410/jebmh/2021/21*

*Submission 27-06-2020,
Peer Review 10-07-2020,
Acceptance 23-11-2020,
Published 11-01-2021.*

*Copyright © 2021 Adithya G.K. et al. This
is an open access article distributed
under Creative Commons Attribution
License [Attribution 4.0 International (CC
BY 4.0)]*

BACKGROUND

Intraoperative cholangiogram (IOC) is a procedure carried out during cholecystectomy with the primary objective to clearly delineate the biliary anatomy. The history of intraoperative cholangiography (well written by Mac Fadyen¹) began in 1918 where Reich first reported the delineation of the anatomy of the biliary tree by using bismuth and petrolatum to identify a biliary fistula.² The first series of IOC was reported by Mirizzi in 1931. He recommended the routine use of IOC in order to identify unsuspected common bile duct (CBD) injuries.³ Later Hickens and colleagues also advocated its use in 1936.⁴ Since then, surgeons observed an improvement in the results of common bile duct exploration (CBDE) if it was based on filling defects seen on IOC rather than the clinical criteria for CBD exploration commonly used at that time which were history of jaundice, cholangitis or pancreatitis; multiple gallbladder stones; or a dilated common bile duct (CBD). With the use of an IOC, stones were found twice as often during CBDE, and also there was a marked decrease in the frequency of performing CBDE during cholecystectomy.⁵⁻⁸ The initial IOC's were performed using static films and that required an average of 20 - 30 minutes to complete the procedure that often had to be repeated.¹

In current day practice the role of intra operative cholangiogram during routine laparoscopic cholecystectomy remains controversial. Disadvantages of routine IOC include increased cost, operating time, need for technical expertise and false positive results leading to unnecessary CBDE or ERCP.⁹ The introduction of MRCP has contributed to the decline in the diagnostic evaluation of patients with suspected CBD stones with ERCP and other modalities. A study conducted in 1999 by Varghese and colleagues showed that MRCP has a sensitivity, specificity, and diagnostic accuracy of 91%, 98%, and 97%, respectively, for the detection of CBD stones. And also, CBD stones were confirmed in all patients by direct cholangiographic methods including ERCP, IOC, and percutaneous transhepatic cholangiography indicating that diagnostic accuracy of MRCP is similar to that of direct cholangiography in the diagnosis of CBD stones.¹⁰

Endoscopic ultrasound (EUS) can also be used to evaluate the CBD to identify calculi. Studies have compared the accuracy of EUS to US, CT and ERCP for detecting CBD stones and showed a sensitivity of EUS ranging from 88% - 97%, with a specificity of 96% - 100%. This result is comparable to ERCP and avoids the complications of pancreatitis, cholangitis and radiation exposure. The role of EUS, however, is yet to be established especially when cost and availability of less invasive modalities such as MRCP are much handier.¹¹

Requirement of extra skills and time to conduct IOC has shifted many surgeons from IOC to MRCP. Given its increasing availability and accuracy the European Association of Laparoscopic Surgeons now consider MRCP to be the standard diagnostic test for patients with an intermediate probability of CBD stones.¹²

In Indian situation laparoscopic surgery especially cholecystectomy is available in most of the small peripheral

centres. However availability and especially interpretation of MRCP and EUS are not widely available. An important additional advantage is that IOC allows for the evaluation of CBD by surgeon himself/herself allowing for a dynamic evaluation of contrast flowing from CBD to duodenum.

Keeping this in mind in our study we have aimed to evaluate the feasibility of laparoscopic IOC in intermediate category of patients for CBD stones for the complete evaluation of CBD highlighting its applicability in our unique healthcare scenario where laparoscopic cholecystectomy is done in small peripheral centers without access to MRCP/EUS.

METHODS

We performed a prospective cohort study in the department of GI surgery, Indraprastha Apollo hospital, Sarita Vihar, Delhi, India with a sample size of 50. All patients getting admitted for laparoscopic cholecystectomy falling within intermediate risk group for CBD stones (according to SAGES criteria) in all cholelithiasis patients from June 2016 to June 2018 in our hospital were included in the study. Data collection started with an informed consent for the particular study. Brief history and examination of patients especially for history of jaundice and history of pancreatitis in the past, history of hypersensitivity to any contrast agents were noted. Liver function reports containing parameters of interest like bilirubin, alkaline phosphatase, gamma - glutamyl transpeptidase, transaminases were noted down. Patients were selected based on the inclusion criteria. Ultrasonography report of abdomen to note status of gall bladder, CBD and liver was collected. Laparoscopic intraoperative cholangiogram was performed as explained below using instruments like, C - arm, flexible catheter (No. 6 ureteric catheter), laparoscopic instruments used for cholecystectomy, dye (Urografin in 1:2 dilution with saline), monitor, lead aprons, glove piece, 18G needle, saline.

Inclusion criteria included 1) Cholelithiasis patients with LFT report showing mildly elevated bilirubin (1.8 - 4 mg%), serum alkaline phosphatase and or/ gamma GTP (more than once, but less than twice). 2) Ultrasound report revealing dilated CBD (>6 mm) 3) Recent past history of jaundice or pancreatitis. Exclusion criteria included, 1) Acute cholangitis, 2) Patients with recognized liver conditions deranging liver function tests, 3) Patients falling in low risk category.

Procedure

Pneumoperitoneum is created using Veress needle and laparoscopic ports are placed according to laparoscopic cholecystectomy requirement. Calot's triangle is dissected to demonstrate cystic artery and cystic duct. Cystic artery is clipped and divided if easily accessible or else can be dealt with later on. Cystic duct is dissected circumferentially taking down the small fibrous and fatty strands. Nothing but the duct should be visible. Duct is milked towards gall bladder with Maryland forceps to push any stone lying in cystic duct and a distal clip (size may be 300 or 400 titanium clip) is

applied. Small ductotomy is made in cystic duct proximal to distal clip transversely. Bile should be visible pouring out of cystic duct. Now the ureteric catheter (5 or 6F) is passed through subcostal 5 mm port as shown in the picture (Figure 1). Fundal grasper is moved to neck of the gall bladder and catheter is pushed in to CBD through cystic duct ductotomy site using Maryland forceps passed through epigastric port. Saline syringe is connected to the catheter and saline is pushed drop by drop during this period. After confirming its position in CBD, saline is pushed into catheter to make sure catheter is lying freely inside. Now a clip is placed over cystic duct including the catheter to fix its position (Figure 2). Clip is tightened only to hold the catheter in place with an eye on the continuously running saline from the syringe.

All the instruments from table or body are removed and forceps is kept over abdomen to guide the direction. C - arm is brought over the operating table and its position is fixed. Dye is loaded to a syringe in 1:2 dilution of dye and saline. All the air removed from syringe and injected slowly through the catheter. Fluorographs are recoded continuously and dynamic flow of dye into CBD and then to duodenum is checked (Figure 3). Patient position is changed with little head low and right side up to fill up both the hepatic ducts. Ductal patency is noticed and free flow of dye into duodenum is noted down. Any abnormality in patency, caliber or contour of CBD and flow of dye is noted down. Filling defects in CBD is looked for and noted down. Saline is injected into CBD to wash out dye. After the procedure, ports are placed back, proximal clip is removed and catheter is pulled out. Clips are placed proximal to ductotomy and cystic duct divided completely. Time taken for the procedure is noted down. Any intraoperative or postoperative complications related to IOC is noted down. This follows usual laparoscopic cholecystectomy.

Postoperative period recovery is same as routine laparoscopic cholecystectomy procedure. If stones are detected on IOC, depending on the character of the stones, number of stones and patients overall risk status patient will be subjected to either operative CBD exploration or postoperative ERCP.

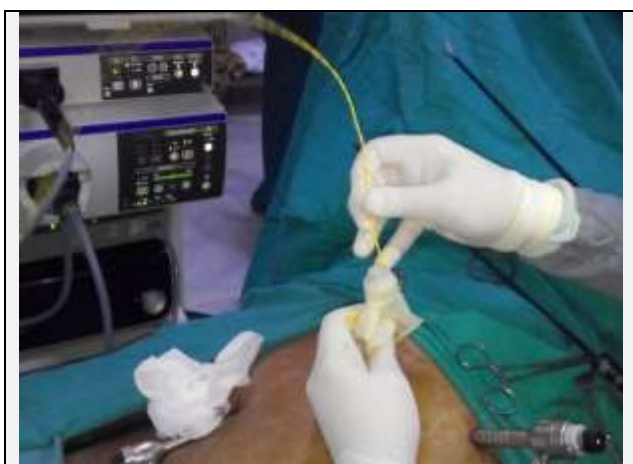

Figure 1. U - Catheter is Passed Through the Hole

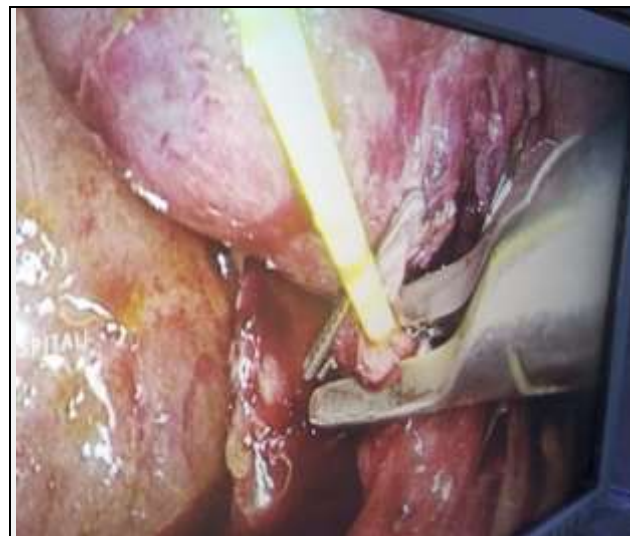


Figure 2. Clip is Placed Over the Cystic Duct in Order to Fix the U - Catheter Position

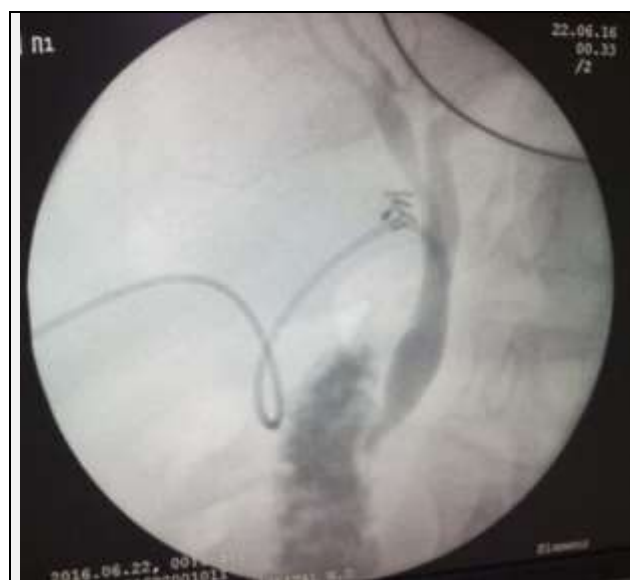

Figure 3. Cholangiogram Showing Free Flow of Dye into Duodenum and No Filling Defect

RESULTS

A total of 50 patients were enrolled in the study during the study period of June 2016 to February 2018 at the department of GI surgery, Indraprastha Apollo hospital, Delhi, India. Most of the patients belonged to age group of 51 - 60 (30%) and 41 - 50 (24%) years. Least number of patients are seen above 60 years. Almost two thirds of the patients were females constituting 64% compared to males forming 36% of the study population. All our patients had pain abdomen as main complaint. One patient was a follow up case of acute pancreatitis who was asymptomatic. Another patient had fever along with pain abdomen. None of the patients had jaundice at the time of surgery. Abdominal examination was unremarkable in all these patients.

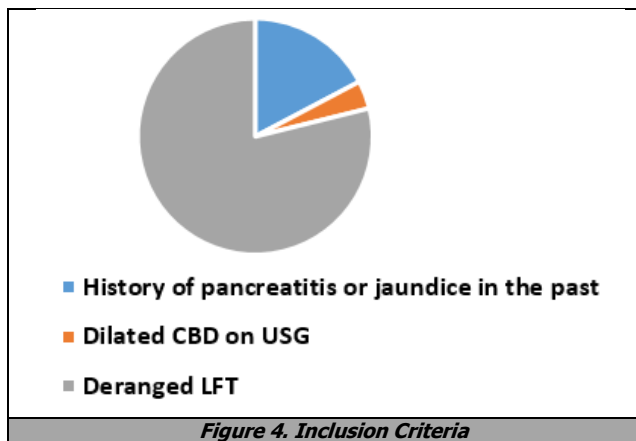


Figure 4. Inclusion Criteria

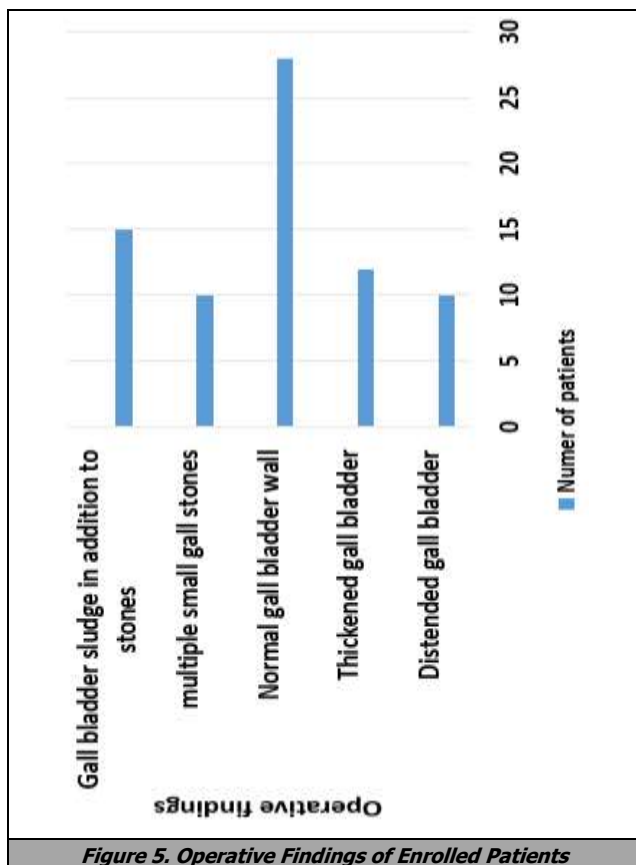


Figure 5. Operative Findings of Enrolled Patients

Forty - one (82%) patients had deranged liver function test as their inclusion criteria for the study. Nine patients (18%) had history of acute pancreatitis in the past which were mild in severity and responded well to conservative treatment (Figure 4).

Two patients had dilated CBD (>6 mm) on ultrasound along with deranged liver function tests. All patients with mild acute pancreatitis were treated conservatively. None of the patients had jaundice in the past. Two patients with history of pancreatitis also had raised alkaline phosphatase level before surgery. In these patients LFT was deranged during pancreatitis in the form of raised serum alkaline phosphatase (Table 5). Patients with history of pancreatitis had their surgery after 4 - 6 weeks of waiting period.

Among the patients who belonged to the deranged LFT group 41 (82%) patients had elevated serum alkaline phosphatase. None of the patients in this group had elevated serum bilirubin level. Transaminases were insignificantly

elevated or normal in all the patients (AST - mean of 35.6, ranged from 18 - 65 U/L (normal range - 10 - 50 U/L) and ALT - mean of 78.3, ranged from 11 - 103 U/L (normal range - 10 - 49 U/L)). Serum alkaline phosphatase level ranged from 108 IU / dL to 244 IU / dL with a mean of 156.9 IU / dL. S. alkaline phosphatase levels were more than once but less than twice the normal range (35 - 129 IU/dl) in all these 50 patients. GGTP level ranged from 9 - 162 U/L with a mean of 52.3 U / L (normal range - 10 - 50 U/L). GGTP was elevated in 10 patients.

Intraoperatively 28 (56%) patients had normal gall bladder wall, 12 (24%) had thickened gall bladder wall (may be due to chronic cholecystitis) and 10 (20%) patients had distended gall bladder (Figure 5). Minimal adhesions were noted in most of the patients. Multiple small gallstones were present in 10 patients, 4 among them were with history of pancreatitis. Gall bladder sludge was noted in 15 patients along with stones. Cystic duct was long in 40 patients and short in 10 patients. In two patients IOC was technically not possible, one due to very thin cystic duct and second due to an inability in cannulate the cystic duct. These two cases were excluded from the study. They were offered MRCP postoperatively. An average of 12 minutes was taken to perform the procedure (range: 8 - 15 min). In cases where IOC took longer time was mainly related to technical aspect (operability of C - arm). Delay was noted in 10 patients with added 5 minutes to the total procedure. No IOC related complications occurred in any of the patients. Hospital stay was not prolonged in any of the patients due to IOC

IOC was found to be normal in all the 50 patients in our study. Criteria to call an IOC normal were a) no filling defects in the CBD b) free flow of dye into the duodenum, c) no delay in flow, d) normal looking left and right hepatic ducts. In some of the cases, on dye injection, flow into duodenum was not seen and they required reinjection of dye with a push to demonstrate the flow. None of them had stricture or filling defects. In 3 patients left hepatic duct was not completely demonstrated initially and required change of table position (head down and left tilt) to get the entire picture. In 3 patients CBD was found to be dilated without any intraluminal filling defects. In these patients CBD was 8 - 10 mm in diameter. Ten mm laparoscopic port was used for size comparison. Places where cystic duct was very thin ductotomy was done carefully much away from CBD, to give it extra space to put the clip, in case of slippage or total transection. We noticed that instrument handling is very important during the procedure especially while inserting the ureteric catheter into the cystic duct. Radiation exposure was minimal since cholangiogram did not take much time. All OT staffs were given lead aprons. Final IOC result was, normal finding in all 50 patients.

These patients are followed up till now, none returned with recurrent symptoms, cholangitis or jaundice.

DISCUSSION

Intraoperative cholangiogram is a valuable tool in the field of biliary surgery. With the development of less invasive preoperative investigations such as MRCP and EUS these

have become the preferred modalities to evaluate the CBD. Indications for IOC are becoming less common and unclear. In order to re-evaluate the place of laparoscopic IOC this particular study was conducted in patients with intermediate risk for choledocholithiasis.

Elevated serum alkaline phosphatase (41 patients) level was the most common indication for IOC followed by a past history of mild acute pancreatitis (9 patients) or a dilated CBD on ultrasound (2 patients). Two patients had dilated CBD (>6 mm) on ultrasound in addition to deranged liver function tests. Two patients with a history of pancreatitis also had raised alkaline phosphatase levels prior to surgery. Of these 50 patients none showed filling defects within the CBD on IOC and there was free flow of dye from the CBD into the duodenum along with a clear demonstration of the left and right hepatic ducts.

James Horwood et al¹³ in their study included patients both of the high and intermediate risk category. Deranged LFT in the past in 15, presently deranged LFT in 33, previously jaundiced in 12, present jaundice in 6, dilated CBD on imaging in 38, history of acute pancreatitis in 9, stone visualised on imaging in 28, jaundice (past and present) along with dilated CBD in 14, jaundice (past and present) with deranged LFT in 3, deranged LFT (past or present) along with dilated CBD in 18 patients. In our study we included only intermediate risk category patients with elevated serum alkaline phosphatase being the most common indication. Our patients falling in the high-risk category directly underwent MRCP followed by ERCP and then laparoscopic cholecystectomy. Horwood et al showed that in patients with a single pre-operative criteria, jaundice at the time of surgery and a stone visualised on pre-operative imaging yielded the highest number of positive cholangiograms (positive predictive values [PPVs] of 0.86 and 0.74, respectively). Patients with combined pre-operative indicators were more likely to have a positive cholangiogram. A history of jaundice and a dilated CBD was the combination with the highest PPV (0.56). Two patients had a biochemical diagnosis of pancreatitis but lacked any other indicators of CBD stones. In both patients, IOCs were normal. A further two patients had pancreatitis and a stone visualised on imaging; however, these also had a negative cholangiogram at the time of surgery.

Megan A. Adams et al¹⁴ showed that of the 317 patients who were classified as intermediate or low probability based on the second set of lab reports (due to a drop in total bilirubin), 209 (65.9%) had no stone or sludge, whereas 108 (34.1%) did have choledocholithiasis. The accuracy of the guidelines, when applied to the second set of lab values, was only 63.2%. Of the 108 low or intermediate-probability patients with history of acute pancreatitis, 74 (68.5%) had a stone and 34 (31.5%) had no stone. Therefore, among patients with biliary pancreatitis, the guidelines had a sensitivity of 39.3%, a specificity of 74.0%, and an accuracy of 61.5% when applied to the second set of laboratory tests.

In our study none of the patients had CBD stone on IOC. Patients belonged to all categories of intermediate risk according to SAGES guidelines. Deranged LFT especially isolated elevated serum alkaline phosphatase (ALP) level did not show any correlation with presence of CBD stones. Elevated serum ALP with history of pancreatitis present in

two of our patients also did not show any evidence of CBD stones on IOC. Of the 9 patients with a history of pancreatitis none had CBD stones on IOC. Among patients with an isolated elevation of serum ALP levels included only those patients in whom elevation was more than once and less than twice. This may have reduced the weightage of this indication. In our study SAGES criteria did not directly correlate with presence of CBD stones. Even though the likelihood of CBD stones with altered LFT values is high according to SAGES guidelines it is not enough to justify sophisticated investigations like MRCP and EUS. These patients can be considered directly for a laparoscopic cholecystectomy with IOC in skilled and experienced hands. Combination of intermediate risk factors for CBD stones would decrease the tolerance for ordering these investigations like MRCP or EUS if IOC is not possible.

Intermediate category of patients are one group where MRCP, EUS and IOC are all proven equal and effective. Depending on whether these patients need to be evaluated preoperatively or intraoperatively decides the management plan. According to SAGES guidelines these patients have a risk of harbouring CBD stones in 10 - 50% of cases. These patients have a chance of developing cholangitis, recurrent symptoms and acute biliary pancreatitis ranging from mild to severe.¹⁵ MRCP has emerged as an accurate, non-invasive diagnostic modality providing excellent anatomic detail of the biliary tract and having a sensitivity of 81% - 100% and a specificity of 92% - 100% in detecting choledocholithiasis.¹⁶ To evaluate this Jinfeng Zang et al¹⁷ conducted a retrospective cohort study to know the role of preoperative magnetic resonance cholangiopancreatography in patients undergoing elective laparoscopic cholecystectomy without intraoperative cholangiography. In the IOC group, all suspected patients underwent an IOC during LC. In the MRCP group, all suspected patients had a MRCP prior to LC. Patients with a history of jaundice, cholangitis or pancreatitis, abnormal liver function tests, ultrasonographic evidence of CBD stones or dilatation underwent IOC or preoperative MRCP for bile duct evaluation. In the IOC group, 12 patients were readmitted with symptoms and/or signs suggestive of retained CBD stones. In 11 patients, retained CBD stones were confirmed through subsequent ERCP. The 11 cases included three patients in whom IOC was normal (false negative). The rate of retained CBD stones was 0.45 % (8/1759) in patients without IOC and 1.41 % (3/213) in patients with IOC. However, in five of 157 patients with positive IOC, subsequent ERCP or laparoscopic CBD exploration showed no evidence of CBD stones (false positive). In the MRCP group, 10 patients without the indication of MRCP before LC were readmitted because of suspected retained CBD stones. In nine patients, retained CBD stones were found by subsequent ERCP. The rate of retained CBD stones was 0.45 % (9/2011) in patients without MRCP. No patients with normal MRCP findings returned with symptomatic CBD stones during 1-year follow-up. Subsequent ERCP or laparoscopic CBD exploration showed no evidence of CBD stones in 12 of 192 patients with positive preoperative MRCP (false positive). They concluded that selective use of preoperative MRCP is an effective and safe strategy when conducting elective LC to treat gallstones. This imaging

modality might allow LC to be performed safely with an acceptable rate of retained CBD stones as that of IOC.

Although when compared to MRCP and IOC the results are similar as far as accuracy is concerned, it needs specialized machine which may not be available in peripheries in our country. IOC can be done by surgeon alone. Surgeon is more confident and comfortable reading an IOC as it gives a dynamic picture of dye flowing into CBD as compared to static picture of MRCP. Although there are no head to head comparison trials between EUS and IOC, EUS needs special equipment and expertise to perform whereas IOC can be done by the surgeon himself/herself in the OT with available resources.

Junji Machi et al¹⁸ evaluated the role of laparoscopic ultrasonography (LUS) during laparoscopic cholecystectomy and concluded that LUS and OC can be used in a complementary manner. There is a prolonged learning curve for LUS because of its technical difficulty. Again, this study imply that IOC provides clear delineation of anatomy and can selectively be used, particularly when ductal anatomic variations or anomalies or bile duct injuries are suspected. Moreover, LUS requires expensive instrument and expertise, while IOC needs routine C - arm which is available in most of the OTs which can be handled by the surgeon and OT technicians with minimal training.

Average time taken for the procedure in our patients was 12 min (range 8 – 15 min). Khaira HS et al reported their technique and took an average time of 20 min per case (range, 7–30 min). IOC has a reported success rate of 86–94%.¹⁹ Failures result from technical difficulties related to cannulation of the cystic duct. In our study also IOC failed in only two patients. IOC is reported to have a sensitivity and specificity ranging between 93–99%,²⁰ with inevitable false - positive examinations. Procedure related complications are rare. The incidence of pancreatitis, in contrast to ERCP, is negligible.²⁰

In our series no IOC related complications were noted. These patients are followed up till now and none of them have come back with recurrent symptoms or cholangitis. They will need further follow up to know the long-term outcome. James Wood reported a sensitivity of selective cholangiogram policy for the detection of CBD stones as 96% and a specificity of 95% (3 false - positive cholangiogram). IOC failed in 3 cases (2%) due to an occluded cystic duct in 2 patients, and complicated anatomy (frozen Calot's) precluding safe cholangiography in one patient.²¹ We feel that a major advantage of IOC is that it allows the surgeon to access the CBD him/herself. Also, the demonstration of the dynamic flow of contrast from the CBD into duodenum helps to confidently rule out biliary obstruction. False positive rates of IOC are not high enough to disregard the procedure. There is a group of patients with high risk of ERCP failure such as those with altered gastroduodenal anatomy like gastric bypass or Billroth - II reconstruction or patients with previous ERCP failure. These patients would specially benefit from an IOC if they fall in the intermediate risk category (for CBD stones) as per the SAGES criteria.

Laparoscopic cholecystectomy in our country is performed in health care set up with a varied level of

facilities. IOC is a simple non - expensive procedure that can be performed as well as interpreted by the surgeon him/herself. Relatively easy to learn. We feel that IOC is a useful tool in the armamentarium of every biliary and laparoscopic surgeon. Additionally, situations such as altered anatomy, suspected bile duct injury, stump cholecystectomy etc., IOC in our experience has been extremely useful. It has helped to avoid conversion to an open procedure and perform the laparoscopic surgery safely and confidently.

CONCLUSIONS

It is a technically feasible procedure that can be performed with limited addition to OT time, minimal failure rate, and complications. All patients with limited criteria for intermediate risk of choledocholithiasis had a normal IOC with no evidence of biliary obstruction in follow up. The findings of this study need further evaluation through RCTs.

Data sharing statement provided by the authors is available with the full text of this article at jebmh.com.

Financial or other competing interests: None.

Disclosure forms provided by the authors are available with the full text of this article at jebmh.com.

REFERENCES

- [1] MacFadyen BV. Intraoperative cholangiography: past, present and future. *Surg Endosc* 2006;20 Suppl 2:S436-S440.
- [2] Reich A. Accidental injection of bile ducts with petrolatum and bismuth paste. *JAMA* 1918;71(19):1555.
- [3] Phillips EH. Routine versus selective intraoperative cholangiography. *The American Journal of Surgery* 1993;165(4):505-507.
- [4] Hickens NF, Best RR, Hunt HB. Cholangiography. *Ann Surg* 1936;103(2):219-229.
- [5] Mirizzi PL. Operative cholangiography. *Surg Gynecol Obstet* 1937;65:702 - 708.
- [6] Holliday HJ, Farringer JL, Terry RB, et al. Operative cholangiography. *Am J Surg* 1980;139(3):379-382.
- [7] Kakos GS, Tompkins RK, Turnipseed W, et al. Operative cholangiography during routine cholecystectomy: a review of 3,012 cases. *Arch Surg* 1972;104(4):484-488.
- [8] Doyle PJ, Ward - McQuaid JN, Smith AM. The value of routine perioperative cholangiography - a report of 4,000 cholecystectomies. *Br J Surg* 1982;69(10):617-619.
- [9] Borjeson J, Liu SK, Jones S, et al. Selective intraoperative cholangiography during laparoscopic cholecystectomy: how selective? *Am Surg* 2000;66(7):616-618.
- [10] Sirinek KR, Schwesinger WH. Has intraoperative cholangiography during laparoscopic cholecystectomy become obsolete in the era of preoperative endoscopic

- retrograde and magnetic resonance cholangiopancreatography? *J Am Coll Surg* 2015;220(4):522-528.
- [11] Freitas ML, Bell RL, Duffy AJ. Choledocholithiasis: evolving standards for diagnosis and management. *World J Gastroenterol* 2006;12(20):3162-3167.
- [12] Neugebauer EAM, Sauerland S, Fingerhut A, et al. EAES guidelines for endoscopic surgery. Chap. 15 and 16. (MRCP) Berlin: Spinger 2006.
- [13] Horwood J, Akbar F, Davis K, et al. Prospective evaluation of a selective approach to cholangiography for suspected common bile duct stones. *Ann R Coll Surg Engl* 2010;92(3):206-210.
- [14] Adams MA, Hosmer AE, Wamsteker EJ, et al. Predicting the likelihood of a persistent bile duct stone in patients with suspected choledocholithiasis: accuracy of existing guidelines and the impact of laboratory trends. *Gastrointest Endosc* 2015;82(1):88-93.
- [15] American Society for Gastrointestinal Endoscopy. The role of endoscopy in the evaluation of suspected choledocholithiasis. *Gastrointestinal Endoscopy* 2010;71(1):1-9.
- [16] Hallal AH, Amortegui JD, Jeroukhimov IM, et al. Magnetic resonance cholangiopancreatography accurately detects common bile duct stones in resolving gallstone pancreatitis. *J Am Coll Surg* 2005;200(6):869-875.
- [17] Zang J, Yuan Y, Zhang C, et al. Elective laparoscopic cholecystectomy without intraoperative cholangiography: role of preoperative magnetic resonance cholangiopancreatography - a retrospective cohort study. *BMC Surgery* 2016;16(1):45.
- [18] Machi J, Tateishi T, Oishi AJ, et al. Laparoscopic ultrasonography versus operative cholangiography during laparoscopic cholecystectomy: review of the literature and a comparison with open intraoperative ultrasonography. *The Journal of American College of Surgeons* 1999;188(4):360-367.
- [19] Khaira HS, Ridings PC, Gompertz RH. Routine laparoscopic cholangiography: a means of avoiding unnecessary endoscopic retrograde cholangiopancreatography. *J Laparoendosc Adv Surg Tech A* 1999;9(1):17-22.
- [20] Morgan S, Traverso LW. Intraoperative cholangiography and postoperative pancreatitis. *Surg Endosc* 2000;14(3):264-266.
- [21] Berci G, Shore MJ, Hamlin AJ, et al. Operative fluoroscopy and cholangiography. The use of modern radiologic technics during surgery. *Am J Surg* 1978;135(1):32-35.