

HISTOPATHOLOGICAL AND GROSS ANATOMICAL STUDY OF HUMAN PLACENTA IN PATIENTS WITH PREECLAMPSIA

Vimla Kumari¹, Umesh Prasad Sinha²

¹Senior Resident, Department of Obstetrics and Gynaecology, Government Medical College, Bettiah.

²Assistant Professor, Department of Anatomy, Government Medical College, Bettiah.

ABSTRACT

BACKGROUND

The beginning reason for preeclampsia is the placenta. Preeclampsia starts to lessen with the conveyance of the placenta and can happen without a baby, however, with the nearness of trophoblast tissue with hydatidiform moles. In perspective of this, investigation of the placenta ought to give knowledge into the pathophysiology of preeclampsia. In this presentation, we look at placental pathological and anatomical changes with preeclampsia and Foetal Development Limitation (FGR). No doubt, this examination ought to enlighten as both conditions are associated with comparably unusual placentation yet just in preeclampsia is there a maternal pathophysiological disorder. Comparative bits of knowledge about ahead of schedule and late onset preeclampsia ought to likewise be given by such information.

METHODS

A prospective study was led in the Department of Obstetrics and Gynaecology, Government Medical College, Bettiah. 250 instances of pregnancy actuated hypertension were concentrated on. The cases with systolic circulatory strain more prominent than 130 mmHg, diastolic pulse more noteworthy than 90 mmHg on two estimations dismantled 6 hours in relationship with histological finding were incorporated into the study. These cases were further separated as mild preeclampsia if the diastolic circulatory strain was ≤ 100 mmHg and as moderate preeclampsia if the diastolic pulse was 110 mmHg. Extreme cases were characterised if the systolic pulse - ≥ 160 mmHg, diastolic circulatory strain ≥ 110 mmHg. Maternal and foetal result was considered and post conveyance placenta was sent for histopathologic examination. Gross anatomical and microscopic examination was done and discoveries were connected with the seriousness of PIH.

RESULTS

Out of 250 cases, there were 156 instances of mild PIH, 53 moderate and 41 were of severe PIH. On gross examination (Table 1), the mean weight of placenta was 429.9 gm in gentle instances of PIH, 364 gm in moderate instances of PIH, and 327.86 gm in extreme instances of PIH. Histopathology of placenta is adversely co-identified with seriousness of placenta.

CONCLUSION

Placenta from the hypertension-induced pregnant women shows a significant morphological changes was observed, which may alter the perinatal outcome.

KEYWORDS

Placenta, Preeclampsia, FGR, Trophoblast.

HOW TO CITE THIS ARTICLE: Kumari V, Sinha UP. Histopathological and gross anatomical study of human placenta in patients with preeclampsia. J. Evid. Based Med. Healthc. 2016; 3(59), 3162-3165. DOI: 10.18410/jebmh/2016/687

INTRODUCTION: Hypertensive disorders during pregnancy occur in women with pre-existing primary or secondary chronic hypertension and in women who develop new-onset hypertension in the second half of pregnancy.

Hypertensive disorders during pregnancy carry risks for the woman and the baby. Although, the rate of eclampsia in the United Kingdom (UK) appears to have fallen. Hypertension in pregnancy remains one of the leading causes of maternal death in the UK. Hypertensive disorders during pregnancy may also result in substantial maternal

morbidity. A UK study reported that one-third of severe maternal morbidity was a consequence of hypertensive conditions. A study from one region of the UK reported that 1 in 20 (5%) women with severe pre-eclampsia or eclampsia were admitted to intensive care. More recently, the long-term consequences for women with a diagnosis of hypertension during pregnancy have become clear in particular chronic hypertension and an increase in lifetime cardiovascular risk. Hypertensive disorders also carry a risk for the baby. In the most recent UK perinatal mortality report, 1 in 20 (5%) stillbirths in infants without congenital abnormality occurred in women with pre-eclampsia. The contribution of pre-eclampsia to the overall preterm birth rate is substantial; 1 in 250 (0.4%) women in their first pregnancy will give birth before 34 weeks as a consequence of pre-eclampsia and 8-10% of all preterm births result from

Financial or Other, Competing Interest: None.

Submission 18-06-2016, Peer Review 28-06-2016,

Acceptance 09-07-2016, Published 25-07-2016.

Corresponding Author:

Dr. Vimla Kumari,

#303, Mansarovar Apartment, Khajpura-800014, Patna.

E-mail: vimlakumari61@gmail.com

umesh18163@yahoo.co.in

DOI: 10.18410/jebmh/2016/687

hypertensive disorders. Half of women with severe pre-eclampsia give birth preterm. Small for gestational age babies (Mainly because of foetal growth restriction arising from placental disease) are common with 20-25% of preterm births and 14-19% of term births in women with pre-eclampsia being less than the tenth centile of birth weight for gestation. There is national guidance on the care of women with severe pre-eclampsia or eclampsia and on screening for hypertensive disorders during pregnancy. However, there has been no guidance on the assessment and care of women and their babies after a diagnosis of hypertension (Including the use of antihypertensive treatment) or on maternity care for women with chronic hypertension.

The complications of hypertensive disorders in pregnancy have been attributed to abnormalities in the placenta. Therefore, the placenta of the hypertensive woman has gained much interest and several pathological changes have been described. Placental villous angiogenesis may soon be viewed as central to normal perinatal development and survival. The present study was embraced to concentrate on the morphological changes and histological changes in the placentae of hypertensive mothers in order to give a superior comprehension of the pathologic procedure included.

RESULTS:

Severity of PIH	Placental Weight in Grams (Mean±SD)	Placental Thickness in cm (Mean±SD)	Foetal Weight and Placental Weight Ratio	Total Number of Cases
Mild	429.9±62.15	2.55±0.24	5.003:1	156
Moderate	364±76.59	2.1±0.23	4.58:1	53
Severity	327.86±110.53	1.76±0.89	4.63:1	41

Table 1: Gross Anatomical Features of Placenta in PIH (n= 250)

Out of 250 cases, there were 156 instances of mild PIH, 53 moderate, and 41 were of severe PIH. On gross examination (Table 1), the mean weight of placenta was 429.9 gm in gentle instances of PIH, 364 gm in moderate instances of PIH, and 327.86 gm in extreme instances of PIH. There is a noteworthy negative relationship between placental weight and PIH seriousness (Spearman's rho = - 0.503, p<0.001) i.e. as the PIH seriousness expands the placental weight diminishes.

The mean foetal weight to placental weight proportion was 5.003:1 in gentle instances of PIH, 4.58:1 in moderate cases, and 4.63:1 in serious instances of PIH. There is a noteworthy negative connection between foetal weight to placental weight proportion and PIH seriousness (Spearman's rho = - 0.548, p<0.001) i.e. as the PIH seriousness expands, the foetal weight to placental weight proportion diminishes.

The thickness of the placenta figured in mean was 2.55 cm in mild cases, 2.1 cm in moderate, and 1.67 cm in severe instances of PIH. There is a noteworthy negative relationship between placental thickness and PIH seriousness

AIMS AND OBJECTIVES: To study the histopathological changes and gross anatomical features of placenta in pregnancy-induced hypertension.

SUBJECTS AND METHODS: An imminent study was led over a time of one year from first January 2008 till 31st December 2009 in the Department of Obstetrics and Gynaecology, Government Medical College, Bettiah. 250 instances of pregnancy-affected hypertension were concentrated on. The cases with systolic pulse more prominent than 130 mmHg, diastolic circulatory strain more prominent than 90 mmHg on two estimations taken 6 hours apart in relationship with histological finding were incorporated into the study. These cases were further isolated as mild preeclampsia if the diastolic pulse was ≤100 mmHg and as moderate preeclampsia if the diastolic circulatory strain was 110 mmHg. Serious cases were characterised if the systolic circulatory strain - ≥160 mmHg, diastolic pulse ≥110 mmHg. Maternal and foetal result was concentrated on and post conveyance placenta was sent for histopathologic examination. Gross anatomical and microscopic examination was done and findings were corresponded with the seriousness of PIH. Measurable examination was completed utilizing Spearman's rho and the relationship considered huge at P <0.001. Permission to conduct the study was taken from the Ethics Committee.

(spearman's rho = - 0.501, p<0.001) i.e. as the PIH seriousness builds, the placental thickness diminishes.

Histopathological Findings	No. of Cases	% of Cases	PIH (250) Mean±SD
Fibrinoid necrosis	86	34.4%	21.1±5.25
Syncytial knots	23	9.2%	6.4±4.07
Villous fibrosis	39	15.6%	8.51±3.5
Hypovascular villi	102	40.8%	61.32±22.29

Table 2: Histopathological Changes in Placenta in PIH (n=250)

Histological changes was observed under light microscope with magnification of 10x. The findings was observed in abnormal cases. Significant finding in histology was the premature ageing as seen in placentae, which increased with the increase in severity of the disease. Hypovascular villi were available in as high as 102 cases out of the aggregate 250 cases (40.8%) taken after by fibrinoid necrosis (34.4%), villous fibrosis (15.6%), and syncytial knots (9.2%).

Histological Lesion	PIH (Mean±SD)	P value
Syncytial knots	23.1±7.52	P<0.001
Hyalinised villi	5.7±3.04	P<0.001
Fibrinoid necrosis	6.26±2.8	P<0.001
Stromal fibrosis	31.23±42.29	P<0.001

Table 3: Statistical Analysis of Histological Examination of Placental Villi

Syncytial knots were seen in as high as 180 cases out of the total 250 cases (72%) expansion in number. Of hypovascular villi and fibrinoid necrosis was seen in expansive number of cases. Villi showed increased fibrosis contributing to the premature ageing (33%).

Histology of Placenta:

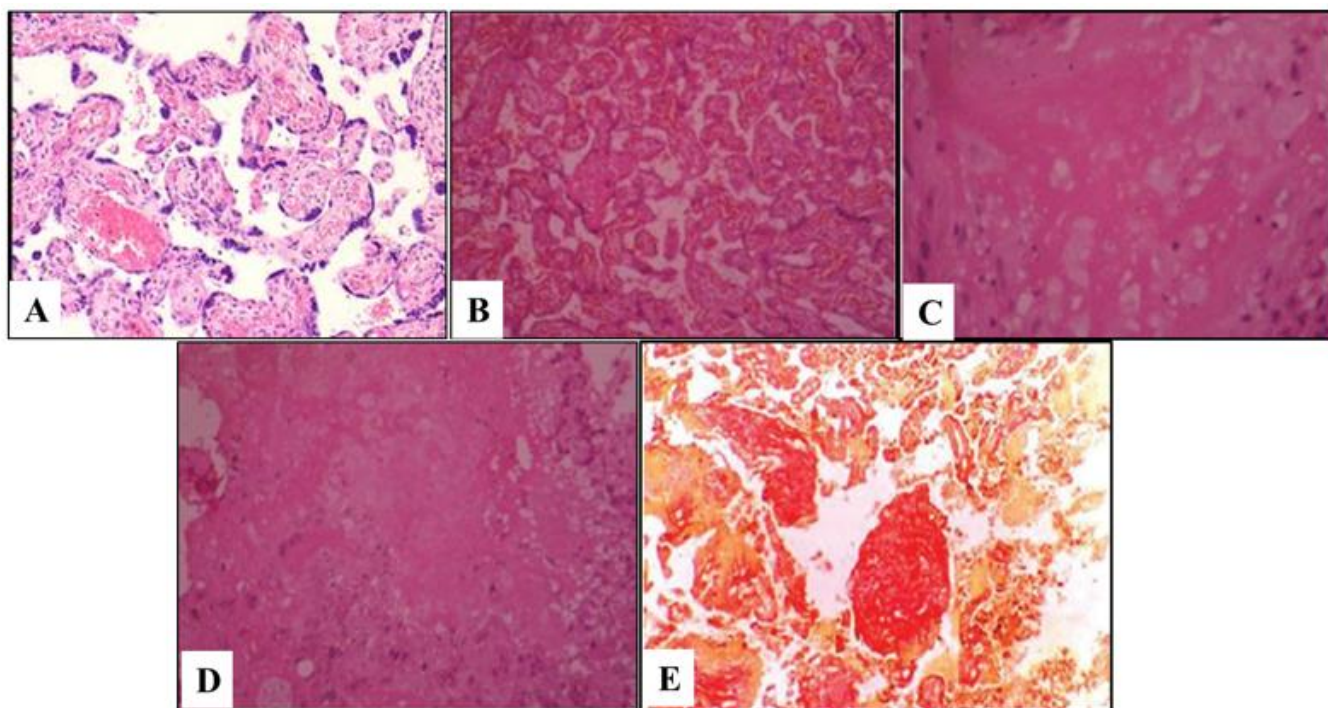


Figure 1: Picture Showing Histology of Placenta A) Normal Mature Placenta B) Syncytial Knots C) Hyalinised Villi D) Fibrinoid Necrosis E) Stromal Fibrosis.

DISCUSSION: The foetus, placenta, and mother form a composite triad of element balance and damage of any of them can influence the other. Hence, the present study expects to associate the progressions found in placenta in instances of PIH.

Normally, a placenta weighs from 400 gms to 800 gms. In the present study, the mean placental weight was 429.9 gms in mild PIH, 364 gms in moderate cases, and 327.86 gms in serious cases. A noteworthy negative relationship was ascertained between the placental weight and seriousness of PIH. In this manner, we can see that the weight of placenta declines with the expanding seriousness of the turmoil. These findings verify with the investigations of different specialists Damania et al in 1989,⁽¹⁾ Fox et al in 1994⁽²⁾ and Kalousek et al in 1994.⁽³⁾ At term, the fetoplacental proportion differs somewhere around 6:1 and 8:1 (Morrison, 1963). In our study, the foetal weight to placental weight proportion was 5.003:1 in gentle instances of PIH, 4.58:1 in moderate cases, and 4.63:1 in extreme instances of PIH. There is likewise a noteworthy negative connection between the proportion and seriousness of PIH showing that as the seriousness of PIH builds, the proportion

diminishes. These discoveries were likewise found in study by Bandana Das et al in 1996 where the proportion was 6.15:1 in mild instances of PIH and 5.43:1 in extreme cases.⁽⁴⁾

The present study noticed that the mean thickness of placenta computed were 2.55 cm in gentle, 2.1 cm in moderate, and 1.76 cm in serious instances of PIH. A critical negative connection was found between the thickness of placenta and PIH seriousness. Thus, the placentas of more serious instances of PIH are more slender when contrasted with the milder cases. This has additionally been substantiated by the study by Bandana Das et al.⁽⁴⁾

In microscopic examination, syncytial knot development (These are foetal bunches of syncytial cores distending from the external surface of villous trophoblasts. There is a contradiction with respect to arrangement of these bunches). In the present study, statistically significant syncytial knot count were seen in cases of toxemia. Fox (1965) concluded from his study that only factor related with syncytial knot formation is length of gestation and suggested that within limits it can be regarded as an index of placental maturity. Statistically significant high count seen in toxemia

maybe related to reduce foetal villous flow in these cases. Fox concluded from his study that excess syncytial knot formation occur in generalised form whenever the foetal circulation through the villi appears to be reduced. Irrespective of the mechanism, which is responsible for reducing foetal blood flow through the villi the inevitable result is stromal fibrosis and excess syncytial knot formation both of which are good indices of the degree of reduction in villous perfusion.

Villous hypovascularity (Hyalinised villi) - the mechanism involved hypovascular villi is not completely comprehended. In the present concentrate, measurably critical number of hyalinised villi was seen in instances of toxemia. Teasdale⁽⁵⁾ and Udainia et al⁽⁶⁾ reported that fibrinoid necrosis, endothelial proliferation of arteries, and hyalinization depict the mosaicism of placenta and probably the aftermath of hypertension. Again, the mosaicism of the placenta probably leads to placental insufficiency and ultimately to foetal growth retardation, Zacutti (1992) thus creating a vicious cycle.

Our data showed statistically significant in stromal fibrosis was seen in 34% instances of toxemia. Like present study, Harianne et al (1976) also discovered measurably noteworthy level of stromal fibrosis in instances of toxemia. However, they additionally acquired very critical level ($P < 0.01$) in instances of anaemia. This they disclosed is because of relative anoxia in this condition. The two principle elements thought to be in charge of the development of stromal fibrosis are ordinary maturing and decreased blood flow. Stromal fibrosis is because of diminished blood stream appears to be more convincing as overabundance stromal fibrosis finds in instances of toxemia. This hypothesis would explain the results obtained in this study. The high incidence of villous fibrosis in placentae from pregnancies complicated by toxemia is probably due to reduction of the foetal blood flow by obliterative endarteritis of the foetal stem arteries, which is a common of such placentae.

Fibrinoid Necrosis - Fibrinoid necrosis of placental villi is a huge characteristic Lesion. The first step in the evolution of this abnormality is the appearance of a small "blob" of homogenous material in the trophoblast. This substance lies deep to the syncytiotrophoblast and external to the basement membrane from which it is quite distant. The "blob" of irregular material continuously enlarges, the accumulation continually being on profound surface, so that the fibrinoid material lumps dynamically into the villous stroma. It does not invade the stromal tissue for the underlying trophoblastic basement membrane remains intact and is pushed inwards to form a gradually deepening crescent. This process proceeds until the entire of the villus is replaced by fibrinoid material. The syncytium of the influenced villus demonstrates a dynamic degeneration,

however, even in the last stages, a couple of leftovers of this tissue remain. Consequently, the last appearance is that of a mass of structure less homogenous acidophilic material around the outskirts of which are a couple ruffian syncytial nuclei. Many workers have suspected that this injury is because of substitution of the villus by fibrin. This being shaped either from the maternal blood in the intervillous space. (Mckay et al. 1958; Wiggles worth, 1964) or from the foetal blood in the villous capillaries.^(7,8)

CONCLUSION: Statistically significant counts of syncytial knots $P < 0.001$ and hypovascular villi seen in cases of PIH, suggesting their presence due to reduced villous blood flow. Statistically significant counts of stromal fibrosis and fibrinoid necrosis were also seen in cases of PIH. It may indicate an immunological reaction within placental tissue responsible for premature onset of labour or it may be a degenerative process.

REFERENCES

1. Damania KR, Salvi VS, Ratnaparki SK, et al. The placenta in hypertensive disorder in pregnancy. *J Obst and Gynaecol Ind* 1989;39:28-31.
2. Fox H. The placenta in intra uterine growth retardation. In Ward RHT, Smith SK, Donnai D, eds. *Early foetal growth and development*. London: RCOG Press 1994:223-235.
3. Kalousek DK, Langlosis S. The effects of placental and somatic chromosomal mosaicism on foetal growth. In: Ward RHT, Smith SK, Donnai, eds. *Early foetal growth and development*. London: RCOG Press 1994:245-256.
4. Das B, Dutta D, Chakraborty S, et al. Placental morphology in hypertensive disorders of pregnancy and its correlation with foetal outcome. *J Obstet and Gynaecol India* 1996;46(1):40-46.
5. Teasdale F. Gestational changes in functional structure of the human placenta in relation to foetal growth: a morphometric study. *Am J Obst Gynaecol* 1980;137(5):560-568.
6. Udainia A, Bhagwat SS, Mehta CD, et al. Relation between placental surface area, infarction and foetal distress in pregnancy-induced hypertension with its clinical relevance. *J Anat Soc India* 2004;53(1):27-30.
7. Emmrich P. Pathologie der Plazenta. VII. Asphyxieinfiltrate der Plazenta. *Zentralbl Pathol* 1991;137:479-485
8. Kline BS. Microscopic observations of development of human placenta. *Am J Obstet and Gynae* 1951;61:1065-1074.