

HISTOPATHOLOGICAL STUDY OF NEOPLASTIC LESIONS OF FEMALE GENITAL TRACT IN KOLHAN, JHARKHAND

Shailendra Nath Paul¹, Saket Kumar², Silbina Murmu³, Emmanuel Anurag Soreng⁴

¹Associate Professor, Department of Pathology, MGM Medical College and Hospital, Jamshedpur, Jharkhand.

²Tutor, Department of Pathology, MGM Medical College and Hospital, Jamshedpur, Jharkhand.

³Assistant Professor, Department of Pathology, MGM Medical College and Hospital, Jamshedpur, Jharkhand.

⁴Tutor, Department of Pathology, MGM Medical College and Hospital, Jamshedpur, Jharkhand.

ABSTRACT

BACKGROUND

Gynaecological specimens form the major proportion of tissue biopsies in most pathology departments. Sexually active women are more prone to cervical disease. The aim of this study is to find out the frequency distribution of tumours occurring in FGT.

MATERIALS AND METHODS

This study was carried out in pathology department of MGM Medical College, Jamshedpur. All formalin fixed surgical specimens of female genital tract from January 2013 to December 2015 were subjected for histopathology and examined under light microscopy. All neoplastic lesions were included, and non-neoplastic lesions were excluded from the study.

RESULTS

Between the period January 2013 to December 2015, a total of hundred (100) FGT surgical biopsies with various types of neoplastic lesions were received in the department of pathology, MGM Medical College, Jamshedpur. Out of which 8 tumours were from uterine cervix, 64 tumours were from uterine body, 28 tumours were from ovaries. Majority 90% were benign and 10% were malignant. Leiomyoma was the most common benign tumour of uterine body and squamous cell carcinoma of cervix was the most common malignant tumour. Both benign and malignant tumours occur in the age group of 41-50 years.

CONCLUSION

Histology is the best technique to detect female genital tract lesions. Leiomyoma is the common tumour arising in FGT. Carcinoma of cervix is the common malignant tumour. Routine Pap smear test in reproductive age group is a way of reducing the occurrence of carcinoma of the cervix in our setup with current means.

KEYWORDS

Female Genital Tract (FGT), Neoplastic Lesion, Leiomyoma, Malignant Tumour, Squamous Cell Carcinoma Cervix.

HOW TO CITE THIS ARTICLE: Paul SN, Kumar S, Murmu S, et al. Histopathological study of neoplastic lesions of female genital tract in Kolhan, Jharkhand. J. Evid. Based Med. Healthc. 2018; 5(40), 2833-2836. DOI: 10.18410/jebmh/2018/581

BACKGROUND

Female genital tract includes vulva, vagina, uterus (body & cervix), fallopian tubes, and ovaries. Common sites for the development of tumours are ovaries, cervix, endometrium and myometrium. Diseases of the cervix are common in young sexually active women.

The ovarian cancer and the cervical cancer are the two common cancers occurring in women. About 80% of new cases of cervical cancer occur in developing countries.¹ Carcinoma cervix is the commonest malignant tumour in Indian women. Early sexual activity, sexually transmitted

disease, viral infections, low socioeconomic status, birth trauma are the various factors responsible for the carcinoma cervix. Viruses especially Human Papilloma Virus (HPV) and Herpes Simplex virus commonly infect the cervix and are strongly associated with carcinoma of the cervix. Other lesions seen in the cervix are mesonephric hyperplasia, endometriosis and microglandular endocervical hyperplasia. These lesions may be misinterpreted as malignant. These are differentiated from malignant by histopathological examination.

Generally, these tumours are symptomless. That is why they come into medical attention only when they are in advanced stage. The study was done to find out the age wise frequency of both benign and malignant neoplasms of female genital tract and to compare the data with other studies.

MATERIALS AND METHODS

We had done this study in the department of pathology, MGM Medical College, Jamshedpur for the period of January 2013 to December 2015. First of all the patient's clinical and

Financial or Other, Competing Interest: None.

Submission 10-09-2018, Peer Review 14-09-2018,

Acceptance 23-09-2018, Published 26-09-2018.

Corresponding Author:

Dr. Shailendra Nath Paul,

Associate Professor,

Department of Pathology,

MGM Medical College and Hospital,

Jamshedpur, Jharkhand.

E-mail: shailendra.paul61@gmail.com

DOI: 10.18410/jebmh/2018/581



the histopathological findings were collected from the pathology department and were analysed.

Various types of specimens, like excision biopsy, pan hysterectomy, cystectomy and cervical biopsies, were fixed in 10% formalin. The gross examination of specimens was done in the histopathology section by the pathologist. Tissue sections were taken from the representative areas. Paraffin blocks were prepared. After microtomy, the slides were prepared. After microtomy, the slides were stained with haematoxylin and eosin stains as follows- deparaffinised the sections with xylene, 3 times and hydrated through graded alcohols in water. Stained in Mayer’s haematoxylin for 10 minutes. Washed well in running tap water for 5 minutes. Then used 1% acid alcohol to differentiate for 10 seconds. Then washed well in tap water until sections were again blue (10-15 min.). Then slides were stained in 1% eosin for 10 minutes. Then it was washed in running tap water for 1-5 minutes. Lastly dehydration was done through alcohols, cleared and mounted in DPX. All histopathological tissues reporting neoplastic lesions were included in the study.

In our study 41-50 years was the commonest age group for both benign and malignant tumours (table 2).

RESULTS

A total of hundred (100) cases of neoplasm of female genital tract were detected. Out of which 90 cases were benign tumours and 10 cases were malignant tumours. Most common benign tumour was leiomyomas containing of 65% (65 cases) of the total tumours (figure 1 & 2). Majority 64 cases were seen arising from uterine body and only one case was seen arising from cervix. Other benign tumours were from ovaries comprising of mature cystic teratomas 13 cases, mucinous cystadenomas 8 cases, (figure 4) and serous cystadenomas 6 cases.

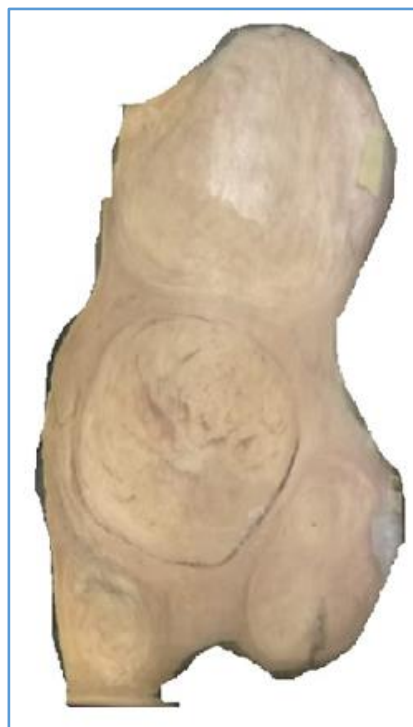

Figure 1. Gross Photograph of Fibroid Uterus Showing Intramural, Submucosal and Subserosal Fibroid

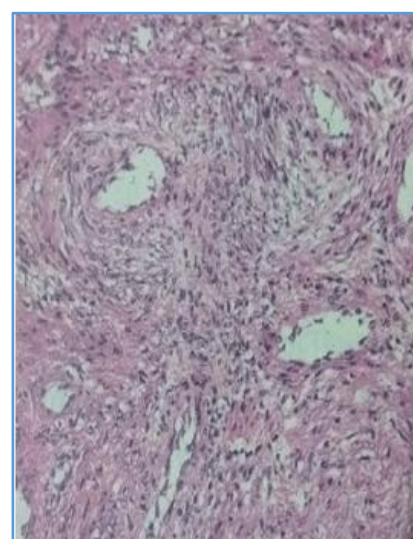


Figure 2. Microphotograph of Leiomyoma Revealing Whorls of Benign Smooth Muscles

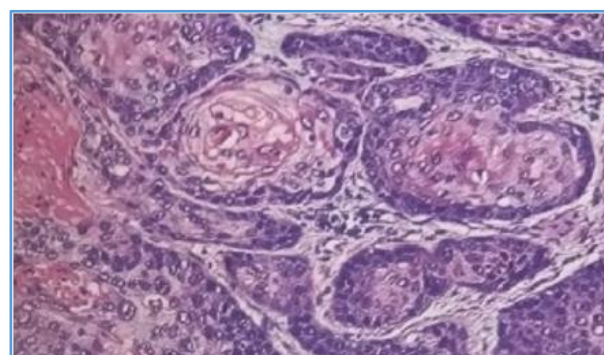


Figure 3. Microphotograph of Squamous Cell Carcinoma of Cervix Showing Nests of Malignant Squamous Cells

| Organ | Number of Cases with Percentage | Histopathological Types |
|----------------|---------------------------------|--|
| Uterine cervix | 8 (8%) | 1 leiomyoma and 7 squamous cell carcinomas |
| Uterine body | 64 (64%) | All leiomyomas |
| Ovary | 28 (28%) | 1 immature teratoma, 13 mature cystic teratoma, 8 mucinous cystadenoma, 6 serous cystadenomata |

Table 1. Distribution of Neoplasms of Female Genital Tract in Various Organs

| Age in Years | Benign | Malignant |
|--------------|--------|-----------|
| 11-20 | 14 | 0 |
| 21-30 | 22 | 1 |
| 31-40 | 22 | 1 |
| 41-50 | 27 | 6 |
| 51-60 | 5 | 0 |
| 61-70 | 0 | 1 |
| >70 | 0 | 1 |

Table 2. Distribution of Benign and Malignant Tumours in Various Age Groups

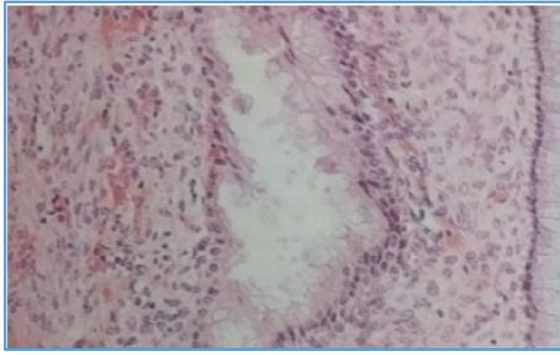


Figure 4. Microphotograph of Mucinous Cystadenoma of Ovary Showing Columnar Cells Lining the Cysts

Out of the malignant tumour, majority was squamous cell carcinoma of cervix containing of 7 cases (7%) of the total tumours (figure 3). One case of malignant tumour was immature teratoma of ovary (table 1).

DISCUSSION

Incidence of carcinoma cervix has declined in developed countries, cervix is still the one most common histopathological specimen in pathology department.² The diagnosis of cervical lesions is grossly neglected.³ Many of the female genital tract malignancies are known as silent killers because many women in developing countries attend the clinic in advanced stage of disease, Regular screenings, self-examination, patient's awareness of family history and life style changes such as exercise and diet can result in the decline of many types of these malignancies.

HPV cervicitis is particularly a high-risk type cervicitis that results in cervical cancer in worldwide population. Koilocytosis is considered as the histological hallmark of papilloma virus infection. It has been proved by various studies that association of HPV infection, HIV infection and lower CD4 counts have predisposed to cervical intraepithelial carcinoma and malignancy. The specificity of diagnosis of HPV has increased by technique like polymerase chain reaction, HPV genotyping, in situ hybridization and molecular studies. Therefore, the timely detection of HPV cervicitis reduces the frequency of malignancies. HPV vaccine plays a important role in the prevention of cervical cancer in developing countries.

We could not perform Elisa, HPV serology and immunohistochemistry in this study due to their non-availability in our setup and high cost. The effectiveness of Pap test in detecting cervical precancers, easy accessibility to cervix by colposcopy and biopsy are the best tool for early detection and eradication of preinvasive lesions, some of it may progressed to cancer if not diagnosed and treated timely.

Many FGT specimens were received in the pathology department after surgical biopsy. The patients get operated for both benign and malignant lesions. It is very difficult to diagnose malignancy before surgery. Though clinical history, signs and symptoms, USG and FNAC help in provisional diagnosis.

Benign Tumours

Leiomyoma uterus is the most frequent reported tumour in genital tract. Three types are usually found-intramural, sub-serosal and sub-mucosal. It has been studied that over 70% of the female by the time of menopause may present with uterine fibroid.⁴⁻⁶ Development of the fibroid depends on the age of patient. It has been seen that this tumour is ten times more common in women in their fifth and sixth decade of life as compared to those in their third decades.⁷⁻⁸

Also, in our study, the commonest tumour occurring in the FGT was leiomyoma comprising of the total 64% of the total neoplasm. The most common site of occurrence was the body of uterus and one was seen in the cervix.

Neoplasms of ovaries are classified into three groups-surface epithelial tumours, germ cell tumours and sex-cord stromal tumours, each group includes both benign and malignant tumour.

Mature cystic teratoma was the commonest benign tumour of ovary in our study which comprised of 46.42% of the total neoplasm occurring in ovary. Study of Malaysian women also showed that mature cystic teratoma was the commonest benign tumour of ovary.⁹ The second most common tumour was mucinous cystadenoma followed by serous cystadenoma of ovaries. Both were cystic in nature. On naked eye examination, serous neoplasm showed uniloculated cyst filled with serous fluid and mucinous neoplasm showed multiloculated cyst filled with gelatinous material. On microscopic examination serous cystadenoma showed cyst lined by single layer of ciliated columnar epithelial cells and mucinous cystadenoma reveal cysts lined by tall columnar epithelial cells with presence of apical mucin. There were no nuclear atypia and cellular pleomorphism in these tumours.

Western literature states that serous and mucinous cystadenoma of ovaries comprise 58% of all ovarian tumours. But their incidence is less in the study done in east.¹⁰⁻¹² Our study showed 50% of serous and mucinous cystadenomas out of total ovarian tumours.

Malignant Tumours

In our study the commonest malignant tumour was squamous cell carcinoma of cervix, comprising of 7% of the total neoplasms. In some countries the incidence of cervical cancer and the mortality from cervical carcinoma are markedly declined due to the screening programmes like regular cervical pap smear examination. Human Papilloma Virus (HPV) type 16 and type 18 infection is the major cause of development of cervical cancer. In late 1980, the vaccine against HPV infection was developed. But due to lack of awareness and high cost of vaccine it has become difficult to implement the vaccine programme in India this is the reason that 80% cervical cancer occurs in developing countries and it account for the fourth common cause of mortality among all cancers.¹³ The two major histologic types of cervical cancers are squamous cell carcinoma and adenocarcinoma. In our study all the cervical cancers was squamous cell carcinoma.

In our study only one immature teratoma was found. Grossly, it is presented as an enlarged cystic ovary with few foci of solid mass. Microscopic examination showed mature cell components from all the germ layers as well as immature neuroepithelial cells. We did not find any case of neoplastic lesion of endometrium, vulva, vagina and fallopian tube. This may be due to small sample size.

CONCLUSION

In our study, sample size is small but still the incidence of various neoplasms correlate with other studies of big sample size. Again, in this study, leiomyoma was the most common benign tumour and cervical carcinoma was the commonest malignant tumour. To reduce the incidence of cervical carcinoma, regular effective pap smear screening programme covering the major population of sexually active women should be organised by Indian Government and NGOs.

REFERENCES

- [1] Stewart BW, Kleihues P, eds. Cancers of the female reproductive tract. In: World cancer report. Lyon, France: IARC Press 2003.
- [2] Wright CT, Ferenczy A. Benign disease of cervix. In: Kurman RT, ed. Blaustein's pathology of female genital tract. 5th edn. New Delhi: Springer Verlag 2002:225-252.
- [3] Craig P, Lowe D. Non-neoplastic lesions of the cervix. In: Fox H, Well M, eds. Haines and Taylor obstetrical and gynaecological pathology. 5th edn. Edinburgh: Churchill Livingstone 2003:273-296.
- [4] Boosz AS, Reimer P, Matzko M, et al. The conservative and interventional treatment of fibroids. *Dtsch Arztebl Int* 2014;111(51-52):877-883.
- [5] Flake GP, Andersen J, Dixon D. Etiology and pathogenesis of uterine leiomyomas: a review. *Environ Health Perspect* 2003;111(8):1037-1054.
- [6] Baird DD, Dunson DB, Hill MC, et al. High cumulative incidence of uterine leiomyoma in black and white women: ultrasound evidence. *Am J Obstet Gynaecol* 2003;188(1):100-107.
- [7] Baird DD, Dunson DB, Hill MC, et al. Association of physical activity with development of uterine leiomyoma. *Am J Epidemiol* 2007;165(2):157-163.
- [8] Lurie S, Piper I, Woliiovitch I, et al. Age related prevalence of sonographically confirmed uterine myomas. *J Obstet Gynaecol* 2005;25(1):42-44.
- [9] Thanikasalam K, Ho CM, Adeed N, et al. Pattern of ovarian tumours among Malaysian women at general hospital, Kuala Lumpur. *Med J Malaysia* 1992;47(2):139-146.
- [10] Scully RE, Clement PB, Young RH. Ovarian surface epithelial stromal tumours. In: Carter D, Greenson JK, Oberman HA, et al, eds. Sternberg's diagnostic surgical pathology. 4th edn. Lippincott Williams and Wilkins Philadelphia 2004:2543-2573.
- [11] Scully RE, Young RH, Clement PB. Tumour of the ovary, maldeveloped gonads, fallopian tube, and broad ligament. *Inter J Gynecol Pathol* 1999;18(3):288.
- [12] Zaloudek C. Tumours of the ovary. In: Fletcher CDM, ed. Diagnostic histopathology of tumours. 2nd edn. Philadelphia: Churchill Livingstone 2005:567-641.
- [13] Schottenfeld D, Fraumeni JF, eds. Cancer epidemiology and prevention. Oxford University Press 2006.