

## ISOLATION OF CRYPTOCOCCUS LAURENTII FROM CONSTRUCTION WORKER WITH PANSINUSITIS - ? AN OCCUPATIONAL HAZARD

Ajita Anand<sup>1</sup>, Saranya Cheriyaomath<sup>2</sup>, Balakrishnan Edacherian<sup>3</sup>, Rajan Joseph Payyappilly<sup>4</sup>

<sup>1</sup>Lecturer, Department of Microbiology, ACME, Pariyaram, Kerala.

<sup>2</sup>Postgraduate Student, Department of Microbiology, ACME, Pariyaram, Kerala.

<sup>3</sup>Professor and Head, Department of Microbiology, ACME, Pariyaram, Kerala.

<sup>4</sup>Professor and Head, Department of Microbiology, ACME, Pariyaram, Kerala.

**HOW TO CITE THIS ARTICLE:** Anand A, Cheriyaomath S, Edacherian B, et al. Isolation of Cryptococcus laurentii from construction worker with pansinusitis - ? An occupational hazard. J. Evid. Based Med. Healthc. 2019; 6(3), 191-193. DOI: 10.18410/jebmh/2019/38

### PRESENTATION OF A CASE

A 51 year old women who is a construction worker, presented with right sided facial pain for the past 2 weeks. She also complained of right sided nasal obstruction followed by foul smelling nasal discharge which was initially yellow and later becoming greyish yellow for 4-5 days and presented at ENT OPD of ACME, Pariyaram. She is a known case of diabetes mellitus and on treatment since 10 years (Inj Human Actrapid 20-20-16) and hypothyroidism on treatment since 1 month (Eltroxin 25 µg). She has frequent contact with soil and cement as she is a construction worker. She has an in-house chicken farm. She is having 2 healthy children and she achieved menopause 2 years ago.

On examination, middle aged women of an average built and well-nourished women with pallor (+), icterus, cyanosis, clubbing, lymphadenopathy and oedema absent. On systemic examination, S1, S2 present with no murmur on cardiovascular examination, normal vesicular breath sound on respiratory examination, per abdomen was soft. Pulse rate -76/minute, BP was 140/90 mm Hg, respiratory rate was 20 per cycle per minute., FBS-209 mg/dL, PPBS-205 mg/dL, T3-70 ng/dL, T4 -11.0 mcg/dL and TSH- 1.64 IU/ml. On examination of nose there is DNS to left side, right middle turbinate enlarged and congested with mucopus ; frontal and maxillary sinus tenderness (+). Nasal endoscopy showing right middle turbinate polypoidal in the middle turbinate; mucopus (+) on the left side pedunculated non-haemorrhagic polyp was seen in middle meatus; DNS (+).

### DIFFERENTIAL DIAGNOSIS

Infection Causing Sinusitis.

Rhinosporidiosis.

Malignancy of Paranasal Sinuses.

Foreign Body.

*Financial or Other, Competing Interest: None.  
Submission 30-12-2018, Peer Review 03-01-2019,  
Acceptance 16-01-2019, Published 21-01-2019.*

*Corresponding Author:*

*Dr. Saranya C. K.,  
Cheriyaomath House,  
Ulikkal P.O., Kannur- 670705,  
Kerala.*

*E-mail: spythmorris@gmail.com*

*DOI: 10.18410/jebmh/2019/38*



### PATHOLOGICAL DISCUSSION

She underwent FESS + septoplasty under general anaesthesia and two samples of nasal secretion collected during surgery was sent for fungal culture to the Department of microbiology, ACME, Pariyaram Medical College.

The nasal secretion received in a sterile container was taken for a microscopic examination, gram staining of nasal secretion showed gram positive budding yeast cells and in modified acid fast staining no acid fast bacilli was seen. On 10% KOH mount also yeast cells were seen. One sample inoculated on MacConkey agar, blood agar and chocolate agar with CO<sub>2</sub> for bacterial culture and other sample inoculated on Sabouraud's dextrose agar with chloramphenicol for fungal culture. On bacterial culture normal flora obtained. On Sabouraud's dextrose agar with chloramphenicol after 8 days of incubation at 25°C shows orange coloured highly mucoid colony. Colony on SDA inoculated in yeast chrome agar to rule out candida species; but there were no colour change which suggestive of candida. Colony has same morphology as seen on SDA. Next step was staining it with India ink preparation in which round to oval yeast cells with capsules were present. Following which we have done biochemical reactions such as urease and assimilation of sugars. Yeast panel was selected for identification on Vitek II, Fully automated microbiology system.

On next day the urease test was positive and assimilation of sugar test shows utilisation of glucose, sucrose, lactose, and maltose. And Vitek II identified growth as Cr.laurentii.

The urine and sputum culture done to rule out any of genitourinary and respiratory system involvement.

The sputum and urine sample also collected and processed. Gram staining of sputum done which shows epithelial cells 6-8/LPF, pus cells 1-2/OIF, gram positive cocci in pairs and chains(+), occasional gram negative cocco bacilli seen. Wet mount of urine shows epithelial cells 1-2 /LPF, pus cells nil.

Sputum and urine sample cultured on MacConkey agar, blood agar and SDA. In urine culture, both blood agar and MacConkey agar shows no bacteriuria. In sputum culture it was normal upper respiratory tract flora. And in SDA there was no growth after 14 days of incubation.

HIV test was done earlier by the patient and the test was negative (ELISA).

**Following Criteria Were Used for Identification**

1. KOH mount: round yeast cells (Figure 1)
2. Colony morphology on SDA with chloramphenicol: orange coloured highly mucoid colony (Figure 2)
3. Gram staining: gram positive budding yeast cells (Figure 3)
4. Yeast chrome agar: colonies grown as same of SDA (no features suggestive of candida species) (Figure 4)
5. India ink preparation: round to oval yeast cell with capsule (Figure 5)
6. Biochemical reaction:
  - Urease – positive (Figure 6)
  - Glucose – positive (Figure 7)
  - Lactose – positive
  - Sucrose – positive
  - Maltose – positive
7. Vitek II, fully automated microbiological analyser: the system identified the growth as *Cryptococcus laurentii*.

**DISCUSSION OF MANAGEMENT**

*Cr.laurentii* is the most common yeast found in Tundra; Antarctica and Prairie soils; as well as the phyllosphere of numerous ecosystems. *Cr.laurentii* is a psychrophilic organism and it grows poorly at temperature above 30°C.

*Cryptococcus* disease is also known as Busse Buschke's disease European Blastomycosis or Torulosis. Previously the disease was latent but it has been steadily increasing in incidence.<sup>1</sup>

*Cryptococci* generally occur in soil and contaminated with pigeon faeces<sup>2</sup> and are transmitted to humans primarily through inhaled fomites. Species other than *Cryptococcus neoformans* have generally being thought to be non-pathogenic to humans.<sup>3-5</sup> Although *Cr.laurentii* has been reported as occurring worldwide. Its natural habitat has to be not yet been thoroughly established.

In the present case she is a known case of diabetic mellitus and was on oral hyperglycaemic agents and changed to insulin one month back and she was also taking Eltroxin 25 microgram for hypothyroidism.

She has been working in a construction site for about 15 years. And having frequent contact with sand, soil, and various chemical agents like cement. So in this case route of entry of infection may be through airborne, cutaneous or percutaneous.

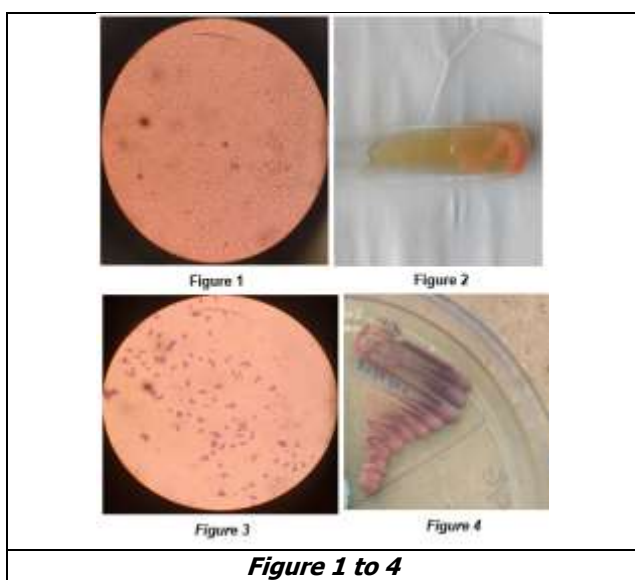
Feral pigeons may be carriers of *Cr.laurentii*<sup>6</sup> but details of previous contact with pigeons were unavailable. She did, however live in close proximity to agricultural areas and pastures, and construction of bridge was also running near her house. Because isolation of *Cr.laurentii* from plants and soils has been previously reported,<sup>7</sup> a rural habitat and possible exposure to yeast, combined with underlying predisposing condition, may have made her vulnerable to infection.

Virtually all *Cryptococci* (both neoformans and non-neoformans species) have the enzyme urease and can hydrolyse urea to ammonia, thus increasing the ambient pH. This property can be detected by using various broths containing urea and pH maker.<sup>8</sup>

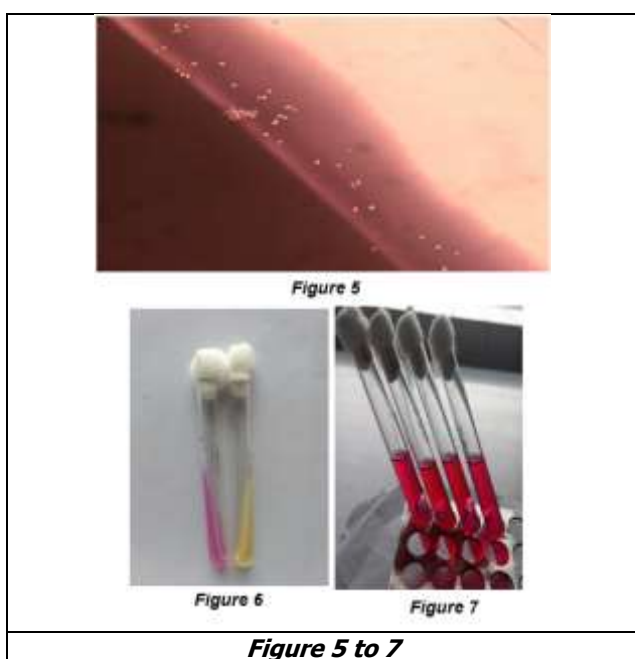
For the completion of this study, we collected soil and sand from working site (on examination river sand contain large amount of decaying organic impurities) home and chicken farm and also chicken faeces collected and cultured to see any growth of same organism.

From the samples collected from home and chicken farm we isolated *Aspergillus Niger*, penicillium species and candida species. Candida species and saprophytic fungus isolated from soil and sand collected from work site. *Cr.laurentii* not isolated from above samples.

In the present case report she was presented with pansinusitis also known case of diabetic mellitus and hypothyroidism but her HIV status was negative. She has exposure to cement, sand, M sand as part of her occupation for a long time about 25 years. In this case exposure of dust occurred when she emptied bags of cement, such exposure irritates the nose and throat and causes choking and difficulty in breathing. The grain size of M sand is more when compared it with river sand. So there is a chance of more



**Figure 1 to 4**



**Figure 5 to 7**

chemical and mucosal corrosion. And here prolonged and repeated exposure leads to inflammation of mucous membrane of nose and paranasal sinuses. Nowadays due to depletion of river sand, M sand is widely used along with river sand which contain more amount of organic impurities.

The rising incidence of *Cryptococcus* infections should be considered as an alarming signal. With high degree of clinical suspicion, improved culture methods and identification techniques like Vitek II can contribute to the diagnosis of unusual fungal infections.

#### REFERENCES

- [1] Nayak JB, Brahmabaht MN, Savalia CV, et al. Cryptococcosis: a garded mycosis threat. Research Journal of Veterinary Sciences 2010;3(2):101-112.
- [2] Chand-Goyal T, Spotts RA. Enumeration of bacterial and yeast colonies of apple fruits and identification of epiphytic yeasts on pear fruits in the Pacific Northwest United states. Microbial Res 1996;151(4):427-432.
- [3] Ritterband DC, Seedor JA, Shah MK, et al. A unique case of *Cryptococcus laurentii* keratitis spread by a rigid gas permeable contact lens in a patient with onychomycosis. Cornea 1998;17(1):115-118.
- [4] Custis PH, Haller JA, de Juan E. An unusual case of Cryptococcal endophthalmitis. Retina 1995;15(4):300-304.
- [5] Lynch JP, Schaberg DR, Kissner DG, et al. *Cryptococcus laurentii* lung abscess. Am Rev Respir Dis 1981;123(1):135-138.
- [6] Mattsson R, Haemig PD, Olsen B. Feral pigeons as carriers of *Cryptococcus laurentii*, *Cryptococcus uniguttulatus* and *debaryomyces hensenii*. Med Mycol 1999;37(5):367-369.
- [7] Fell JW, Statzell-Tallman A. *Cryptococcus willemin*. In: Kurtzman CP, Fell JW, eds. The yeasts - a taxonomic study. 4<sup>th</sup> edn. Amsterdam: Elsevier 1988:742-767.
- [8] Li A, Wu S. An urease negative *Cryptococcus neoformans*. Acta Microbial Sinica 1992;32(1):68-67.