

Morphometric Analysis of Spleen in Eastern Uttar Pradesh Population – A Cadaveric Study

Gunjan Rai¹, Soumya Khanna², Royana Singh³, Chandramayee Mohanty⁴

¹Assistant Professor, Department of Anatomy, Institute of Medical Sciences, Banaras Hindu University, Varanasi, Uttar Pradesh, India. ²Assistant Professor, Department of Anatomy, Institute of Medical Sciences, Banaras Hindu University, Varanasi, Uttar Pradesh, India. ³Professor, Department of Anatomy, Institute of Medical Sciences, Banaras Hindu University, Varanasi, Uttar Pradesh, India. ⁴Professor, Department of Anatomy, Institute of Medical Sciences, Banaras Hindu University, Varanasi, Uttar Pradesh, India.

ABSTRACT

BACKGROUND

Spleen is the largest lymphatic organ having an important role in immunological and haematological response of the body. A surgeon should prefer a conservative approach in case of splenic injury. It varies a lot variation in shape, size and other morphometric parameters which should be kept in mind while examining and / or operating on a patient. The present study focuses on morphometric analysis of cadaveric spleen and its comparison with other previous studies.

METHODS

A total number of 49 human cadaveric spleens obtained from the Department of Anatomy, Institute of Medical Sciences, Varanasi, were selected for morphometric studies. The length, breadth and width were measured using a measuring tape and a digital vernier callipers. Weight was measured using an electronic weighing machine. Data obtained was tabulated and statistically analysed in Microsoft Excel. Others features like variation in shape was noted down. Notches on the superior and inferior borders and fissures on diaphragmatic and visceral surfaces were also studied.

RESULTS

Out of 49 cases, lengths of the spleens ranged between 5.1 cms and 13.6 cms, with an average length of 9.53 cms. Breadth was observed to vary between 3.2 cms and 9.2 cms, with an average breadth of 6.12 cms., width of the spleens varied from 1.8 cms to 7.1 cms, with an average width of 3.52 cms. Out of 49 spleens, wedge shaped (61.22 %) was the most common followed by tetrahedral (20.41 %) shape, triangular (12.24 %) shape, oval (4.08 %) shape and semilunar (2.08 %) shape. The number of notches varied from zero to four, but in most of the cases there were 1 or 2 notches. The maximum number of notches were found to be four and they were present on the superior border of spleen. Out of 49 specimens, 55.10 % spleens had notches on superior border, 12.24 % on inferior border, and 8.16 % on both the borders. There was absence of notch in 20.41 % of spleens. 4.08% had anomalous fissures on diaphragmatic surface in which one of the fissure was H shaped.

CONCLUSIONS

The findings of the present study will be useful to anatomists in their routine dissection classes as well as for clinicians in the diagnosis of various clinical diseases of spleen.

KEYWORDS

Anomaly, Variation, Splenic Notch, Splenic Fissure, Hilum

Corresponding Author:

*Dr. Soumya Khanna,
Department of Anatomy,
Institute of Medical Sciences,
Banaras Hindu University,
Varanasi - 221005, Uttar Pradesh, India.
E-mail: khannasoumya15@gmail.com*

DOI: 10.18410/jebmh/2020/351

How to Cite This Article:

*Rai G, Khanna S, Singh R, et al.
Morphometric analysis of spleen in
eastern up population – a cadaveric
study J Evid Based Med Healthc 2020;
7(33), 1683-1687. DOI:
10.18410/jebmh/2020/351*

*Submission 20-06-2020,
Peer Review 25-06-2020,
Acceptance 11-07-2020,
Published 17-08-2020.*

*Copyright © 2020 JEBMH. This is an
open access article distributed under
Creative Commons Attribution License
[Attribution 4.0 International (CC BY
4.0)]*

BACKGROUND

Spleen is the largest lymphatic organ. It is located in the left hypochondrium of abdominal cavity. It is a graveyard of RBCs and also the storage site of platelets and blood. It filters the blood and protect the body against the infections. It is having two poles and two surfaces- anterior and posterior poles and diaphragmatic or super lateral and visceral or infer medial surface. The anterior pole is broad and faces laterally. The posterior pole faces medially towards the vertebral column.¹ The diaphragmatic surface is smooth and convex. It is covered by peritoneum and is related to abdominal surface of left dome of diaphragm which separate it from basal pleura, lower lobe of left lung and ninth to eleventh ribs. Its visceral surface is irregular and faces infer medially towards the abdominal cavity. It is having impressions for the left kidney, tail of pancreas, left colic flexures and fundus of stomach.¹ The hilum of the spleen is located between the impressions of stomach and left kidney. The long axis of the hilum lies along the line of tenth rib. The spleen is connected to posterior abdominal fold via fold of peritoneum (lien renal, phrenic colic and phrenosplenic ligament) and to the anterolateral abdominal wall and stomach by the gastro splenic ligament.²

The tail of pancreas lies within the lien renal ligament and makes contact with the hilum of spleen. Spleen is having three borders - superior, inferior and intermediate. It is of different shapes owing to its relation with nearby organs. The shapes may vary from curved wedge shaped to tetrahedron. The size of the adult spleen is usually 12 cms long, 7 cms breadth and 3 - 4 cms width. Weight of the spleen range from 80 gms to 300 gms and average being 150 gms (Gray's 2005).² The development of spleen occurs in the form of mesodermal condensations in cephalic part of dorsal mesogastrum, during sixth week of intrauterine life (Sadler, 2000).³ The spleen comes to lie at the left margin of lesser sac. During the development spleen is present in form of splenic nodules (splines). These splenic nodules may fuse wholly or partially. The partial fusion of splenic nodules results in formation of splenic notches at various borders of spleen. Sometimes improper fusion can result in formation of splenic fissure present on diaphragmatic or visceral surface of spleen.¹ Spleen gets enlarged in certain pathological conditions like infectious mononucleosis, leukemia, malaria, kala-azar, bacterial infections and liver diseases. Normally spleen is not palpable but it gets palpable when its size becomes two to three times of its normal size. The spleen enlarges towards the umbilical region.⁴ Present study has been carried out to find morphometric variations of spleen in formalin preserved cadavers in eastern UP population and compare it with other available literatures.

METHODS

The study was done in the Department of Anatomy IMS, BHU. The spleens were removed after dissecting splenic vessels in cadaveric dissection of abdominal region by MBBS students. The organs were preserved in 40 % formalin with

1:9 water. We studied on 49 stored spleen under following parameters-

1. Shape of spleen.
2. Length in cms, breadth in cms, width in cms.
3. Weight in grams.
4. Location of notch-superior border, inferior border or both.
5. No. of notches.
6. Presence of fissures on diaphragmatic or visceral surfaces.
7. Accessory splenic tissue at hilum.

The measurement of length, breadth and width were taken by using measuring tape and digital vernier callipers. The maximum length was taken between anterior and posterior pole along the long axis and breath was obtained between upper and lower border perpendicular to maximum length. The maximum width of all the spleens have been noted. Weight was taken by electronic weighing machine. The data obtained, was tabulated, statistically analysed in Microsoft excel and compared with that of other studies. The spleens were photographed and variation related to above parameter were documented.

RESULTS

Among the 49 spleens observed, 30 (61.22 %) were wedge shaped, 10 (20.41 %) tetrahedral, 6 (12.24 %) triangular, 2 (4.08 %) oval shaped and one (2.08 %) was of semilunar shape. (Fig 1) One of the tetrahedral shaped spleens had an abnormal protrusion towards the anterior pole on the superior border as depicted in Fig 2. The number of notches on the superior border ranged between 1 to 4 while on inferior border it was limited to one (Fig 3). The maximum number of notches on the superior border of spleen was 4. Out of 49 specimens, 27 (55.10 %) spleens had notches on superior border, 6 (12.24 %) on inferior border, 4 (8.16 %) on both the borders. There was absence of notch in 10 (20.41 %) spleens. Two spleens (4.08 %) had anomalous fissures on diaphragmatic surface (Fig 4).

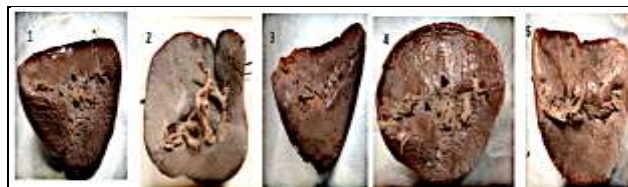

Figure 1. Different Shapes of Spleen. 1 - Wedge Shape, 2 - Tetrahedral Shape, 3 - Triangular, 4 - Oval. 5 - Semilunar




Figure 2. Tetrahedral Shaped Spleen with Tongue Shaped Protrusion towards the Anterior Pole on the Superior Border

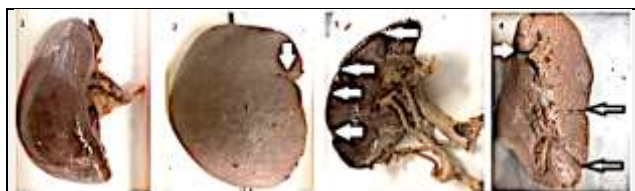

Figure 3. Variation of Notches. 1 - No Notch, 2 - One Notch in the Superior Border, 3 - Four Notches on the Superior Border, 4 - Two Notches on Sup. Border & One Notch on Inf. Border

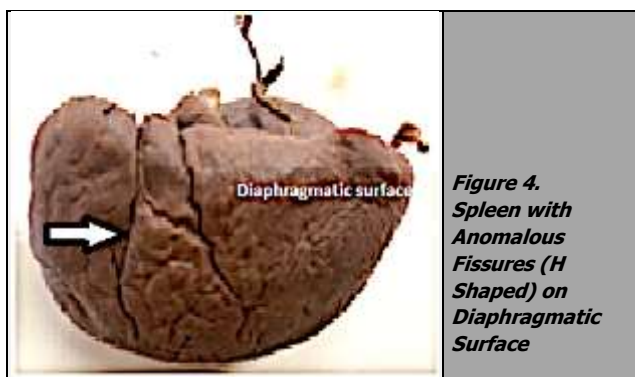


Figure 4. Spleen with Anomalous Fissures (H Shaped) on Diaphragmatic Surface

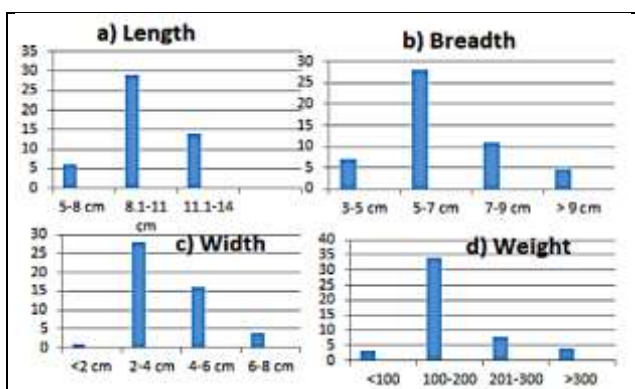


Figure 5. Showing Number of Spleens (Y Axis) and Morphometric Parameters on X Axis Namely Length, Breadth, Width and Weight of Spleen

The minimum weight of spleen observed was found to be 70 gms whereas the maximum weight was 320 gms. Out of the 49 spleens observed 34 (69.39%) laid in the range of 100-200 gm, in 8 specimens (16.38%) 201-300 gm, in 4 specimens (8.16 %) > 300 gm. 3 spleen weighed below 100 gm (6.12 %). The length of spleen varied from 8.1 - 11 cms in 28 cases (57.14 %), 11.1 - 14 cms in 15 cases (30.61 %) and 5 - 8 cms (12.24 %) in 6 cases. The breadth of spleen varied from 3 - 5 cms in 7 cases (14.28 %), 5 - 7 cms in 27 cases (55.10 %), 7 - 9 cms in 11 cases (22.45 %), > 9 cms in 4 cases (8.16 %). The width of the spleen was in the range 2 - 4 cms in 28 cases (57.14 %), 4 - 6 cms in 16 cases (32.65 %), and 6 - 8 cms in 4 cases (8.16 %) and of < 2 cms in 1 case (2.04 %).

DISCUSSION

In the early twentieth century, spleen was not considered as significant organ;⁵ but now it is known to be having crucial role in haematological and immunological functions of body. The size and weight of the spleen varies with age and sex.²

It can also vary in the same individual under different conditions. One of the most common congenital anomalies of the spleen is the presence of accessory spleens in various parts of the abdominal cavity in addition to the spleen.⁶ The accessory spleens are seen in about 10-15 % of individuals, out of which 1-2 % may be located in the tail of the pancreas.⁷ According to the study conducted by Souparis et al.,⁸ presence of retroperitoneal accessory spleens may mimic retroperitoneal tumors with the history of epigastric pain, intermittent nausea and vomiting. In the present study we did not get any accessory spleen. This might be due to the already stored spleens which were obtained by the students by ligating and cutting away the structures passing through hilum during their routine dissection.

The length of the spleen in present study varied between 5.1 cms to 13.6 cms with the maximum number of spleens lying in range of 8.1 to 11 cms. The average length of spleen was found to be 9.53 cms which is on a lower side as compared to previous studies done by Chaware et al⁹ (9.66 cm), Chaudhari et al¹⁰ (9.59 cm), Sangeeta et al¹¹ (9.68 cm) and Rao et al¹² (10.15 cm) (Table 1). The breadth of the spleen varied between the ranges of 5.1 cms to 10.5 cms with the maximum number of spleens lying in range of 5 to 7 cms. The average breadth of spleen was found to be 6.12 cms which is on a lower side as compared to previous studies done by Chaware et al⁹ (6.22 cm), Chaudhari et al¹⁰ (6.59 cm), Sangeeta et al¹¹ (6.64 cm) and Rao et al¹² (8.3 cm) [Table 1].

The width of the spleen varied between the range of 1.8 cms to 7.1 cms with the maximum number of spleens lying in range of 2 to 4 cms. The average width (3.52 cm) was higher than Chaware et al⁹ (3.06) [Table 1]. The average weight of spleen was 150.18 gms which is comparable to Chaudhari et al¹⁰ whose average weight was 150 gms [Table 1]. These variations in findings may be due to the differences in the genetic factors, socioeconomic status, and geographical conditions.

Dimension (cm)	Chaware et al ⁹	Chaudari et al ¹⁰	Sangeeta et al ¹¹	Rao et al ¹²	Present study
Average Length	9.66	9.59	9.68	10.15	9.53
Average Breadth	6.22	6.59	6.84	8.30	6.12
Average width	3.06	4.54	3.61	3.96	3.52
Average weight (gms)	145.76	150	-	138.40	150.18
Weight range (gms)	80 - 300	80 - 350	53 - 444	30 - 3	70 - 320

Table 1. Comparison of Morphometric Parameters with Those of Previous Studies

Shape	Chaware et al ⁹ (%)	Chaudari et al ¹⁰ (%)	Sangeeta et al ¹¹ (%)	Rao et al ¹² (%)	Present Study (%)
Wedge	61.26	33.87	33.9	40	61.22
Tetrahedral	21.61	32.25	15	20	20.41
Triangular	12.61	19.35	33.9	32	12.24
Oval	3.60	8.06	9.4	8	4.08
Irregular	0.09	6.45			
Semilunar			3.7		2.04
Heart			3.7		

Table 2. Comparison of Shape of Spleen with Those of Previous Studies

In the present study most common shape of the spleen was wedge shaped and was present in 61.22 % cases which is comparable to Chaware et al who reported the shape to be present in 61.26 % cases. The second most common shape was tetrahedral (20.41 %) which is comparable to

Rao et al who found 20 % tetrahedral shaped spleens. In present study one of the tetrahedral shaped spleen was having a tongue shaped protrusion (Figure 2). On the anterior pole near the superior border. This finding has not been reported in any of the previous studies.

In the developmental period, the spleen develops from mesoderm and different lobules are formed which fuse with each other later. Improper fusion of splenic nodules result in formation of notch on borders of spleen. Presence of notches on the superior border is useful for the clinician to palpate the spleen during enlargement of spleen. The spleen in carnivores is large with notch on all the borders whereas spleen is less notched in anthropoids (Parson 1901).¹³ In the present study 27 (55.10 %) spleens had notches on the superior border. Other previous studies showed presence of notches on the superior order in 98 % of cases by Daset al,¹⁴ 78.6% of cases by Skandalakis et al¹⁵ and 50% of cases by Sateeshaet al.¹⁶

In the present study we observed 6 (12.24 %) spleens having notch on the inferior border which is higher as compared to the observations of Parsons¹³ and Das et al¹⁴ who reported the incidence to be 8 % and 2 % respectively. Unnotched spleens are a characteristic feature of Rodents.¹³ In the present study, there were 10 (20.41 %) unnotched spleens. The perfect fusion of splenic nodules result in development of unnotched spleens. The Percentage of incidence of unnotched as reported by Setty et al¹⁷ and Girish et al⁴ were 16% and 1.67% respectively which is lower as compared with the present study. In case of splenomegaly of unnotched spleen, the clinician may mistake it as a case of renal swelling on palpation. This confusion can be ruled out by percussion as renal swelling is resonant on percussion. It has slight movement on respiration, is ballot able and is bimanually palpable by insinuation of the hand in between the renal swelling and anterior abdominal wall.

Out of 100 cases Das et al 2008 has reported the single case of presence of fissure on the diaphragmatic surface. We have also found two case out of 49 cases. Out of two specimens of fissures, one had H shaped fissure on the diaphragmatic surface as seen in Fig 4. This shape of fissure has not been documented in previous studies. According to the Parson's,¹³ one of mechanism behind this diaphragmatic surface fissures could be the evolutionary cause i.e. persistence of lobulation pattern of ancestral spleen and the other one may be the mechanical cause related with the growth of spleen and its surrounding viscera. Presence of fissures on the diaphragmatic surface may be confused for lacerations of the spleen in case of abdominal trauma when radio logically investigated. Smidt reported a case of large congenital fissure mimicking splenic hematoma. [18] Knowledge of splenic fissure is essential for the radiologist to avoid any misinterpretation. In contest enhanced CT scan the radiologist can differentiate fissures from the laceration by its smooth contour and sharply defined margins.

During extensive splenic injuries, the surgeon must avoid total splenectomy as it has an important role in immune function. The partial splenectomy is preferred as there is rapid regeneration of lost tissue it which avoids post-

operative complications such as overwhelming Post splenectomy sepsis syndrome (OPSS).²

CONCLUSIONS

Detailed anatomical knowledge is not only important from academic point of view, but is also important for the clinicians, surgeons and radiologists for accurate clinical diagnosis and treatment of diseases. We observed few spleens with no notches. If this kind of spleen gets enlarged, it may be confused with left renal swelling on palpation. In the present study, we observed fissures on visceral surface extending till diaphragmatic fissure. This kind of spleen when examined radiologically may mimic splenic laceration. To avoid any complication, splenic variations should be kept in mind while performing diagnostic and surgical procedures.

Financial or Other Competing Interests: None.

REFERENCES

- [1] Sinnatamby, Chummy S, and R J. Last. Last's Anatomy: Regional and Applied. Edinburgh: Churchill Livingstone, 2011; 270 - 272.
- [2] Stranding S: Gray's Anatomy: The Anatomical Basis of the Clinical Practice, 39th edition. Edinburg: Elsevier Churchill Livingstone, 2006; 1239-44.
- [3] Sadler, T. W. Langman's Medical Embryology. Baltimore, Lippincott Williams & Wilkins, 2000. 277.
- [4] Girish v. Patil, Shishirkumar, Apoorva D, Thejeswari, Javed sharif, C. Sheshgiri & Sushanth, N. K. Study of splenic notches in a human cadaver, International Journal of Recent Advances in Multidisciplinary Research. 2014; 1(2): p.001- 003.
- [5] Jakubovský J, Porubský J. Funkcnámorfológiásleziiny [Functional morphology of the spleen]. BratisLekListy. 1995; 96(12): 637 - 641.
- [6] Gayer G, Hertz M, Strauss S, Zissin R. Congenital anomalies of the spleen. Semin Ultrasound CT MR. 2006; 27: 358–369.
- [7] Weiland G, Mangold G. Accessory spleen in the pancreatic tail - a neglected entity? A contribution to embryology, topography and pathology of ectopic splenic tissue. Chirur. 2003; 74: 1170 – 1177. (German).
- [8] Souparis A, Pappayiorgas B, Alexandrakis A, Koutelidakis J, Paraskevas G, Papaziogas T. An unusual case of retroperitoneal accessory spleen with vascular supply directly from the aorta. Minerva Chir. 2002; 57: 513–515.
- [9] Chaware PN, Belsare SM, Kulkarni YR. Morphological variations of the human spleen. J Clin Diagn Res 2012; 6:159 - 62.
- [10] Chaudari ML, Maheria PB, Lakhani C. Morphological variations of human spleen and its clinical significance. Int J Med Res Rev 2014; 2: 16 - 9.

- [11] Sangeeta M, Varalakshmi KL, Sahana BN. Cadaveric study of morphometry of spleen. *J Med Sci Health* 2015; 1(3): 14 - 17.
- [12] Rao S, Katikireddi S. Morphometric study of human spleen. *Int J Biol Med Res* 2013; 4: 3464 - 8.
- [13] Parsons, F.G. Notches and Fissures of the Spleen. *J Anat Physiol.* 1901 I; 35(3): 416–427.
- [14] Das S, Abd Latiff A, Suhaimi FH, Ghazalli H, Othman F. Anomalous splenic notches: A cadaveric study with clinical importance. *Bratisl Lek Listy* 2008; 109: 513 - 6.
- [15] Skandalakis PN, Colborn GL, Skandalakis LJ, Richardson DD, Mitchell WE Jr, Skandalakis JE. The surgical anatomy of the spleen. *Surg Clin North Am* 1993; 73: 747-68.
- [16] Sateesha NB, Somayaji SN, Soumya KV. A study on the variations of size, shape and external features of the spleen in South Indian population. *Int J Morphol* 2011; 29: 675-7.
- [17] Setty SNRS, Katikireddi RS. A cadaveric study of human splenic notches and fissures. *Int J Health Sci Res.* 2013; 3(9):40-44.
- [18] Smidt KP. Splenic scintigraphy: a large congenital fissure mimicking splenic hematoma. *Radiology.* 1977; 122: 169.