

MRCP AND ERCP IN DIAGNOSIS OF OBSTRUCTIVE JAUNDICEBheemashanker¹¹Associate Professor, Department of Radiology, Malla Reddy Medical College for Women's, Hyderabad.**ABSTRACT****BACKGROUND**

Patients with obstructive jaundice constitute significant proportion of patients presenting with jaundice at our hospital. In present study it is proposed to investigate primarily the diagnostic accuracy of MRCP and ERCP in defining aetiology, level of obstruction in obstructive jaundice.

MATERIALS AND METHODS

A prospective study conducted on 25 adult patients excluding paediatric population. A total of 17 male, 8 female subjects were evaluated in mean age group of 22 to 79 years. MRCP followed by ERCP was done in all patients.

RESULTS

The study group was defined into 3 groups: Stone – group I, Neoplastic – Group II, Non- Neoplastic Group-III. MRCP and ERCP had a success rate of 100% & 83% respectively to identify calculi in group-I, 100% & 73% respectively to identify neoplastic disease process in group-II 100% & 75% respectively for identifying non-neoplastic cause in group-III.

CONCLUSION

Diagnostic accuracy of MRCP and ERCP are comparable while MRCP scores over ERCP in failed ERCP cases. MRCP has 100% sensitivity and 100% specificity in stone disease and can be used as noninvasive alternative to ERCP. ERCP has more therapeutic value compared to MRCP.

KEYWORDS

Endoscopic Retrograde Cholangio-Pancreatography (ERCP), Magnetic Resonance Cholangio-Pancreatography (MRCP), Calculi, Stricture, Obstructive Jaundice.

HOW TO CITE THIS ARTICLE: Bheemashanker. MRCP and ERCP in diagnosis of obstructive jaundice. J. Evid. Based Med. Healthc. 2017; 4(70), 4170-4174. DOI: 10.18410/jebmh/2017/830

BACKGROUND

Jaundice refers to yellowish pigmentation of skin, sclera and mucosa due to raised plasma bilirubin (visible >35 mol/L). Obstructive jaundice is strictly defined as due to a block in the pathway between the site of conjugation of bile in the liver cells and entry of bile into the duodenum through the ampulla. The block may be intrahepatic (at biochemical cellular or canalicular level) or extra hepatic in bile ducts. Extra hepatic obstruction often termed as surgical jaundice can occur at intrahepatic, porta-hepatic, suprapancreatic, intrapancreatic periaampullary locations. Symptoms of obstructive jaundice include jaundice with or without pain, dark urine, pruritis, pale stools, weight loss, anorexia. Raised serum alkaline phosphatase level is often seen. The role of imaging is crucial for detection of site, extent and cause of obstruction. In case of malignant obstruction,

characterization and staging of tumour is crucial to decide optimal management. Non-invasive indirect biliary imaging include sonography, MR cholangiopancreatography (MRCP), Endoscopic ultrasound (EUS), helical CT cholangiography (hCTC). Direct invasive biliary imaging include ERCP and PTC. Ultrasound has capability to detect dilated biliary radicals with 87-99% accuracy,¹ making it an ideal technique for initial screening with accuracy of 14-41.6%³ to detect cause of obstruction. CT/ hCTC is superior to ultrasound for detecting cause of obstruction. Endoscopic retrograde cholangiopancreatography (ERCP) considered gold standard for biliary evaluation however is invasive and has technical failure rate of 5-15% with a small but significant (0.6-3%) risk of procedure induced pancreatitis, cholangitis, haemorrhage, perforation, bile leak.² Contraindications due to contrast medium reaction, difficult anatomy and post-operative status as well as difficulty in evaluating small children are other factors which limit the applications of this technique. In addition, it is difficult to assess the biliary anatomy proximal to a tight stricture with ERCP and distal to it on PTC. PTC has risk of sepsis, bile leak, bleeding. MR cholangiopancreatography (MRCP) has emerged as accurate and non-invasive alternative to diagnostic ERCP for evaluation of biliary tract with a diagnostic accuracy comparable to ERCP in evaluation of both malignant and benign biliary diseases. Advantages of MRCP are no use of contrast, radiation, noninvasiveness, complication free,

Financial or Other, Competing Interest: None.

Submission 10-07-2017, Peer Review 01-08-2017,

Acceptance 15-08-2017, Published 29-08-2017.

Corresponding Author:

Dr. Bheemashanker,

Gurupadappa Nagmarpalli,

Multi Super Speciality Co-Operative

Hospital and Research Center Ltd, Bidar,

Akka Mahadevi Colony, Near Axis Bank, Haroogeri,

B.V.B. College Road, Bidar- 585403. (K. S)

E-mail: bheemaprabha@yahoo.com

DOI: 10.18410/jebmh/2017/830



short examination time, multiplanar imaging and usefulness in poor ERCP candidates. Disadvantages include poor availability, cost, difficulty with claustrophobic subjects and aneurysmal clips.

Aims and Objectives

To evaluate clinical utility of Magnetic Resonance Cholangiopancreatography (MRCP) and Endoscopic Retrograde Cholangiopancreatography (ERCP) in defining the aetiology, level of obstruction in obstructive jaundice patients.

MATERIALS AND METHODS:

A Prospective study was conducted on 25 adult patients who presented to our institution over a period of 18 months with symptoms and signs of biliary obstruction and evidence of obstruction detected on routine Ultrasound/CT scan examination. Paediatric population, medical jaundice, cirrhosis was excluded from the study. Informed consent was obtained from all patients. All patients underwent a detailed clinical history, examination and routine laboratory tests like haemogram and liver function test. All patients had initial USG examination of abdomen using ESOATE MY LAB. MRCP followed by ERCP examination was done subsequently. MRCP was performed on 1.5 T MR System (SIEMENS AVANTO) with breath holding & respiratory triggering. Localizers, HASTE Axial & Coronal, TRUFI Axials & Coronals, 3D MIP Coronal reconstructions were performed. ERCP with an aim to decompress the biliary system was done by an experienced gastroenterologist within a period of 24-48 hrs of MRI examination. Patients with suspected cholangitis were given antibiotic prophylaxis 1 hr before and 5 days after procedure. MRCP and ERCP images were assessed by two different radiologists who were aware of main clinical indication for performing MRCP and ERCP examination but did not know the results of other diagnostic studies. Both source images and MIP reconstructed images were evaluated for intrahepatic and the extrahepatic ductal system. The intrahepatic biliary system was evaluated for visualization of ducts in major hepatic quadrants. The extrahepatic ducts were evaluated for visualization, dilatation of hepatic ducts (right, left), hepatic duct confluence, CHD, CBD (proximal, middle, distal). Dilatation criteria IHBR >2 mm, CHD>6 mm, CBD>5-7 mm, CBD post cholecystectomy state> 10 mm Stones were diagnosed with MRCP when round, oval, or multi faced areas of signal void with or without a crescent sign were seen within the bile duct. Their number and location were noted. Stricture was diagnosed when there was a focal area of narrowing of biliary tree with or without proximal dilatation. Stricture was graded as short segment (length less than 1 cm) or as long segment (length > 1 cm). These were further graded according to Bismuth classification. A malignant obstruction was considered when there was abrupt cut off with irregularity of distal narrow segment, proximal dilated biliary tree and filling defect with irregular margins. Benign strictures have short smooth margins.

RESULTS

Out of 25 patients evaluated, 17 (68%) were male, 8 (32%) were female. Age of study group ranged from 22-79 years of age. Most affected age group was 50-60 years mainly males and least affected was above 70 years of age. Clinical examination revealed wide range of signs and symptoms separately or in combinations. Jaundice (100%) & pruritis (92%) was most common complaint whereas fever (40%) was least common complaint. In these 25 patients, the total serum bilirubin ranged between 2.4 –32.2 mg% with a mean of 20 mg%, Serum alkaline phosphatase ranged between 380-1240 IU/L with a mean of 560 IU/L and SGOT /SGPT level ranged between 20/15 IU to 70/35 IU with a mean of 35 /19.1 IU. Most common cause of obstruction was choledocholithiasis (24%) followed by cholangiocarcinoma (20%), Hepatocellular carcinoma, Carcinoma gall bladder, primary sclerosing cholangitis, Hydatid cyst, periampullary mass were least common (4%). Patients were categorized into 3 groups-I-stone, II-neoplastic, III-nonneoplastic groups. Neoplasia was predominant (44%), followed by nonneoplastic (32%) & stone disease (24%) respectively. Alternatively patients were classified into various aetiologic entities-congenital, inflammatory, neoplastic, postoperative, traumatic. Predominance of inflammatory cause was followed by neoplastic cause. Cholangiocarcinoma (20%) was most common cause of malignant obstructive jaundice and choledocholithiasis (24%) was commonest benign cause. A single case of post-operative stricture in a patient of carcinoma stomach was seen.

Cause of Obstruction	MRCP		ERCP	
	Number of cases (n)	Success rate (%)	Number of cases (n)	Success rate (%)
Calculous Obstruction	6	100	5	83
Neoplastic obstruction	11	100	8	73
Non-neoplastic obstruction	8	100	6	75

Table 1. Comparison of MRCP and ERCP Success Rate

ERCP failed in one case of stone disease due to difficult cannulation of CBD. ERCP could not be done in three cases of neoplastic obstruction due to active haemorrhage when common bile duct was cannulated. ERCP could not be done in two cases of nonneoplastic obstruction due to difficult cannulation of terminal CBD.

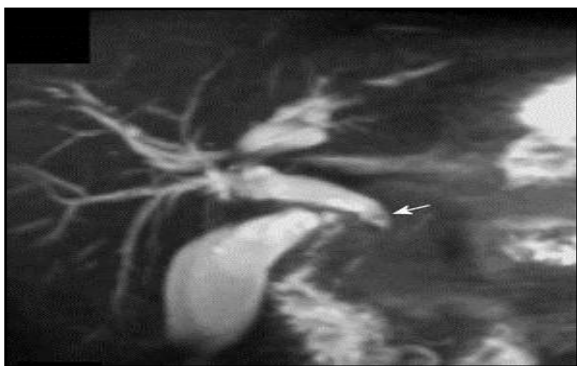

Figure 1. Coronal MIP Filling Defect (Calculus) in the Common Bile Duct (Arrow)

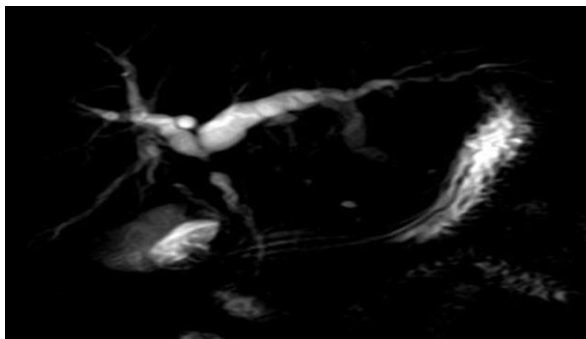


Figure 2. CBD Stricture

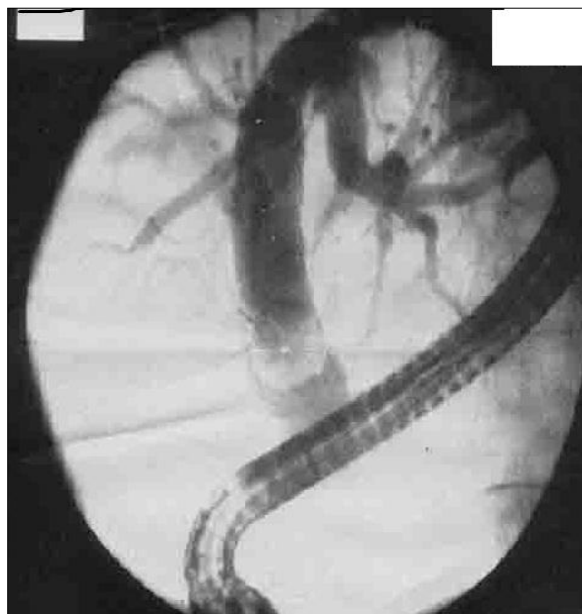

Figure 3. ERCP Showing Calculus in Dilated CBD

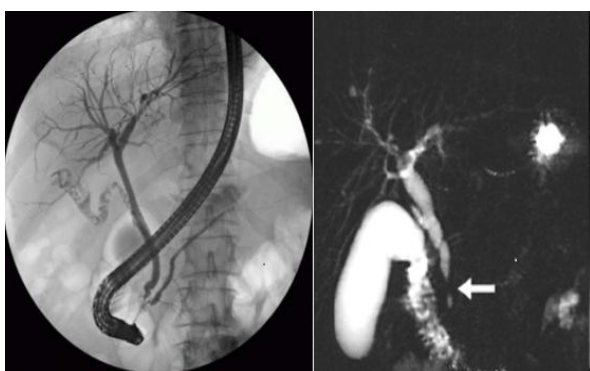


Figure 4. Normal ERCP and MRCP of same patient shows malignant stricture

DISCUSSION

While evaluating a patient with obstructive jaundice, the main aim of radiological investigations is to confirm the presence of bile duct obstruction and to accurately define its site and cause. In cases of malignant obstruction, delineation of extent of disease and assessment of tumor resectability are important to plan the appropriate treatment. While ultrasound is an excellent modality to confirm or exclude presence of biliary obstruction, its ability to determine the site and the cause of obstruction is not good because of obscuration of CBD by overlying colonic gases and due to inability to distinguish dilated obstructed system from dilated nonobstructed system which can result from recent passage of a stone or in post cholecystectomy status and old age. In the present study, US could predict the site of obstruction correctly in all 25 patients and also defined the cause in 60% (15/25) of the cases. Though CT has also been used to evaluate the patients of obstructive jaundice because of its higher accuracy compared to US, direct cholangiography (ERCP/PTC) is often required before planning a definitive therapy. Since its development in the 1970s, endoscopic retrograde cholangiopancreatography (ERCP) has occupied a unique position as a diagnostic modality for the diagnosis and management of obstructive jaundice. Anatomical abnormalities such as papillary stenosis, pancreatic divisum, duodenal diverticulum, biliary stricture, Billroth II or Roux en Y anastomosis, duodenal stricture and annular pancreas, all can contribute to the technical failure.¹ ERCP has high accuracy to diagnose the presence, site and cause of obstruction. Stake et al³ evaluated 101 patients of obstructive jaundice with ERCP. ERCP could correctly rule out obstruction in 10 and confirm obstruction in 91 cases (100%) but cause could only be correctly diagnosed in 79 out of 101 cases. This was attributed to incomplete filling of intrahepatic ducts with ERCP. Authors suggested that in cases of complete obstruction both ERCP and PTC are complementary and can better define cause of obstruction. In the present study, ERCP was successful in 19/25 patients and was unsuccessful in six patients due to failure of cannulation of papilla with active bleeding. Lee et al⁴ showed 71% sensitivity, 92% specificity and 88% accuracy of ERCP in differentiating benign versus malignant obstruction. The potential pitfall of ERCP lies in the fact that infiltrative malignancies not associated with significant mass effect may result in smooth appearance of the strictured segment which may stimulate benign lesion. In our series ERCP related complications were seen in 3/25 patients who underwent ERCP examination where 2 patients of cholangiocarcinoma/Klatskin tumor suffered from severe haemorrhage and another patient of chronic pancreatitis developed severe cholangitis. A good delineation of biliary tree could not be achieved in few patients in our series due to degree of biliary obstruction and avoiding injection of more contrast to prevent cholangitis. Hence this could explain slightly poor diagnostic accuracy of ERCP in our study. In view of the potential pitfalls and complications of ERCP, there has been a constant search for evolving a non-invasive technique which could obviate the need for ERCP and PTC. MRCP with newer techniques like HASTE, TRUFI allow high resolution images, short imaging time, low respiratory artefacts. Diagnostic accuracy of MRCP

with respect to the determination of presence of obstruction varies from 94 to 100%.⁵

Our results revealed that MRCP was excellent for confirming the presence, level and aetiology of biliary obstruction in all 25 (100%) patients. Not only MRCP was 100% accurate in demonstrating the presence of obstruction, it was also superior in visualizing the dilated IHBRs and the hepatic ducts proximal to the obstruction in all 25 patients. Similar observations have been reportedly by Yeh et al⁶ where they could diagnose the ductal dilatation in 100% of the cases and showed biliary tree cephalad to stenotic site in all cases. Choledocholithiasis as a cause of obstruction was seen in 24% patients and was the most common cause of obstruction in our series. (Figure 1) For MRCP to be accepted as an alternative to diagnostic ERCP, however, its sensitivity and specificity in the setting of suspected choledocholithiasis must at least equal those of ERCP. The determination of sensitivity and specificity of ERCP in the diagnosis of choledocholithiasis is difficult because the ERCP is considered the standard of reference for common bile duct stone detection. In an analysis of 72 patients studied with intraoperative cholangiography and ERCP, Frey et al⁷ found a sensitivity of 90% and a specificity of 98% for ERCP in the setting of choledocholithiasis. Recent studies focusing the role of MRCP in the detection of common bile duct stones yielded sensitivity of 90-100% and specificity of 92-100%, matching and, in most cases, exceeding those of ERCP. Positive predictive value range from 96-100%.⁸ Equally important as the sensitivity, specificity, and positive predictive value of MRCP is its negative predictive value, which ranges from 96-100%. Therefore, if an MRCP is interpreted as negative for common duct stones then one can avoid the performance of a diagnostic ERCP in most cases. In our series MRCP had 100% sensitivity & 100% specificity to detect presence of stone disease. ERCP failed in one case due to difficult cannulation. Sensitivity of MRCP decreases as size of stone decreases 67-100% for stone > 10 mm, 89-94% for stone 6-10 mm, 33-71% for stone 6 mm. MRCP was more effective to locate small calculi with sensitivity of 100% and superior to ERCP to localize multiple calculi in our study. Air bubbles can mimic calculi on ERCP leading to overestimation. Papillary tip/distal CBD calculi missed on USG can be effectively located on MRCP/ERCP equally. In proximal CBD/CHD calculi sensitivity & specificity of MRCP, ERCP are almost same. Both MRCP, ERCP cannot detect composition of calculi. Cholangiocarcinoma as second common cause of obstruction was seen in 20% patients in our series. In present study MRCP could correctly diagnose all 5 patients of cholangiocarcinoma (100% accuracy), whereas ERCP could not be done in one patient of cholangiocarcinoma due to active bleeding. MRCP was useful in delineating extent of tumor, identify isolated lobar hepatic ducts useful for planning surgical intervention. Klatskin tumour as cause of obstruction was seen in 3 (12%) patients. In contrast to ERCP, MRCP is particularly advantageous because it depicts the ducts located proximal and distal to a high grade obstruction and identifying multisegmental obstruction of intrahepatic ducts that are not opacified at ERCP. The identification of isolated obstructions is helpful in providing a road map for planning percutaneous interventions. In our series MRCP showed equivalent results with ERCP in two

cases. However in one case ERCP could not be performed due to active haemorrhage during cannulation. also reported higher sensitivity, specificity and diagnostic accuracy of MRCP in diagnosing Klatskin tumor. In their study 85% patients with Klatskin tumour could be correctly diagnosed by MRCP, compared to 71% by ERCP. MRCP missed diagnosis in few patients due to presence of concomitant hepatolithiasis located cephalad to the hilar Cholangiocarcinoma. Pancreatitis was seen in 12% patients with jaundice in our study group. Two patients with chronic pancreatitis had pancreatico-biliary junction stricture with dilated CBD. One patient with acute focal pancreatitis at head region developed smooth distal CBD benign stricture. (Figure 2) MRCP is accurate in detecting ductal dilatation, strictures, stones, pseudocysts, thoracopancreatic fistulas.⁹ In addition to depicting morphologic changes of chronic pancreatitis, recent studies reveal the utility of MRCP in assessing functional abnormalities of exocrine pancreas.¹⁰ In one study by Takehara agreement by two different readers between MRCP and ERCP was 83 % to 92% in cases of ductal dilatation, 70% to 92% in case of ductal narrowing, and 92% to 100% in case of filling defects. In our study 12% patients were diagnosed has benign stricture. MRCP showed same results as ERCP in one patient. In one patient MRCP diagnosed as left hepatic duct stricture, ERCP overestimated the length of length of stricture with extension into common hepatic duct due to insufficient entry of contrast. In another case MRCP diagnosed as terminal CBD stricture, but ERCP failed because of difficult cannulation. MRCP is less sensitive in differentiating benign from malignant stricture since finer imaging details like mural irregularity, ductal asymmetry, abrupt / gradual tapering, double duct sign used as criteria are not always reliable. We also demonstrated a benign hilar stricture in a late post-operative case of carcinoma stomach. In our series one patient was diagnosed as having primary sclerosing cholangitis (PSC) by MRCP. ERCP was performed two times (first there was a failure to cannulate CBD due to tight stricture, second there was an incomplete study due to insufficiency of contrast entering the biliary tree due to multiple strictures). MRCP is able to depict the subtle ductal abnormalities that characterize PSC which include mural irregularities, strictures and diverticular outpouching. In preliminary study of 34 PSC patients and 68 age matched controls with hepatobiliary diseases other than PSC, MRCP was shown to have a sensitivity of 88%, a specificity of 97%, a positive predictive value of 94% and negative predictive value of 94% in the diagnosis of PSC. This same study, however, noted that ERCP may be required to establish the diagnosis of PSC early in the course of the disease when ductal abnormalities are minimal and late in the course of the disease when the ducts are distorted by cirrhosis. In addition, ERCP is the study of choice if there is a need for therapeutic intervention such as stent placement or stricture dilation. Conventional MR performed in association with MRCP provides useful information regarding the presence of cirrhosis and portal hypertension in PSC patients. This represents an advantage when compared with ERCP. Jaundice is present in 19-40% of hepatocellular carcinoma (HCC) at the time of diagnosis. Obstructive jaundice in HCC can result due to ductal obstruction by tumour thrombi, haemobilia, tumour compression or tumour infiltration. We encountered 1 patient of HCC who presented with

obstructive jaundice. MRCP could exactly define the tumour extension into the confluence in this case, whereas ERCP failed to define the exact extension due to non-filling of the ductal system beyond obstruction. Carcinoma gallbladder usually manifests as a intraluminal polypoidal mass, or bulky exophytic mass infiltrating the adjacent liver parenchyma. On ERCP the gall bladder per se is usually not opacified because of the concomitant obstruction of the cystic duct due to tumour infiltration and mimics Klatskin tumour on ERCP images. But, MRCP when combined with cross sectional MR imaging, can demonstrate filling defect within gall bladder due to the presence of growth as well as its perihilar extension if any simultaneously. In one patient MRCP revealed GB fossa mass infiltrating into hilum causing narrowing of right hepatic duct, right branch of portal vein with intrahepatic biliary dilatation but ERCP could not be done due to active bleeding. In one case of periampullary adenoma MRCP showed equivalent results to ERCP, but biopsy was required to confirm diagnosis. Ampullary lesions may be missed on MRCP due to bowel gas obscuration and terminal CBD may be difficult to cannulate on ERCP due to extrinsic compression. In one case of hepatic hydatid cyst MRCP showed site of cyst rupture with few dilated biliary radicles adjacent to cyst suggesting biliary communication.

CONCLUSION

MRCP provides a noninvasive means to detecting common bile duct stones. If MRCP is interpreted as negative for common bile duct stones, diagnostic ERCP can be avoided in most cases. MRCP replaces ERCP in diagnosing neoplastic diseases as it provides extent and stage of the disease – an important factor in determining resectability especially when it is combined by Triphasic CECT Abdomen. Diagnostic yield of MRCP scores over incomplete/failed ERCP. ERCP has more of a therapeutic than diagnostic value.

REFERENCES

- [1] Cotton PB, Chong WK. Complications of endoscopic retrograde cholangiography and therapy. In: Silvis SE, Rohrmann CA, Ansel HY, ed. *Endoscopic retrograde cholangiopancreatography*. New York: Igaku-Shoin 1995:446-450.
- [2] Masci E, Toti G, Mariani A, et al. Complications of diagnostic and therapeutic ERCP: a prospective multi-centre study. *Am J Gastroentrol* 2001;96(2):417-442.
- [3] Satake K, Cho K, Tatsumi S, et al. Evaluation of cholangiographic procedures in diagnosis of obstructive jaundice. *Am Surg* 1981;47(9):387-392.
- [4] Lee MG, Jeong YK, Kim MW, et al. MR cholangiopancreatography of the pancreaticobiliary diseases: comparison of single-shot RARE and multi slice HASTE sequences. *AJR* 1998;171(6):1539-1545.
- [5] Alcaraz MJ, De la Morena EJ, Polo A, et al. A comparative study of magnetic resonance cholangiography and direct cholangiography. *Rev Exp Enferm Dig* 2000;92(7):423-442.
- [6] Yeh TS, Jan YY, Tseng JH, et al. Malignant perihilar biliary obstruction: magnetic resonance cholangiographic findings. *Am J of Gastroenterology* 2000;95(2):432-440.
- [7] Frey CF, Burbige EJ, Meinke WB, et al. Endoscopic retrograde cholangiopancreatography. *AM J Surg* 1982;144:109-114.
- [8] Soto JA, Barish MA, Yucel EK, et al. MR cholangiography comparison with ERCP. *Gastroenterology* 1996;110(2):589-597.
- [9] Fulcher AS, Capps GW, Turner MA. Thoracopancreatic fistula: clinical and imaging findings. *J Comput Assist Tomogr* 1999;23(2):181-187.
- [10] Cappeliez O, Delhay M, Deviere J, et al. Chronic pancreatitis: evaluation of pancreatic exocrine function with MR pancreatography after secretin stimulation. *Radiology* 2000;215(2):358-364.