

## OCULAR MANIFESTATIONS IN DIABETES-RELATED CHRONIC RENAL FAILURE PATIENTS IN A TERTIARY CARE CENTRE

Geoffrey Joju<sup>1</sup>, Anthrayose Kakkanatt C. V<sup>2</sup>, Monsy Mathai<sup>3</sup>, Sapna Mohan<sup>4</sup>

<sup>1</sup>Junior Resident, Department of Ophthalmology, Jubilee Mission Medical College and Research Institute, Thrissur, Kerala.

<sup>2</sup>Professor and HOD, Department of Ophthalmology, Jubilee Mission Medical College and Research Institute, Thrissur, Kerala.

<sup>3</sup>Professor, Department of Ophthalmology, Jubilee Mission Medical College and Research Institute, Thrissur, Kerala.

<sup>4</sup>Junior Resident, Department of Ophthalmology, Jubilee Mission Medical College and Research Institute, Thrissur, Kerala.

### ABSTRACT

#### BACKGROUND

A descriptive, observational and non-interventional hospital-based study on diabetes-related chronic renal failure patients undergoing regular haemodialysis was conducted to evaluate the occurrences of ocular manifestations and to know whether ocular screening was useful.

#### MATERIALS AND METHODS

A cross-sectional study was conducted. Hundred patients who were diabetic and undergoing treatment for chronic renal failure were taken. Detailed history was collected and clinical examination was done. All ocular findings were noted. Vision was noted with Snellen's chart. Anterior segment was assessed with slit lamp. Intraocular Pressure (IOP) measured using applanation tonometer. Retinal pathologies were noted with 90 D lens under slit lamp and indirect ophthalmoscopy and ultrasound scan were used in mature cataract cases.

#### RESULTS

Diabetic Retinopathy (DR) was noted in 95% cases, and of this, 64% of diabetic retinopathy were detected for the first time and were advised to undergo treatment. Lid oedema (58%), dry eye (48%) and corneal conjunctival calcification (12%) were also detected. More severe grades of DR were detected with increasing severity of renal disease. Seventeen percent patients showed Age-Related Macular Degeneration (ARMD) changes.

#### CONCLUSION

Chronic Renal Failure (CRF) patients are at increased risk of visual loss since this condition causes worsening of diabetic retinopathy changes. Regular ocular examinations are required in these patients for timely interventions to reduce risk of visual loss and thereby to improve patient's quality of life.

#### KEYWORDS

Ocular Manifestations, Diabetic Retinopathy, Chronic Renal Failure.

**HOW TO CITE THIS ARTICLE:** Joju G, Kakkanatt CVA, Mathai M, et al. Ocular manifestations in diabetes-related chronic renal failure patients in a tertiary care centre. *J. Evid. Based Med. Healthc.* 2017; 4(65), 3871-3874. DOI: 10.18410/jebmh/2017/773

#### BACKGROUND

Chronic Kidney Disease (CKD) affects every organ systems including the eye, which may ultimately cause vision loss. The kidney disease outcomes quality initiative and kidney disease improving global outcomes define chronic renal failure as the presence of kidney damage or glomerular filtration rate less than 60 mL/min./1.73 m<sup>2</sup> for a period greater than 3 months irrespective of aetiology.<sup>1</sup> Chronic kidney disease is a major worldwide public health issue. The

incidence of End-Stage Renal Disease (ESRD) is increasing worldwide at a rate of 8%, which far exceeds the global population growth rate of 1.3%.<sup>2</sup> Many patients are weighed down by their present diagnosis of end-stage renal disease and most of the resources are directed towards this condition to the exclusion of others. A patient may therefore do not notice or complain of visual symptoms until vision is irreversibly lost. Haemodialysis, one of the renal replacement therapies is frequently carried out in patients with chronic renal failure and end-stage renal disease. Many of these patients also have hypertension as well as diabetes mellitus. The most common cause of chronic renal failure is diabetic nephropathy followed by hypertensive nephroangiosclerosis and various glomerulonephropathies.<sup>3</sup> The ocular manifestations commonly seen in CKD patients are subconjunctival calcifications and cataract along with retinal findings including macular degeneration, Diabetic Retinopathy (DR) and calcification.<sup>4</sup> Retinal haemorrhages occur as a feature of DR and Age-Related Macular

*Financial or Other, Competing Interest: None.*

*Submission 21-07-2017, Peer Review 26-07-2017,*

*Acceptance 10-08-2017, Published 11-08-2017.*

*Corresponding Author:*

*Dr. Anthrayose Kakkanatt C. V,*

*Professor and HOD, Department of Ophthalmology,*

*Jubilee Mission Medical College and Research Institute,*

*Thrissur, Kerala-680005.*

*E-mail: geworld@gmail.com*

*DOI: 10.18410/jebmh/2017/773*



Degeneration (ARMD) and is exaggerated in uraemia due to bleeding tendencies.<sup>5</sup> Retinal vascular complications are common in these patients because diabetes, hypertension and other renovascular diseases are the main risk factors for this condition. Diabetes is the most common cause of CKD worldwide. This could be due to increase in urbanisation and standard of living. Since both kidney and retina share similar vascular features, microangiopathy produced by the diabetes affects both of them equally. Suggested risk factors include-

- Longer diabetes duration.
- Insulin therapy.
- Hypertension.
- Poor glycaemic control.
- Body mass index >30.

Diabetic nephropathy leading to CKD tends to worsen the retinopathy. There is increase in vascular permeability leading to oedema and the closure of the capillaries leading to ischaemia and later neovascularisation. There is increased chance of ARMD in renal failure patients and factors involved are increase in age, hypertension and smoking.<sup>6</sup> Corneal conjunctival calcification is another important complication commonly seen in CKD and dialysis. A possible reason for this could be a high calcium phosphate product and also loss of carbon dioxide at these sites along with rise in pH make an ideal situation for the precipitation. The pathophysiology of this situation is not clearly understood, whereas secondary hyperparathyroidism is considered as a reason behind this.<sup>3</sup> Cataract is another common finding in these patients. The relation between CKD and the cataractous change in lens remains unclear. But, there is a proposed mechanism of lens changes in which it suggests that the urea gets retained inside the lens resulting in water retention and then leads to osmotic cataract. Frequent movement of fluid inside and outside the lens during dialysis leads to cataractous lens change.<sup>7</sup> The various complications, which these patients face as a result of prolonged period of haemodialysis can be systemic (like hypotension, muscle cramps, haemolysis and febrile reactions) as well as ocular.

## MATERIALS AND METHODS

This was a cross-sectional, non-interventional, descriptive, hospital-based study conducted in the Department of Ophthalmology at Jubilee Mission Medical College and Research Institute, Thrissur, Kerala. Study period was 4 months from February 2016 to May 2016. A total of 100 cases of chronic renal failure with diabetes attending the nephrology unit for treatment including regular dialysis were selected. Cases of reversible renal failure, renal failures due to other causes like hypertension/vasculitis/snakebite and postrenal transplant cases were excluded from the study.

Regular laboratory investigations such as haemoglobin, total leucocyte count, differential leucocyte count, erythrocyte sedimentation rate, fasting blood sugar, HbA1c and serum electrolytes were carried out.

Detailed ophthalmological examinations were done. The evaluation included visual acuity with internally illuminated Snellen's chart, retinoscopy and subjective refraction to obtain best corrected visual acuity. The anterior and posterior segment was evaluated using Haag-Streit slit lamp. Retina was evaluated after pupil dilatation with tropicamide eye drop. The 90D aspheric lens with slit lamp was used to evaluate the retina and 20D lens was used to evaluate indirect ophthalmoscopy. Intraocular pressure was measured with applanation tonometry. Schirmer's test was performed. Ocular images were taken with the help of fundus photography.

## RESULTS

In this study, 62% were males and 38% were females. The patient's age ranges from 50 to 70 years with mean age of 60. In the present study, 64% reported visual acuity between 6/6 and 6/18, 18% patients have visual acuity between 6/18 and 6/60. Ten percentage patients have vision between 6/60-3/60 and only 8% patients have very low visual acuity of less than 3/60.

The commonest ocular finding in these patients were lid oedema (58%) followed by dry eye (48%) (Figure 1). The striking observation is that corneal conjunctival calcification was observed in 12% patients.

The important posterior segment findings in these patients were the prevalence of Diabetic Retinopathy (DR) changes in 95% of cases (Figure 2). Out of this 95% patients, 64% cases were not diagnosed previously and were diagnosed for the first time during our study. They were advised to undergo treatment. Fifty two percent patients were detected to have hypertensive retinopathy features. Age-Related Macular Degeneration (ARMD) changes were observed in 17% patients and optic neuropathy was seen in 18% of patients, which is a very significant value.

Grades of DR in these patients were analysed (Table 1). There were 38% patients with severe Nonproliferative Diabetic Retinopathy (NPDR) features, which were the highest and 7% with moderate NPDR, 27% with very severe NPDR, 16% patients had Proliferative Diabetic Retinopathy (PDR) and 7% patients had advanced diabetic eye disease. An important finding was that no patients had mild NPDR features. In the End-Stage Renal Disease (ESRD), 18% patients were having severe NPDR, 20% patients had very severe NPDR, 14% with PDR and 7% patients had Advanced Diabetic Eye Disease (ADED). Diabetic maculopathy were observed in 54% of cases.

As shown in Figure 3, the percentage of patients with DR increased progressively with the deterioration of the renal function. Fifty nine percent patients with DR were suffering from ESRD and only 3% patients with DR were from the mild Chronic Renal Failure (CRF) stage.

Fifteen percent of the patients showed secondary glaucoma. Out of these patients, 7% had neovascular type, 5% had uveitic type, 2% had pigmentary type and 1% had phacomorphic type of secondary glaucoma (Figure 4).

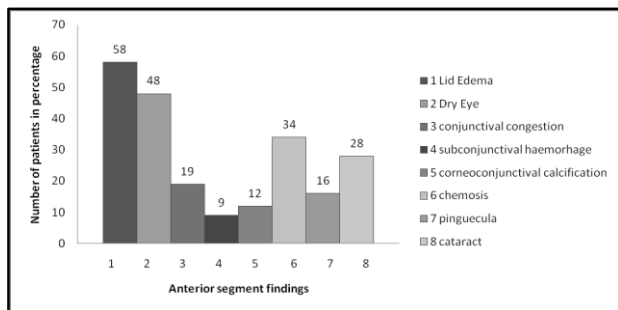


Figure 1. Anterior Segment Findings

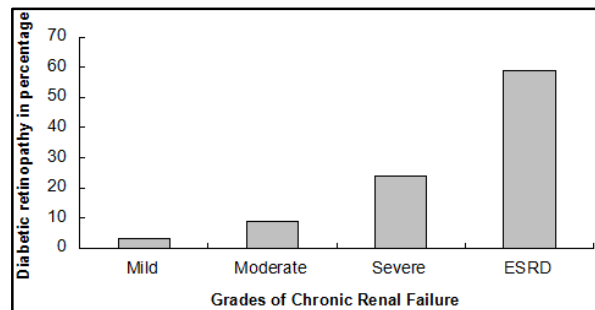


Figure 3. Comparison of Grades of CRF with DR

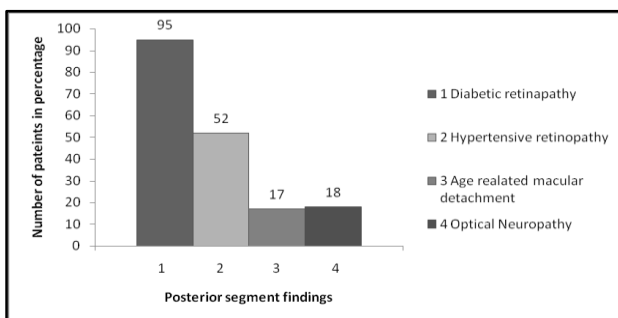


Figure 2. Posterior Segment Findings

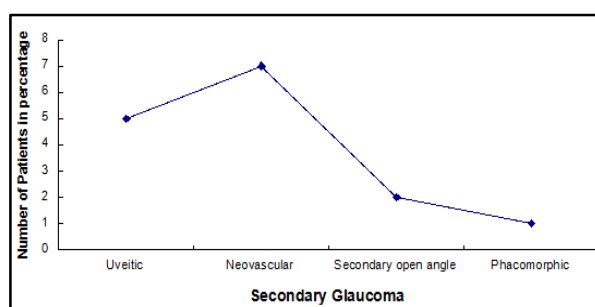


Figure 4. The Types of Glaucoma Detected

Grades of CRF	Mild NPDR	Moderate NPDR	Severe NPDR	Very Severe NPDR	PDR	ADED
Mild	-	3	-	-	-	-
Moderate	-	4	5	-	-	-
Severe	-	-	15	7	2	-
ESRD	-	-	18	20	14	7
<b>Total</b>	-	<b>7</b>	<b>38</b>	<b>27</b>	<b>16</b>	<b>7</b>

**Table 1. Comparison of Grades of DR Among Subgroups of CRF**

**DISCUSSION**

Diabetes mellitus contributes significantly to the burden of chronic kidney disease. The proportion of diabetic patients admitted to renal replacement programs has increased dramatically in recent years.<sup>8</sup> Microangiopathy of diabetes affects the kidney and the retina. Poor glycaemic control, longer diabetes duration, hypertension, insulin therapy and body mass index higher than 30 appear to be risk factors. Diabetic nephropathy tends to increase the progression of DR. It is characterised by increased vascular permeability leading to oedema and capillary closure resulting in ischaemia and neovascularisation.<sup>9</sup> In the present study, the mean age of the patients was 60 and male-to-female ratio of 1.6:1, whereas in a similar study on chronic renal failure (all stages) by Dahal P et al, the mean age of the patients was 45.2 years with male-to-female ratio of 2.5:1.<sup>10</sup> The corneal conjunctival calcification was observed in 12% patients, which may be due to the secondary hyperparathyroidism, which in turn maybe due to increased blood phosphate levels in these patients. Lid oedema was due to the fluid overload resulting from kidney dysfunction, whereas the dry eye was due to the increased amount of urea in the tears causing tear film instability. In a study conducted among CRF patients, DR was present in 38 out of 43 diabetic cases (88.3%), while in the present study, it was 95%. Fifty percent DR cases were detected for the first time in their study, which was 64% in the present study. This shows the importance of ocular evaluation of the patients

with renal insufficiency.<sup>11</sup> Moderate, severe and PDR (proliferate diabetic retinopathy) were seen in higher grades of CRF in the study conducted by Dahal P et al, which corresponds to our study results.<sup>10</sup>

In a study conducted among renal failure patients, it was found that 14% had corneal conjunctival calcification and 7% had ARMD,<sup>3</sup> whereas in our study, it was 12% and 17%, respectively. Optic neuropathy rates were high due to the hypotensive episodes occurring during the dialysis period. In a study conducted by Wang T J et al, it was found that patients with CRF had a significantly higher prevalence of retinal disorders, uveitis, glaucoma and cataract compared with patients without CRF, which corresponded to our findings.<sup>12</sup> Chang Y S et al showed a substantial increase in Non-Arteritic Ischaemic Optic Neuropathy (NAION) comparing with normal population (in our study, it was 18% with optic neuropathy). ESRD increased the risk of NAION, which is an interdisciplinary emergency. Close collaboration between nephrologists and ophthalmologists is important in NAION management following ESRD to prevent fellow eye involvement.<sup>13</sup>

The early treatment diabetic retinopathy study has classified DR into nonproliferative, proliferative retinopathy and diabetic maculopathy. This classification aims to predict degree of visual loss and timing for intervention to reduce progression and preserve vision.<sup>14</sup> Cataract was detected in 28% cases and its relation with CKD and haemodialysis is poorly defined in the previous studies. The possible causes

of increased cataract incidence in these patients was suggested was the urea getting trapped inside the lens and hence causing osmotic cataract and frequent movement of the fluid inside and outside of the lens during haemodialysis procedure causing chronic lens changes.<sup>15</sup>

### CONCLUSION

Chronic kidney disease is undoubtedly a global public health problem and diabetes is a leading cause for it. The management of chronic kidney disease requires collaboration between primary care physicians, the nephrologist and the ophthalmologist to ensure improved management, which would hopefully translate to improved quality of life of these patients. Early reference of these patients to the ophthalmologists is a must for early detection and necessary treatments, which may prevent them from vision loss.

### ACKNOWLEDGEMENT

We extend our sincere gratitude to faculty members of Jubilee Center for Medical Research for editing this article.

### REFERENCES

- [1] Levey AS, Atkins R, Coresh J, et al. Chronic kidney disease as a global public health problem: approaches and initiatives—a position statement from kidney disease improving global outcomes. *Kidney Int* 2007;72(3):247-259.
- [2] Schieppati A, Remuzzi G. Chronic renal diseases as a public health problem: epidemiology, social, and economic implications. *Kidney Int* 2005;(98):7-10.
- [3] Vrabec R, Vatavuk Z, Pavlovic D, et al. Ocular findings in patients with chronic renal failure undergoing haemodialysis. *Coll Antropol* 2005;29(1):95-98.
- [4] Huynh SC, Kifley A, Strippoli GF, et al. Is renal impairment a predictor of the incidence of cataract or cataract surgery? Findings from a population-based study. *Ophthalmology* 2005;112(2):293-300.
- [5] Wong TY, Mitchell P. Hypertensive retinopathy. *N Engl J Med* 2004;351(22):2310-2317.
- [6] Deva R, Alias MA, Colville D, et al. Vision-threatening retinal abnormalities in chronic kidney disease stages 3 to 5. *Clin J Am Soc Nephrol* 2011;6(8):1866-1871.
- [7] Wessing A. Diabetic retinopathy: update on diagnosis and treatment. *Nephrol Dial Transplant* 1997;12(9):2013-2018.
- [8] Klein R, Klein BE, Moss SE. Relation of glycemic control to diabetic microvascular complications in diabetes mellitus. *Ann Intern med* 1996;124(1 Part 2):90-96.
- [9] Jawa A, Kcomt J, Fonseca VA. Diabetic nephropathy and retinopathy. *Med Clin* 2004;88(4):1001-1036.
- [10] Dahal P, Gouli S. Ocular findings in the chronic renal failure. *Journal of College of Medical Sciences Nepal*. 2014;10(2):18-26.
- [11] Bajracharya L, Shah DN, Raut KB, et al. Ocular evaluation in patients with chronic renal failure—a hospital based study. *Nepal Med Coll J* 2008;10(4):209-214.
- [12] Wang TJ, Wu CK, Hu CC, et al. Increased risk of comorbid eye disease in patients with chronic renal failure: a population-based study. *Ophthalmic Epidemiology* 2012;19(3):137-143.
- [13] Chang YS, Weng SF, Chang C, et al. Risk of non-arteritic anterior ischemic optic neuropathy following end-stage renal disease. *Medicine* 2016;95(12):e3174.
- [14] Early treatment diabetic retinopathy study research group. Grading diabetic retinopathy from stereoscopic color fundus photographs—an extension of the modified airle house classification: ETDRS report number 10. *Ophthalmology* 1991;98(5):786-806.
- [15] Evans RD, Rosner M. Ocular abnormalities associated with advanced kidney disease and hemodialysis. *Semin Dial* 2005;18(3):252-257.