

# Reliability of Ultrasound in Patients with Chronic Liver Disease in the Diagnosis of Cirrhosis - A Systematic Review

Mishal Javaid\*, Syed Muhammad Yousaf Farooq, Syeda Khadija Tul Sughra, Muhammad Zubair, Mehreen Fatima, Abeer Gohar, Lina Khaled Fares Jallad

Department of Radiological Sciences and Medical Imaging Technology, The University of Lahore, Lahore, Pakistan.

## ABSTRACT

### BACKGROUND

Chronic liver disease is a major reason of morbidity and mortality. With a high prevalence of CLD, Ultrasonography can classify the appearances of cirrhosis and liver fibrosis etc.

### OBJECTIVE

The aim of this study was to assess the reliability of ultrasound in patients with chronic liver disease in the diagnosis of cirrhosis.

### METHODOLOGY

This systematic review and meta - analysis were carried out in agreement with the Preferred Reporting Items for Systematic Reviews and Meta -Analyses guidelines (PRISMA). We searched medicine and EMBASE research databases including Google scholar, PubMed, NCBI, Scopus, and Crossref databases from 2000 up to 2021. The keywords included were chronic liver disease, HCC and cirrhosis, hepatocellular carcinoma and ultrasound, liver cirrhosis, reliability of ultrasound in liver cirrhosis, cirrhotic liver, sonography of liver.

### RESULTS

Our primary literature screening identified 242 articles. The variables such as accuracy, sensitivity, and specificity, positive predictive value and negative predicative value in patients with chronic liver disease were included of 53 studies 27,751 patients were included, out of which 1615 are male patients and 1011 are female patients in 17 studies (08 studies did not mentioned male to female ratio). The main causes of chronic liver diseases were included. Out of 53 studies, 18 studies included the causes of CLD. Out of total of 2235 patients, 781 patients had hepatitis B virus, 497 patients had hepatitis C virus, and 957 patients had cirrhosis.

### CONCLUSION

With the several varieties of the causes, CLD is growing in incidence and cirrhosis is the most progressive phase of CLD. It is related with probable adverse event, such as the development of hepatocellular carcinoma which requires careful medical care. The ultrasonography parameters are helpful for providing predictive evidence and also for influential the best beneficial choices throughout follow - up of patients with CLD, mainly in patients with HBV or HCV in order to predict the incidence of HCC.

### KEYWORDS

Chronic liver disease, Liver cirrhosis, Reliability, Ultrasound

*\*Corresponding Author:*

*Mishal Javaid, Department of Department of Radiological Sciences and Medical Imaging Technology, The University of Lahore, Lahore, Pakistan.*

*E-mail: Manjaric.sdc@saveetha.com*

*How to Cite This Article:*

*Javaid M, Farooq SMY, Sughra SKT, et al. Reliability of Ultrasound in Patients with Chronic Liver Disease in the Diagnosis of Cirrhosis - A Systematic Review. J Evid Based Med Healthc 2022;9(10):31.*

*Received: 04-Apr-2022,*

*Manuscript No: JEBMH-22-54389;*

*Editor assigned: 06-Apr-2022,*

*PreQC No. JEBMH-22-54389 (PQ);*

*Reviewed: 20-Apr-2022,*

*QC No. JEBMH-22-54389;*

*Revised: 02-Jun-2022,*

*Manuscript No. JEBMH-22-54389 (R);*

*Published: 14-Jun-2022,*

*DOI: 10.18410/jebmh/2022/09.10.31.*

*Copyright © 2022 Javaid M, et al. This is an open access article distributed under Creative Commons Attribution License [Attribution 4.0 International (CC BY 4.0)]*

## INTRODUCTION

Chronic Liver Disease (CLD) is one of the reasons of death in the devolving world. Recently, the incidence of CLD has been increased and the mainstream of CLD in the developed world contain; alcoholic liver, viral hepatitis B and C, non - alcoholic hepatic steatosis, and hemochromatosis.<sup>1</sup> According to the NVSR in 2017 from the CDCP in USA, about 45,00,000 adults had CLD and liver cirrhosis, which is 1.8 % of the adult populace and approximately 41,673 deaths from CLD and cirrhosis. It is very common clinical condition, and it causes an advanced worsening of liver functions in 06 months. It is a constant progression of infection, obliteration, and redevelopment of liver parenchyma, which leads to fibrosis and cirrhosis. The variety of causes is comprehensive for CLD, which contains toxins, alcohol abuse for a persistent time, infection, autoimmune diseases, genetic and metabolic disorders. The problem of Hepatitis C Virus (HCV) associated with CLD in Pakistan has increased over the years and the current data demonstrations approximately 60.0 % to 70.0 % patients with chronic liver disease tend to be positive for anti - hepatitis C virus. It had revealed that approximately 50.0 % patients with hepatocellular carcinoma in Pakistan have positive HCV.<sup>2</sup> Cirrhosis is a last phase of CLD. The diagnosis of cirrhotic patients is determined by the incidence and development of Hepatocellular Carcinoma (HCC).<sup>3,4</sup> In Pakistan, there are no national accepted guidelines for screening high risk patients. The most mutual tendency is six months ultrasonography and serum alpha fetoprotein level.<sup>5</sup> Approximately 10.0 % patients are diagnosed with hepatocellular carcinoma on screening base in Pakistan and that possibly clarifies the delayed exhibition and poor diagnosis in majority of hepatocellular carcinoma patients.<sup>6</sup> The relationship between higher level of alpha fetoprotein and hepatocellular carcinoma diagnosis are variable because hepatocellular carcinoma may be present in 7.5 - 100 % patients with higher level of alpha fetoprotein.<sup>7</sup> In hepatology liver fibrosis is main clinical problem and it is a result of entirely CLD. Cirrhosis is the last phase of fibrosis and patients might have severe medical problems including PHT and HCC. An accurate established findings and presentation of liver fibrosis is achieved by histopathological investigation of biopsy. In mutual unsighted biopsy series, there are delayed by false negative identifies of cirrhosis due to sampling errors in an assessed average of 24.0 %. Furthermore, there is limitation of biopsy in clinical training because of the inappropriateness and risk problems. Since cirrhosis is frequently exposed by its problems and the possibility of variceal rupture is peak in the two years resulting the finding of cirrhosis, the primary finding of severe fibrosis and cirrhosis is necessary. It is a common disease, which is commonly undiagnosed, and the risks and limits of biopsy stop its use for screening of this situation. In the previous few years, another non - invasive procedure to assessment liver disease has been estimated, containing clinical signs, sonographic signs, or biochemical parameters in the blood. The sensitivity of ultrasonography for the finding of liver cirrhosis has been assessed to be 62.0 % for liver biopsy and 87.0 % for sonography with the characteristic sonographic signs of cirrhosis. Ultrasonography had a main role in the finding and organization of Chronic Liver Disease

(CLD) by providing analytical and predictive evidence as well as identifying difficulties such as Hepatocellular Carcinoma (HCC) and Portal Hyper Tension (PHT). Although conservative sonography is appreciated in the valuation of liver parenchyma and recognition of liver lesions, a variety of other sonography procedures had remained established that raises its prospective worth. Non - invasive procedures of dimensions in CLD are quickly changing in presentation proficiencies and accessibility. These embrace laboratory tests and imaging studies.<sup>8</sup>

## LITERATURE REVIEW

### Search Strategy

This systematic review and meta - analysis were carried out in agreement with the Preferred Reporting Items for Systematic Reviews and Meta - Analyses guidelines (PRISMA). We searched medicine and EMBASE research databases including: Google scholar, PubMed, NCBI, Scopus, and Crossref databases from 2000 up to 2021. The keywords included were; chronic liver disease, HCC and cirrhosis, hepatocellular carcinoma and ultrasound, liver cirrhosis, reliability of ultrasound in liver cirrhosis, cirrhotic liver, sonography of liver, sonography of CLD. To increase the affectability of the search the Google scholar was utilized with similar keywords, taking the newly available research studies in the sonography of hepatocellular carcinoma. Articles with original research work and peer - reviewed written in English were included in this review.

### Selection Criteria

After independently screening the abstract and titles relevant articles. Studies investigating both adults and children together were included. The minimum data set required was sample size, anatomical region of the body, role of radial - space sampling technique, imaging indication, imaging time, presence of motion artifact, image quality and pathology Detection. Data were extracted from the full journal article and studies were assessed for applicability and quality. Summary statistics were calculated from the raw data given in the study if they were not reported. Numbers were read from graphs if not reported in the text of the articles.

### Inclusion Criteria

- All the articles including authentic sources.
- Topics having relevant data
- HEC approved journals

### Exclusion Criteria

- Duplicated articles
- Articles having clues of already taken data
- Articles not fulfilling the available variables

### Data Collection and Analysis

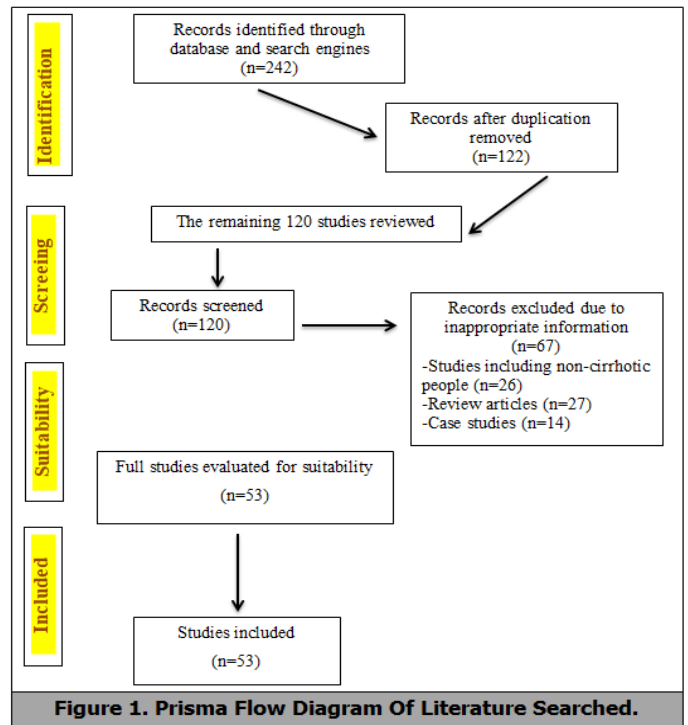
We self - sufficiently selected studies removed data and presented the results of sensitivity and specificity of ultrasound in chronic liver disease patients, using forest - plot and arranged the results. We obtained the accuracy estimates using 95 % Confidence Intervals (CIs). We double-checked all data extractions and analyses.

### Ethical Considerations

No ethical consideration is required for this type of study design.

**RESULTS**

Our primary literature screening identified 242 articles. 122 articles were removed because of duplication. 120 studies were screened for titles and abstracts. 67 studies were excluded for not including the appropriate information. 53 studies (2235 patients) were included for the extraction of data related to reliability of ultrasound in the diagnosis of cirrhosis. The whole process of searching is depicted in (Figures 1 - 4). Table 1 shows the qualitative variables (number of patients, mean age, type of research, and place of research) of 53 screened studies. Table 2 shows the data set of 25 studies including the variables as accuracy, sensitivity, specificity, positive predictive value and negative predicative value in patients with chronic liver disease. Of 53 studies 27,751 patients were included, out of which 1615 are male patients and 1011 are female patients in 17 studies (08 studies did not mentioned male to female ratio). Tables 2 and 3 shows the main causes of chronic liver diseases. Out of 53 studies, 18 studies included the causes of CLD. Out of total of 2235 patients, 781 patients had hepatitis B virus, 497 patients had hepatitis C virus, and 957 patients had cirrhosis (Table 4).



**Figure 1. Prisma Flow Diagram Of Literature Searched.**

References	Year	Country	Journal	Study design	Sample size	Male	Female
Shaista	2016	Pakistan	Pak Armed Forces Journal	Validation study	75	33	42
Nafees	2008	Pakistan	Pak Armed Forces Journal	Validation study	50	31	29
Wasim	2011	Pakistan	International Journal of General Medicine	Cross Sectional study	239	156	83
Schneider	2005	Germany	Liver International	Prospective study	119	66	53
Macias	2003	Spain	Europe PMC	Prospective study	113	NA	NA
Macias	2011	Spain	Europe PMC	Cross Sectional study	113	76	37
Moon	2013	Korea	Europe PMC	Prospective study	230	187	43
Shen	2006	China	World Journal of Gastroenterology	NA	324	272	52
Agostino	2003	Italy	RSNA Radiology	Prospective study	300	234	66
Aube	2004	France	European Journal of Gastroenterology and Hepatology	Prospective study	106	NA	NA
Mathiesen	2001	Sweden	Digestive and Liver Disease	Prospective study	165	110	55
D'Onofrio	2005	Italy	European PMC	Prospective study	105	73	32
Hung	2003	Taiwan	Journal of Gastroenterology	NA	210	NA	NA
Chen	2008	China	European PMC	Retrospective study	428	NA	NA
Gaia	2009	Italy	Journal of Hepatology	Prospective study	61	41	20
Liu	2007	Taiwan	Clinical Gastroenterology and Hepatology	Consecutive study	565	NA	NA
Abbattista	2008	Italy	Abdominal Radiology	Prospective study	83	22	16
Nishiura	2014	Japan	British Journal of Radiology	Prospective study	103	60	43
Carli	2019	Brazil	European Journal of Gastroenterology and Hepatology	Retrospective study	323	59	264
Jafarov	2020	Turkey	European Journal of Gastroenterology and Hepatology	NA	139	82	57
Choong	2012	Singapore	Journal of Clinical Imaging Science	Retrospective study	156	NA	NA
Agostino	2021	Italy	Cochrane Library	Retrospective study	18,792	NA	NA
Sidrah	2020	Pakistan	Journal of Rawalpindi Medial Collage	Cross -sectional validation study	75	43	32
Petzold	2020	Germany	PLOCS ONE	Retrospective study	157	70	87
Hernaes	2011	USA	Hepatology	NA	4720	NA	NA

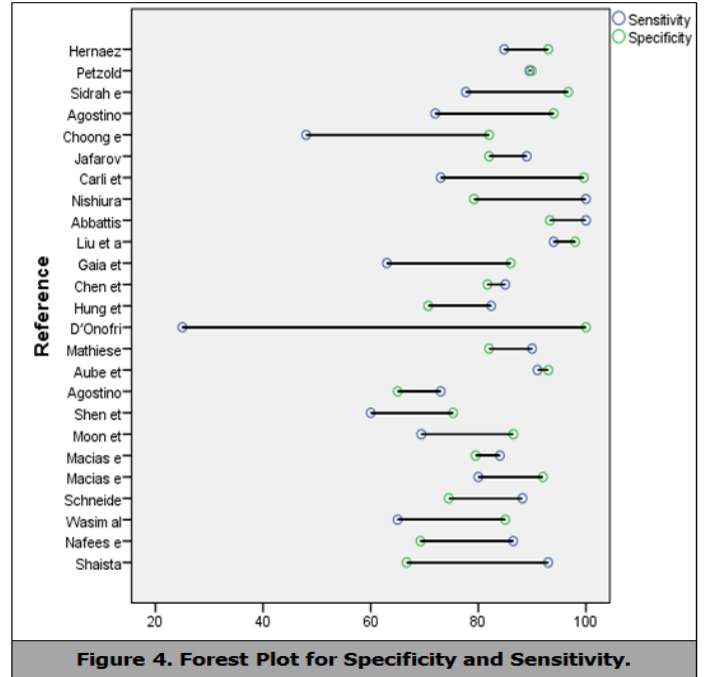
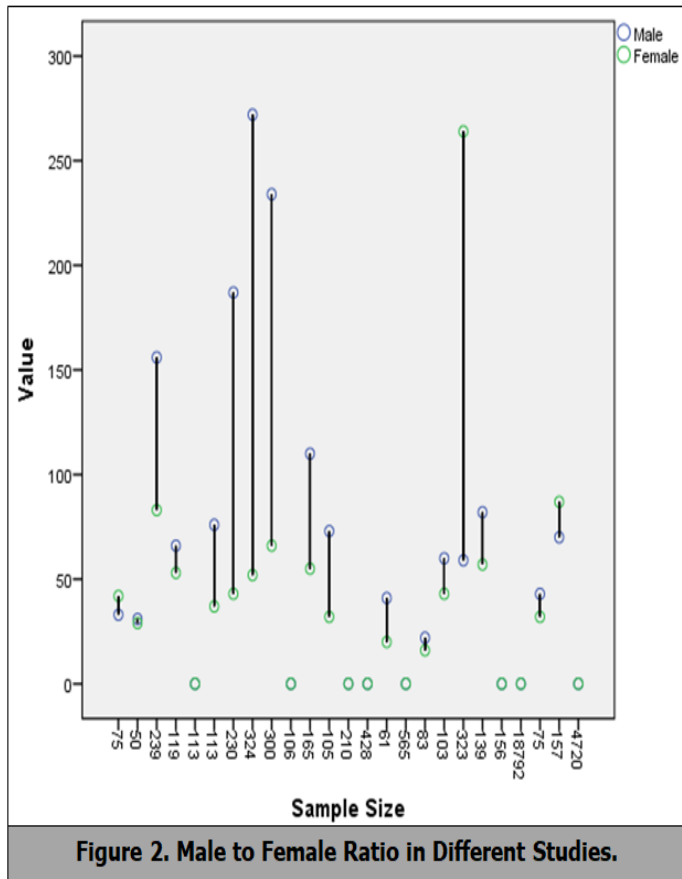
**Table 1. Article First Authors, Number of Patients, Research Type and Country of Origin.**

References	Sample size	Clinical findings	Anatomical region of scan	Acu of us %	Sens %	Spe %	Ppv %	Npv %
Shaista	75	NA	Abdomen	88.7	93	66.7	90	75
Nafees	50	CVH	Abdomen	82	86	69.2	89	64
Wasim	239	NA	Abdomen	70	65	85	92	45
Schneider	119	NA	Abdomen	90	88	74.5	100	96
Macias	113	NA	Abdomen	89	80	92	NA	NA
Macias	113	NA	Abdomen	86.7	84	79.5	NA	NA
Moon	230	NA	Abdomen	89.2	69	86.5	75	83
Shen	324	NA	Abdomen	73.7	60	75.3	20	95
Agostino	300	A.A	Abdomen	70	73	65	54	96
Aube	106	NA	Abdomen	92	91	93	82	93
Mathiesen	165	NA	Abdomen	84	90	82	87	87
D'Onofrio	105	NA	Abdomen	80	25	100	100	79
Hung	210	NA	Abdomen	74.8	82	70.7	61	88
Chen	428	NA	Abdomen	84.3	85	81.7	77	97
Gaia	61	NA	Abdomen	65	63	86	NA	NA
Liu	565	NA	Abdomen	94	94	98	98	76
Abbattista	83	NA	Abdomen	98	100	93.3	93	100
Nishiura	103	NA	Abdomen	95	100	79.2	95	NA
Carli	323	D.M, SAH	Abdomen	93	73	99.6	86	95
Jafarov	139	D.M, HPT	Abdomen	86	89	82	73	93
Choong	156	NA	Abdomen	66	48	82	28	89
Agostino	18,792	NA	Abdomen	80	72	94	NA	NA
Sidrah	75	NA	Abdomen	85.3	78	96.7	97	74
Petzold	157	D.M	Abdomen	92.3	90	89.9	55	98
Hernaes	4720	D.M	Abdomen	80	85	93	13	16

**Table 2. Parameters Justify the Reliability of Ultrasound in Patients with Chronic Liver Disease.**

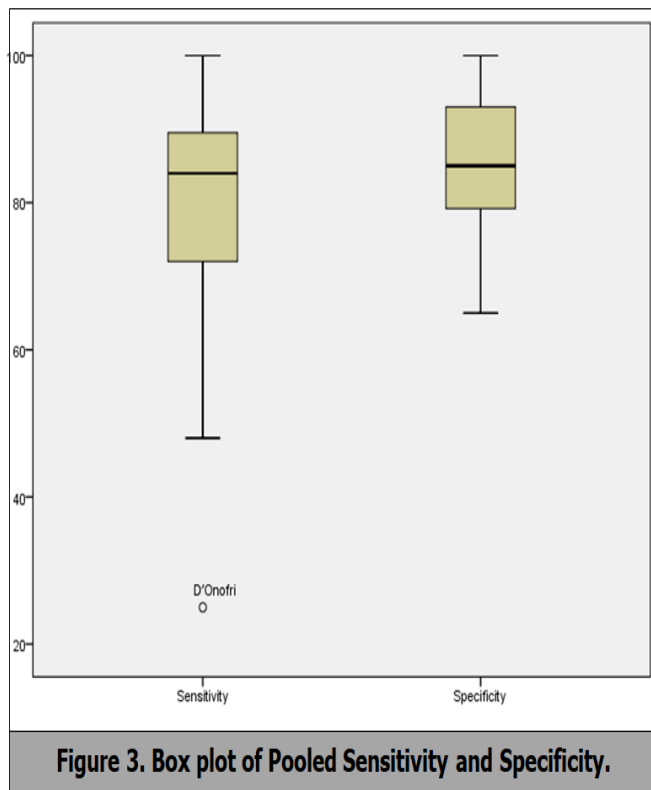
References	Hepatitis b virus	Hepatitis c virus	Liver cirrhosis	Hepatocellular carcinoma
Shaista	NA	NA	52	NA
Nafees	50	50	NA	NA
Wasim	NA	NA	51	62
Schneider	10	10	17	NA
Shen	306	18	324	NA
Agostino	21	122	73	NA
Aube	69	69	37	NA
Mathiesen	15	25	7	NA
Hung	67	143	78	NA
Nishiura	103	22	64	NA
Choong	136	20	23	NA
Petzold	4	18	231	NA

**Table 3. Ultrasonography Diagnosis in the Diagnosis of Cirrhosis.**



Descriptive Statistics					
	N	Minimum	Maximum	Mean	Std. Deviation
Sensitivity	25	25	100	78.5	16.987
Specificity	25	65	100	84.6	10.388

**Table 4. Combined Sensitivity and Specificity of All Studies.**



**DISCUSSION**

The purpose of our study was to assess the reliability of ultrasound in patients with chronic liver disease in the diagnosis of cirrhosis. The search was limited to the procedures that used sonographic image. Our study outcomes show that the sonographic features of chronic liver disease had high sensitivity in 24 out of 25 studies, only one study had low sensitivity 25.0 % 19 although the specificity was moderately high 100 %. We confirmed that observation with sonographic examination is highly accurate in CLD and hepatocellular carcinoma at any stage, with a mutual sensitivity of 80.0 % and pooled specificity of 84.5 % (Figure 2). Chronic liver diseases with viral disease patent variable grades of hepatic fibrosis ranging from no fibrosis to cirrhosis. Ultrasonographic investigation of the abdomen is require preferably every 6 to 12 months when cirrhosis had developed in patients with CLD to rule out the occurrence of HCC.<sup>9-33</sup> Usually B - mode and color Doppler sonography are safe, non - invasive, and low cost technique that is accessible in a wide variety of health care settings. To recognize the onset of cirrhosis in patients with CLD, sonography is routinely use in screening programmes. In accumulation, several studies confirm that B - mode and color Doppler sonography identifies of cirrhosis are related with high specificity.<sup>34</sup> these outcomes are reliable with our experience in this study. On the other hand, the finding of early HCC is of better significance for observation to be effective. While a systematic review had previously achieved on the effectiveness of ultrasonography in the finding of hepatocellular carcinoma, there are quite a few important variances from our review. First, we only included studies that



used ultrasonography as an investigation method in a potential manner, although previous studies evaluated ultrasound as a one - time diagnostic tool. This is a significant difference assumed that ultrasonography is most frequently used as an investigation tool in clinical practice. Second, our analysis precisely assessed the sensitivity of ultrasound for cirrhotic patients. Singal et al. studied the surveillance of ultrasonography in the diagnosis of HCC in patients with cirrhosis.<sup>35</sup> They also included those studies where sonography had observation procedure in a prospective manner. Chronic viral hepatitis is most common caused by the hepatitis B or C infection results in liver parenchyma injury and inflammation might be lead to fibrosis, cirrhosis or hepatocellular carcinoma. Cirrhosis often arises as an indolent disease and many patients are remaining asymptomatic until incidence of decompensation. The investigative accurateness of ultrasound in the finding of cirrhosis had examined in several studies. The specificity was high in 14 studies and sensitivity was in 11 studies, so the indicative accurateness varies from 65 - 100 % (Table 2). In specific, application of the purpose to identify principle is an important reason that reduced the diagnostic accuracy the non - invasive Evaluated of CLD had attempted by numerous research groups comprising either clinical signs, grayscale, or color Doppler sonographic signs. The use of color Doppler sonography in the finding and presentation of CLD built on the hypothesis that modification of liver hemodynamics due to chronic inflammatory changes may indirectly reflect the histological alterations. Hence, positive association studies had typically mentioned to velocity ratios of the hepatic artery to the portal vein. However, the role of color Doppler sonography remains controversial concerning the reproducibility and the numerical importance of the measurements in hepatic fibrosis and cirrhosis. Previous studies had evaluated numerous procedures for assessing the fibrosis stage of CLD by using different sonographic parameters. However, there are little studies regarding the accuracy in the diagnosing the signs of compensated liver cirrhosis by sonography. Hung suggested a complex sonographic scoring system *via* indices of the liver surface, parenchymal echotexture, vessel pattern, and spleen size etc. The role of sonography in the expecting cirrhosis had a subject of importance for decades, the most common sonographic features used for the recognition of liver is surface nodularity. Nishiura et al. found the sonographic assessment of the three Liver features that had reliable the predictors of the full spectrum of liver fibrosis. By developing a scoring system, they described that both advanced individual and total ultrasonography scores were intensely prognostic of a cumulative stage of fibrosis. Our search determines developed accuracies and exhibited increasing the sensitivity and accuracy of ultrasound in chronic liver diseases. The diagnostic presentations of previous studies in the diagnosing of severe fibrosis or cirrhosis were generally different, with sensitivities ranging from 25 - 100 %. Various investigators on the non - invasive observing of CLD report a variation of algorithms and scoring systems that could be valuable to progress the judgment of fibrosis, including combinations of biochemical, radiological, laparoscopic studies and some studies allow the documentation of patients with significant fibrosis.

### CONCLUSION

In our study, with the several varieties of the causes, CLD is growing in incidence universal and cirrhosis is the most progressive phase of CLD. It is related with probable adverse event, such as the development of hepatocellular carcinoma

which requires careful medical care. The ultrasonographic parameters are helpful for providing predictive evidence and also for influential the best beneficial choices throughout follow - up of patients with CLD, mainly in patients with HBV or HCV in order to predict the incidence of HCC.

### REFERENCES

1. Heidelbaugh JJ, Bruderly M. Cirrhosis and chronic liver failure part I. Diagnosis and evaluation. *Am Fam Physician* 2006;74(5):756-762.
2. Riaz S, Khokhar RA, Farooq A. Validity of Gray Scale Ultrasonography In Diagnosis Of Chronic Liver Disease Of Viral Etiology. *Pakistan Armed Forces Medical Journal* 2016;66(3):238-243.
3. Sayiner M, Golabi P, Younossi ZM. Disease burden of hepatocellular carcinoma a global perspective. *Dig Dis Sci* 2019;64(4):910-917.
4. Norsaadah B, Nurhazalini - Zayani CGC. Epidemiology and survival of hepatocellular carcinoma in north - east Peninsular Malaysia. *Asian Pac J Cancer Prev* 2013;14(11):6955-6959.
5. Phulpoto JA, Shah IA, Bhatti Z. Prevalence of hepatocellular carcinoma in cirrhotic patients of Northern Sindh attending liver clinics at Ghulam Mohammad Mahar Medical College Hospitals Sukkur and Khairpur. *J Liaquat Uni Med Health Sci* 2012;11(1):29-33.
6. Butt AS, Hamid S, Wadalawala AA, et al. Hepatocellular carcinoma in Native South Asian Pakistani population trends, clinico-pathological characteristics and differences in viral marker negative and viral-hepatocellular carcinoma. *BMC research notes* 2013;6(1):1-13.
7. Baig JA, Alam JM, Mahmood SR, et al. Hepatocellular carcinoma (HCC) and diagnostic significance of A - fetoprotein (AFP). *Journal of Ayub Medical College, Abbottabad JAMC* 2009;21(1):72-75.
8. Gerstenmaier J, Gibson R. Ultrasound in chronic liver disease. *Insights into imaging* 2014;5(4):441-55.
9. Nafees M, Abbas G, Saqib M. Validity of Ultrasound in Diagnosis of Liver Fibrosis Resulting from Chronic Viral Hepatitis. *Pakistan Armed Forces Medical Journal* 2011;61(4):585-589.
10. Memon WA, Haider Z, Beg MA, et al. Diagnosis of hepatoma using grayscale and Doppler ultrasound in patients with chronic liver disease. *Int J Gen Med* 2011;4:751.
11. Schneider A, Teuber G, Kriener S, et al. Noninvasive assessment of liver steatosis, fibrosis and inflammation in chronic hepatitis C virus infection. *Liver international* 2005;25(6):1150-1155.
12. Rodriguez M, JM IH. Ultrasonography in patients with chronic liver disease: its usefulness in the diagnosis of cirrhosis. *Revista espanola de enfermedades digestivas organo oficial de la Sociedad Espanola de Patologia Digestiva* 2003;95(4):258-264.
13. Maclas - Rodriguez MA, Rendon - Unceta P, Ramos - Clemente - Romero MT, et al. Prospective validation of two models for ultrasonographic diagnosis of cirrhosis. *Revista espanola de enfermedades digestivas: organo oficial de la Sociedad Espanola de Patologia Digestiva* 2011;103(5):232-237.
14. Moon KM, Kim G, Baik SK, et al. Ultrasonographic scoring system score versus liver stiffness measurement in prediction of cirrhosis. *Clin Mol Hepatol* 2013;19(4):389.
15. Shen L, Li J-Q, Zeng M-D, et al. Correlation between ultrasonographic and pathologic diagnosis of liver fibrosis due to chronic virus hepatitis. *World J Gastroenterol* 2006;12(8):1292.
16. Colli A, Fraquelli M, Andreoletti M, et al. Severe liver

fibrosis or cirrhosis: accuracy of US for detection analysis of 300 cases. *Radiology* 2003;227(1):89-94.

17. Aube C, Winkfield B, Oberti F, et al. New Doppler ultrasound signs improve the non-invasive diagnosis of cirrhosis or severe liver fibrosis. *Eur J Gastroenterol Hepatol* 2004;16(8):743-751.

18. Mathiesen U, Franzen L, Aselius H, et al. Increased liver echogenicity at ultrasound examination reflects degree of steatosis but not of fibrosis in asymptomatic patients with mild/moderate abnormalities of liver transaminases. *Dig Liver Dis* 2002;34(7):516-522.

19. Donofrio M, Martone E, Brunelli S, et al. Accuracy of ultrasound in the detection of liver fibrosis in chronic viral hepatitis. *La Radiologia Medica* 2005;110(4):341-348.

20. Hung C- H, Lu S-N, Wang J-H, et al. Correlation between ultrasonographic and pathologic diagnoses of hepatitis B and C virus-related cirrhosis. *J Gastroenterol* 2003;38(2):153-157.

21. Chen Y, Hou J, Dai L, et al. Ultrasonic scores combined with blood indexes for screening and predicting compensated liver cirrhosis in chronic hepatitis B patients. *Nan fang yi ke da xue xue bao J South Med Univer* 2008;28(12):2157-60.

22. Gaia S, Cocuzza C, Rolle E(2009) A comparative study between ultrasound evaluation, liver stiffness measurement and biopsy for staging of hepatic fibrosis in patients with chronic liver disease. *The International Liver Congress by EASL*.361.

23. Liu CH, Hsu SJ, Lin JW, et al. Noninvasive diagnosis of hepatic fibrosis in patients with chronic hepatitis C by splenic Doppler impedance index. *Clin Gastroenterol Hepatol* 2007;5(10):1199-206.

24. Abbattista T, Ridolfi F, Ciabattini E, et al. Diagnosis of liver cirrhosis by transit-time analysis at contrast-enhanced ultrasonography. *La radiologia medica* 2008;113(6):860-874.

25. Nishiura T, Watanabe H, Ito M, et al. Ultrasound evaluation of the fibrosis stage in chronic liver disease by the simultaneous use of low and high frequency probes. *Br J Radiol* 2005;78(927):189-197.

26. De Carli MA, de Carli LA, Correa MB, et al. Performance of

noninvasive scores for the diagnosis of advanced liver fibrosis in morbidly obese with nonalcoholic fatty liver disease. *Eur J Gastroenterol Hepatol* 2020;32(3):420-425.

27. Jafarov F, Kaya E, Bakir A, et al. The diagnostic utility of fibrosis-4 or nonalcoholic fatty liver disease fibrosis score combined with liver stiffness measurement by fibroscan in assessment of advanced liver fibrosis a biopsy - proven nonalcoholic fatty liver disease study. *Eur J Gastroenterol Hepatol* 2020;32(5):642-629.

28. Choong C- C, Venkatesh SK, Siew EP. Accuracy of routine clinical ultrasound for staging of liver fibrosis. *J Clin Imaging Sci* 2012;2.

29. Colli A, Nadarevic T, Miletic D, et al. Abdominal ultrasound and alpha - foetoprotein for the diagnosis of hepatocellular carcinoma in adults with chronic liver disease. *Cochrane Database of Systematic Reviews* 2021.

30. Nadeem S, Wasim S, Manzoor S, et al. Diagnostic Accuracy of Hepatic Vein Resistive Index in Detection of Hepatic Fibrosis in Patients of Chronic Liver Disease. *J Rawal Med Cig* 2020;24(3):278-282.

31. Petzold G, Lasser J, Ruhl J, et al. Diagnostic accuracy of B-Mode ultrasound and Hepatorenal Index for graduation of hepatic steatosis in patients with chronic liver disease. *PloS one* 2020;15(5):e0231044.

32. Hernaez R, Lazo M, Bonekamp S, et al. Diagnostic accuracy and reliability of ultrasonography for the detection of fatty liver: a meta - analysis. *Hepatology* 2011;54(3):1082-1090.

33. Wilson JF. Liver cancer on the rise. *Ann Intern Med* 2005;142:1029-1032.

34. Bernatik T, Strobel D, Hahn EG, et al. Doppler measurements: a surrogate marker of liver fibrosis? *Eur J Gastroenterol Hepatol* 2002;14(4):383-387.

35. Singal A, Volk M, Waljee A, et al. Meta - analysis surveillance with ultrasound for early - stage hepatocellular carcinoma in patients with cirrhosis. *Aliment Pharmacol Ther* 2009;30(1):37-47.