

# SPECTRAL DOMAIN OPTICAL COHERENCE TOMOGRAPHIC EVALUATION OF THE ASYMPTOMATIC EYE IN PATIENTS WITH UNILATERAL CENTRAL SEROUS CHORIORETINOPATHY

Pappa Padmavathi<sup>1</sup>, Sunil Maruthivila Sudhakaran<sup>2</sup>

<sup>1</sup>Assistant Professor, Department of Ophthalmology, Government Medical College, Thrissur, Kerala.

<sup>2</sup>Assistant Professor, Department of Ophthalmology, Government Medical College, Trivandrum, Kerala.

## ABSTRACT

### BACKGROUND

CSC is characterised by a serous detachment involving the fovea. CSC may make the patient hypermetropic. It is primarily a disease of the choroid as evidenced by the fact that the asymptomatic other eye of patients with CSC shows thick choroid. Symptomatic eye with CSC very often shows pigment epithelial detachments. Pigment epithelial detachments have also been noted in the asymptomatic other eye of patients with CSC.

### MATERIALS AND METHODS

Spectral Domain (SD), Optical Coherence Tomography (OCT) provides high resolution images of the retinal layers and improved visualisation of the choroid. This study was done to assess the SD-OCT changes in asymptomatic eye in patients with unilateral CSC.

### RESULTS

19 cases (53%) had SD-OCT changes in asymptomatic eye. Out of this, 13 (37%) cases had PED, 5 (13%) cases with subretinal fluid (13%) and 6 (16%) cases had retinal pigment epithelial changes.

### CONCLUSION

The presence of only PED in the asymptomatic eyes suggests that the pathologic process is evolving with asymmetric clinical presentation. So, it is reasonable to conclude that CSC is a bilateral disease with an asymmetric presentation.

### KEYWORDS

Spectral Domain (SD), Optical Coherence Tomography (OCT), Pigment Epithelial Detachment (PED).

**HOW TO CITE THIS ARTICLE:** Padmavathi P, Sudhakaran SM. Spectral domain optical coherence tomographic evaluation of the asymptomatic eye in patients with unilateral central serous chorioretinopathy. J. Evid. Based Med. Healthc. 2017; 4(10), 552-555. DOI: 10.18410/jebmh/2017/107

### BACKGROUND

Central Serous Chorioretinopathy (CSC) is a disease affecting usually young, anxious males with thick choroid.<sup>1-2</sup> CSC is characterised by a serous detachment involving the fovea. CSC may make the patient hypermetropic. Vision of the patient may range from normal to counting fingers. This disease is also seen in those taking systemic, topical and inhalational steroids. Moreover, those with high endogenous level of steroids like the state of pregnancy are also susceptible to the development of CSC. Sometimes, CSC maybe bilateral or even bullous mimicking exudative detachment. It is primarily a disease of the choroid as evidenced by the fact that the asymptomatic other eye of patients with CSC shows thick choroid. Symptomatic eye with CSC very often shows pigment epithelial detachments.

Pigment epithelial detachments have also been noted in the asymptomatic other eye of patients with CSC. Fluorescein angiography along with Indocyanine green angiography is routinely performed now to identify the site of leak. CSC shows classical angiographic patterns like smokestack or ink blot. If the leak is outside the foveal avascular zone, laser photocoagulation is an effective procedure. Laser is generally done if the disease does not settle spontaneously, the other eye of patients with CSC have findings like pigment epithelial detachments just like the one which are present in the affected eye suggesting that they are the early findings of the disease before the serous detachment develop. Spectral Domain (SD)-Optical Coherence Tomography (OCT) provides high-resolution images of the retinal layers and improved visualisation of the choroid.<sup>3-6</sup>

*Financial or Other, Competing Interest: None.*

*Submission 04-12-2016, Peer Review 11-12-2016,*

*Acceptance 24-12-2016, Published 02-02-2017.*

*Corresponding Author:*

*Dr. Pappa Padmavathi,*

*Vaishnavam, Whitefield,*

*Ayyanthol, Trichur-3.*

*E-mail: pappavinod@gmail.com*

*DOI: 10.18410/jebmh/2017/107*

### Aim and Objectives of the Study

This study was done to assess the SD-OCT changes in asymptomatic eye in patients with unilateral CSC. The study aimed to identify any predictive factor in SD-OCT for the development of CSC in asymptomatic eye of those with unilateral CSC.

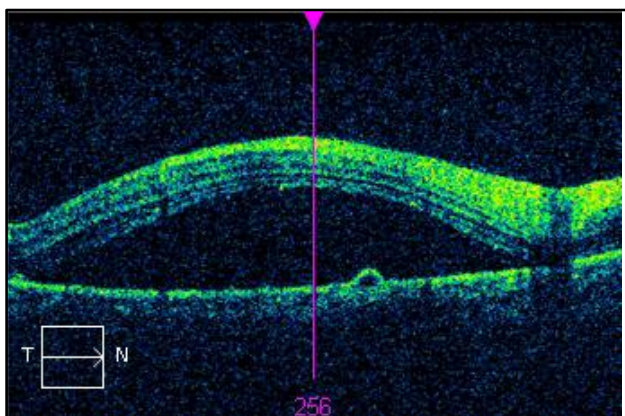


**MATERIALS AND METHODS**

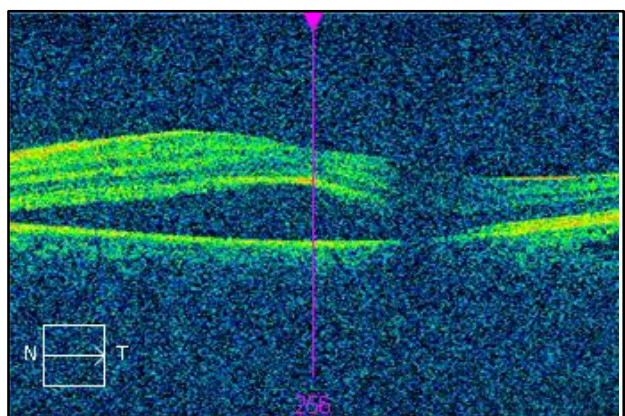
This clinical observational study was conducted in a tertiary eye care centre after obtaining the approval from the institutional review board. The research adhered to the tenets of the declaration of Helsinki. Inclusion criteria was those presented with CSC in one eye and asymptomatic other eye. All the 36 patients who had symptomatic CSR in one eye underwent ocular examination, which included Best Corrected Visual Acuity (BCVA), 90 Dioptre (D) evaluation of macula, 5-line raster scan and topographic scan with SD-OCT machine of both eyes. Fundus Fluorescein Angiography (FFA) and Indocyanine Green Angiography (ICG) were done wherever necessary to confirm diagnosis and to find out leaks. Patients with hazy media, Age-Related Macular Degeneration (AMD), inflammatory choroiditis were excluded from study as well as those with bilateral symptomatic CSC.

**RESULTS**

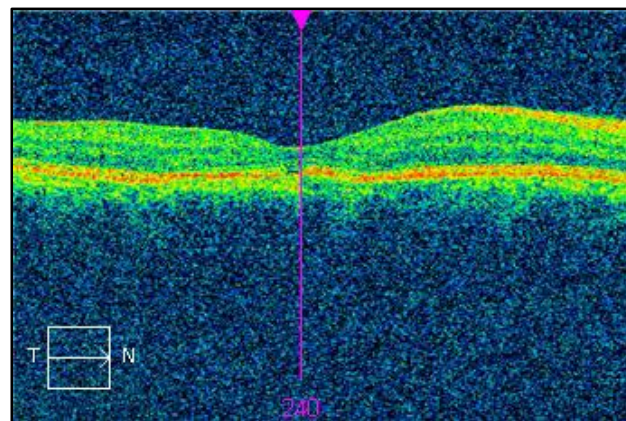
Among this, 26 cases (72%) were males and 10 females (28%) with right eye involvement in 21 (58%) of cases and that of left eye in 15 (42%) cases. Majority (29) patients in the age group 31-50 years (81%), four patients in 21-30 years range (11%) and one patient each in 11-20 years and 51-60 years group. Duration of the symptoms in 58% patients was less than one month while 42% had more than one month.



**Figure 1. Pigment Epithelial Detachment with CSC**



**Figure 2. CSC**



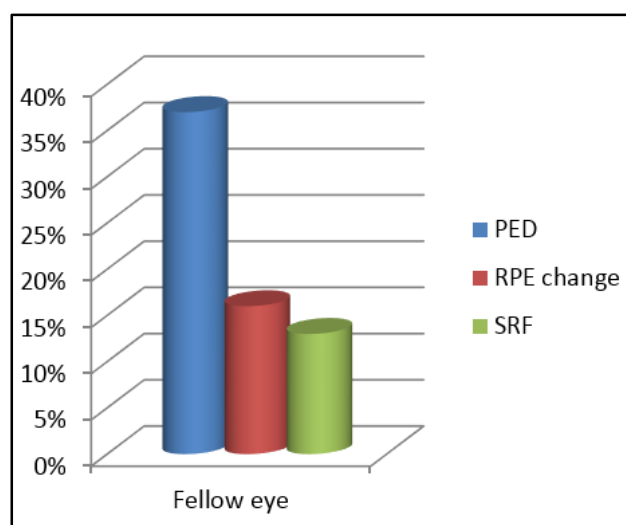
**Figure 3. Foveal Atrophy Following CSC**

BCVA	Symptomatic Eye	Asymptomatic Eye
6/6	4	15
6/9	11	3
6/12	10	1
6/18	4	0
= or <6/24	7	0

**Table 1. Visual Acuity in Study Population**

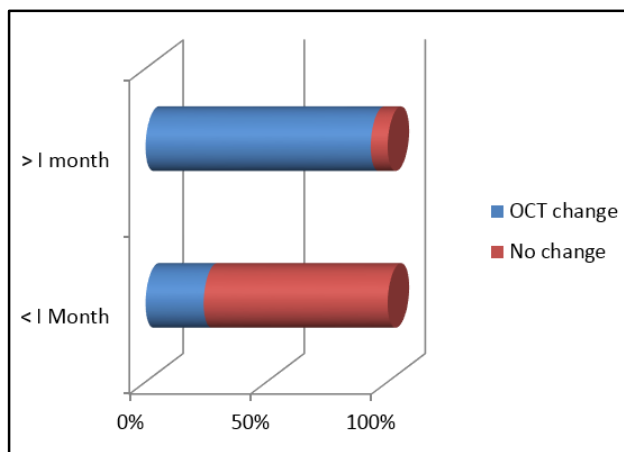
SD-OCT showed retinal Pigment Epithelial Detachments (PED) in the affected eye in 28 (78%) cases. Out of this, 64% (18 cases) had single PED and 36% (10 cases) multiple PEDs. Four cases had four PEDs and two cases had 3 PEDs and four cases had two PEDs. Location of the PEDs also varied. 50% had foveal PED, 32% had extrafoveal PED and 18% had multiple PEDs involving foveal and extrafoveal region.

19 cases (53%) had SD-OCT changes in asymptomatic eye. Out of this, 13 (37%) cases had PED (Figure 1), 5 (13%) cases with subretinal fluid (Figure 2) (13%) and 6 (16%) cases had retinal pigment epithelial changes (Figure 3).



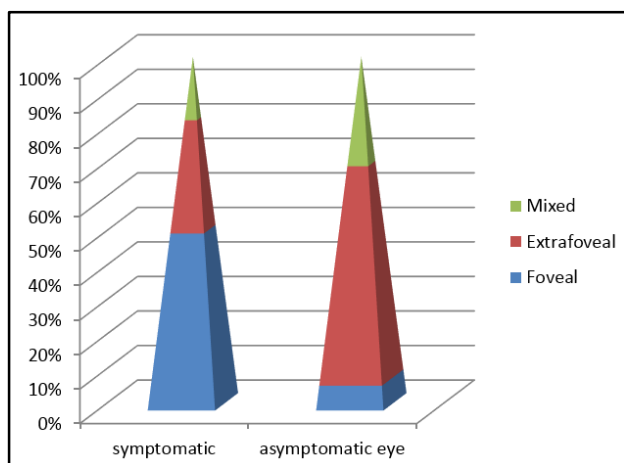
**Chart 1. Showing Findings in Asymptomatic Eye**

93% of patients of more than one month duration has OCT changes while only 24% of less than one month history has OCT changes in the asymptomatic eye (Chart 2).



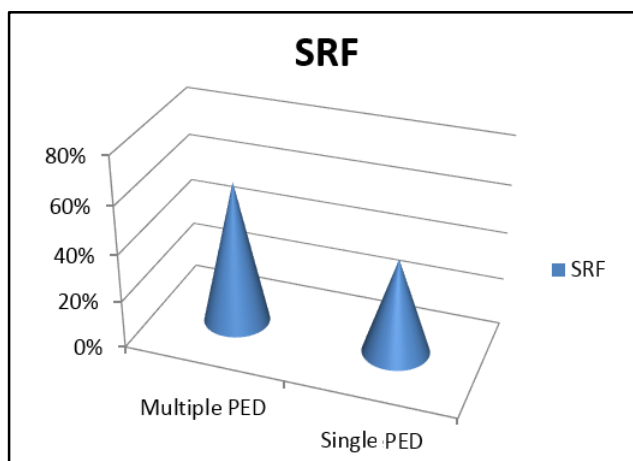
**Chart 2. Showing OCT Changes in Asymptomatic Eye**

Among the patients with PED, 62% (8 cases) had extrafoveal PED, one patient with foveal PED (7%) and 4 patients (31%) with multiple PED in foveal and extrafoveal region (Chart 3).



**Chart 3. Showing Location of Findings**

In patients with SRF, 60% had multiple PED and 40% had single PED (Chart 4).



**Chart 4. Showing SRF and PED**

60% patients with SRF had multiple PED involving foveal region and extrafoveal region. 50% of patients with SRF had RPE irregularities and atrophic changes. 40% of cases with

SRF seen extrafoveally and 60% had both foveal and extrafoveal fluid. 38% of patients with PED has SRF and 33% of patients with RPE change has SRF.

**DISCUSSION**

Spectral domain OCT is a commonly used noninvasive imaging to study retinal and choroidal disease. In CSC, the fundus picture that we get in SD-OCT can be used to correlate with the OCT findings. The findings in the OCT of asymptomatic other eye can be interpreted with the help of the fundus picture available as scanning laser ophthalmoscopic picture. Newer technologies allow accurate image capturing using scanning laser ophthalmoscopic pictures and eye tracking systems. CSC may occur subfoveally, perifoveally or extrafoveally. Some of the asymptomatic eyes had extrafoveal CSC. This underlines the fact that CSC can be bilateral and can be symptomatic in only one eye. The presence of only PED in the asymptomatic eyes suggest that the pathologic process is evolving with asymmetric clinical presentation.<sup>7</sup> So, it is reasonable to conclude that CSC is a bilateral disease with an asymmetric presentation. We can also conclude that CSC initially present as serous pigment epithelial detachments, which subsequently lead on to defect in the retinal pigment epithelium and the accumulation of subretinal fluid. The study has also shown as an incidental finding that in people with CSC has got prominently thickened choroid not only in the symptomatic eye, but also in the asymptomatic other eye. This again suggest that CSC is a disease of choroidal vasculature.

ICG angiographic studies have revealed the bilateral nature of CSC. Many of these patients have small or occult pigment epithelial detachments, which are not clinically seen or on fundus photo or on fluorescein angiography. OCT invariably could pick up all pigment epithelial detachments, however, small they are. Asymptomatic eyes showed not only pigment epithelial detachments, but also focal or diffuse retinal pigment epithelial atrophy, drusen-like deposits, subretinal precipitates and extrafoveal serous detachments. Even though, CSC is a disease of young adult males. Spaide et al reported a study conducted on 130 older patients with neurosensory macular detachment. Out of these, 57 were diagnosed with CSC after they turned 50. Spaide et al observed in patients aged 50 years and older that the areas with choroidal vascular hyperpermeability were almost always bilateral (96.90%), even if patients had unilateral visual disturbance.<sup>3,7</sup> OCT scanning reveals serous pigment epithelial detachments more often than previously recognised, not only in eyes with neurosensory detachment, but also in asymptomatic other eye of patients with unilateral CSC. Guyer by ICG angiography detected many occult small PEDs, which were not observed clinically and by FA.<sup>8</sup> A higher tendency towards bilaterality with exudative manifestations were observed by him in elderly people. A pink halo surrounding the PED is caused by shallow separation of the retina at the edge of the pigment epithelial detachments. Colour fundus photography will show retinal pigment migration or retinal pigment atrophy. A subserous

or pigment epithelial fibrin is also seen in CSC. Chronic or long-standing pigment epithelial detachments may present in CSC. One study showed that the choroidal vascular abnormalities in patients with CSC remained in all the symptomatic eyes after cessation of leakage during the follow-up period. These findings were also seen in majority of the fellow asymptomatic eyes. These findings remained unaltered during the follow up period.

In fundus, fluorescein angiogram pigment epithelial detachments in the asymptomatic eye may appear as a diffuse hyperfluorescence. Sometimes, there are multiple pigment epithelial detachments are seen in the asymptomatic eye. Occasionally, in asymptomatic eyes, single or multiple leakage points are seen as in the symptomatic eye. In the asymptomatic eye, window defects are seen. These window defects overly the areas of choroidal hyperpermeability. Whenever the disease is chronic the mottled hyperfluorescence may be seen. Hyperpermeability in the mid phase of the ICG angiogram is a consistent finding in CSC.<sup>9</sup> The areas of hyperpermeability enlarge during the later phases of the Indocyanine green angiogram. Sometimes, there will be multiple hyperfluorescent areas noted in angiogram, which suggest occult pigment epithelial detachments. This also shows that CSC is a more widespread disease than previously believed. Choroidal hyperpermeability may be associated with actual leak in fluorescein angiogram, but not invariable. OCT can pick up serous detachments of the retina and pigment epithelial detachments. It can also be used to track the resolution of the fluid by looking at the height of the serous retinal or pigment epithelial detachments. This tool can also detect findings like pigment epithelial detachments in the asymptomatic other eye. This will definitely reduce the need of repeat angiograms.

In our study, OCT changes in asymptomatic eye is found to be 53%, while study by Gupta showed changes in 94% cases.<sup>10</sup> Study by Bujorborua and Chatterjee showed fellow eye changes in 44.54% cases.<sup>7</sup> As the disease becomes chronic, the chance of changes in other eye is high, i.e. 74% in CSR cases of more than one month duration compared to 26% of less than one month duration. In our study, PED seen in 37% of cases while in Gupta study it is 12% and study by Bujorborua and Chatterjee had PED in 33% cases. 16% had RPE abnormalities like RPE bump and atrophic changes in our study while Gupta showed RPE bump in 94% eyes and 51% in Bujorborua and Chatterjee. SRF is seen more in cases with multiple PED (60%) than with single PED (40%). Extrafoveal and multiple PED is seen with eyes having SRF. 50% eyes with SRF has RPE changes. SRF is seen more in cases with PED (37%) than with RPE change (33%).

## CONCLUSION

In our study, we have found out that more than half of the patients (53%) have OCT changes in asymptomatic eye in patients with CSR indicating that it is a bilateral disease, i.e. 37% PED, 16% RPE change and 13% SRF. Changes in other eye is seen more in chronic cases, i.e. 74% in more than one month duration and 26% in less than one month duration. Asymptomatic eye also has SRF in 13% cases and when it is extrafoveal, patient is not symptomatic in that eye. SRF is seen more in eyes with multiple PED, RPE changes and chronic cases. These eyes needs close follow up and these maybe the predictive factors for the development of CSR in future.

## REFERENCES

- [1] Manjunath V, Taha M, Fujimoto JG, et al. Choroidal thickness in normal eyes measured using cirrus HD optical coherence tomography. *Am J Ophthalmol* 2010;150(3):325-329.
- [2] Kuroda S, Ikuno Y, Yasuno Y, et al. Choroidal thickness in central serous chorioretinopathy. *Retina* 2013;33(2):302-308.
- [3] Spaide RF, Koizumi H, Pozzoni MC. Enhanced depth imaging spectral-domain optical coherence tomography. *Am J Ophthalmol* 2008;146(4):496-500.
- [4] Fujiwara T, Imamura Y, Margolis R, et al. Enhanced depth imaging optical coherence tomography of the choroid in highly myopic eyes. *Am J Ophthalmol* 2009;148(3):445-450.
- [5] Imamura Y, Fujiwara T, Margolis R, et al. Enhanced depth imaging optical coherence tomography of the choroid in central serous chorioretinopathy. *Retina* 2009;29:1469-1473.
- [6] Margolis R, Spaide RF. A pilot study of enhanced depth imaging optical coherence tomography of the choroid in normal eyes. *Am J Ophthalmol* 2009;147(5):811-815.
- [7] Bujarborua D, Chatterjee S, Choudhury A, et al. Fluorescein angiographic features of asymptomatic eyes in central serous chorioretinopathy. *Retina* 2005;25(4):422-429.
- [8] Guyer DR. Central serous chorioretinopathy. In: Yannuzzi LA, Flower RW, Slakter JS, eds. *Indocyanine green angiography*. St. Louis: Mosby 1997:297-304.
- [9] Hiram Y, Tsujikawa A, Sasahara M, et al. Alterations of retinal pigment epithelium in central serous chorioretinopathy. *Clin Exp Ophthalmol* 2007;35(3):225-230.
- [10] Gupta P, Gupta V, Dogra MR, et al. Morphological changes in the retinal pigment epithelium on spectral-domain OCT in the unaffected eyes with idiopathic central serous chorioretinopathy. *Int Ophthalmol* 2010;30(2):175-181.