

VARIATIONS IN DISTRIBUTION PATTERNS OF CORONARY ARTERIES IN CADAVERIC HEART

Sanjay Kumar Sinha¹, Vipin Kumar², Madhu Sinha³, Pramod Kumar Agrawal⁴

HOW TO CITE THIS ARTICLE:

Sanjay Kumar Sinha, Vipin Kumar, Madhu Sinha, Pramod Kumar Agrawal. "Variations in Distribution Patterns of Coronary Arteries in Cadaveric Heart". Journal of Evidence based Medicine and Healthcare; Volume 1, Issue 12, November 24, 2014; Page: 1511-1517.

ABSTRACT: The heart is supplied by two coronary arteries and their branches. Variations occur occasionally in their origin and patterns of distribution. The coronary circulation and its collateral circulation has long been a topic of interest. The branches of the coronary arteries are generally considered to be functionally end arteries. However anastomoses do exist between branches of coronary arteries on the surface of the heart and between these arteries and extra cardiac vessels. These collaterals may or may not be well developed in individuals with normal cardiac anatomy. Vulnerability of an individual to develop coronary collaterals may characterize the myocardial susceptibility hence knowledge of branching pattern and mechanisms involved in formation of collaterals may aid in the treatment of coronary heart diseases.

KEYWORDS: Heart, Coronary arteries, Variations, Anastomosis, Distribution.

INTRODUCTION: Heart is a pair of valved muscular pumps combined together in a single organ.⁽¹⁾ The heart needs an uninterrupted supply of nutrition and oxygen throughout life due to increased susceptibility of the myocardium to ischaemia. The heart is supplied by the two coronary arteries and their multiple branches. The veins that drain the myocardium do not have names that corresponds to arteries in this respect the heart resembles the brain.⁽²⁾ The arterial supply of heart is provided by the right and left coronary arteries which arise from the ascending aorta immediately above the aortic valve. The coronary arteries and their major branches are distributed over the surface of heart lying within subepicardial connective tissue.⁽³⁾ The importance of knowledge of the course and branches of both coronary arteries has increased considerably in recent years as these arteries are often visualized both diagnostically and therapeutically in living during coronary angiography.

The pattern of branching of coronary arteries shows considerable variations.⁽⁴⁾ The right coronary artery (RCA) arises from the anterior aortic sinus, passes anteriorly and to the right between the right auricle and the pulmonary trunk and descends vertically in the coronary sulcus between right atrium and right ventricle. Near its origin, the RCA gives off sinoatrial nodal branch. The RCA then descends in the atrioventricular groove and gives off the right marginal branch. Then the RCA on reaching the inferior margin of the heart turns to left and continues in the coronary sulcus on to diaphragmatic surface and base of heart. Here it gives off the atrioventricular nodal branch at the crux of heart and a final major branch the posterior interventricular branch which lies in the posterior interventricular sulcus.

Typically the RCA supplies the right atrium, most of right ventricle, part of left ventricle (diaphragmatic surface), part of interventricular septum, sinoatrial node and the atrioventricular node. The left coronary artery (LCA) originates from left posterior aortic sinus and passes

ORIGINAL ARTICLE

between the pulmonary trunk and left auricle and runs in the coronary sulcus. While still posterior to the pulmonary trunk, the artery divides into its two terminal branches, the anterior interventricular branch (left anterior descending artery) and the circumflex branch.

The anterior interventricular branch continues and descends obliquely towards the apex of heart in the anterior interventricular groove and turns around the inferior border of heart and commonly anastomoses with the posterior interventricular branch of the right coronary artery. Along its course it gives off one or two diagonal branches. The smaller circumflex branch of the LCA runs in the coronary sulcus around the left border of heart to reach the posterior surface of the heart. A large branch the left marginal artery usually arises from it and continues across the rounded obtuse margin of heart.

Typically the LCA supplies to the left atrium, most of the left ventricle, part of right ventricle, and most of interventricular septum including the atrioventricular bundle of His and its branches. Variations in branching patterns and distribution of coronary arteries are common. The most common variant is right dominant pattern, present in approximately 67% of people where the posterior interventricular branch arises from the RCA. In about 15% of people the LCA is dominant, where posterior interventricular branch arises from the left circumflex branch of LCA. Apart from right and left coronary dominance, there is balanced coronary circulation.⁽⁵⁾

Anastomosis between right and the left coronary arteries are abundant during foetal life, but are much reduced by the end of first year of foetal life. Anastomoses providing collateral circulation may become prominent in conditions of hypoxia and in coronary artery diseases.⁽⁶⁾The potential for development of collateral circulation probably exists in most of heart if not all hearts. The anterior interventricular branch ends in terminal anastomosis with posterior interventricular branch of right coronary artery.

MATERIALS & METHODS: The present study was conducted in the Department of Anatomy, Katihar Medical College, Katihar, Bihar over a period of 5 years during which 30 specimens from both sexes of intact heart with great vessels were dissected and removed from the adult cadavers during routine dissection. The specimens were washed in running water to remove coagulated blood clots and were fixed in 10% formalin. Photograph of each specimen was taken prior to injection of Eosin solution (Fig. 1). Eosin solution was injected into each coronary artery by polythene cannulae under constant pressure. The pressure was maintained in order to prevent rupture of small vessels and for optimum penetration of eosin solution.

ORIGINAL ARTICLE

Fig. No 1: Intact Cadaveric Heart Prior to Injection of Eosin Solution.

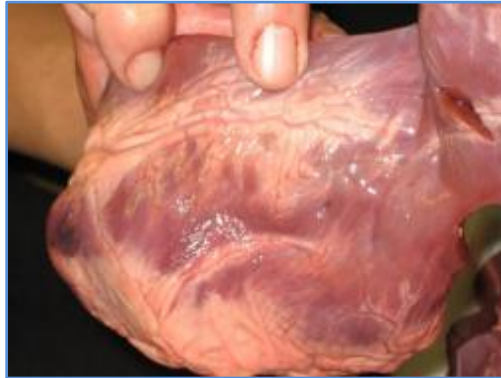

Fig. 1

OBSERVATION: Both coronary arteries were observed to arise from the root of the aorta and were seen to course subepicardially in the atrioventricular and interventricular grooves and the RCA was seen to be arising from the anterior aortic sinus and its branches originated at about right angles (Fig. 2). The RCA terminated on the diaphragmatic surface of the heart with two or more branches descending in or parallel to the interventricular sulcus towards the apex cordis.

Fig. No 2: AO=Aortic Orifice, LCA= Left Coronary Artery & RCA= Right Coronary Artery.

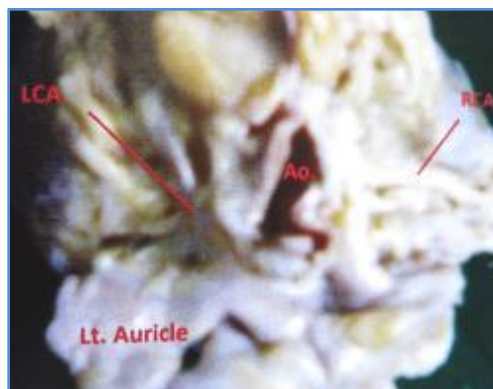


Fig. 2

Almost in all cases the LCA was short and normally had no branches proximal to its bifurcation. The left descending branch is a continuation of the left main coronary trunk which was seen to course in the anterior interventricular sulcus up to the apex cordis. The left circumflex coronary artery was seen to originate from the LCA at right angles (Fig. 3). 2 out of 30 examined hearts (6.6%) had a third coronary artery (TCA) (Fig.4). They were seen to arise from the right aortic sinus and their orifices in all cases were in front and to the left of the orifice of the right ventricle.

ORIGINAL ARTICLE

Fig. No. 3: Left Anterior Descending Branch of Left Coronary Artery.

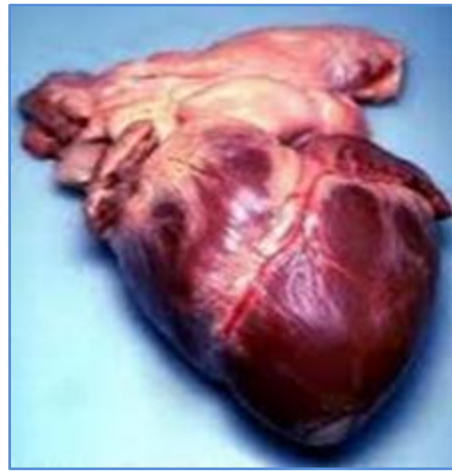


Fig. 3

Fig. No. 4: 1 = Left Coronary Artery, 2= Right Coronary Artery, 3 = Third Coronary Artery

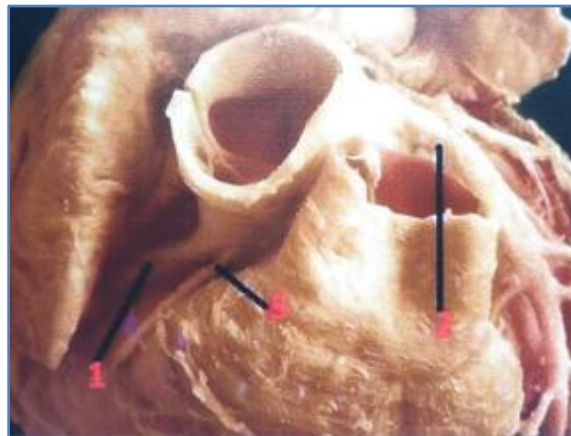

Fig. 4

Based on the distribution of coronary arteries and their branching patterns, 3 types of coronary circulations were considered. [A] Right dominant; [B] Balanced and [C] Left dominant. The RCA dominance was observed in 21/30 cases (70%) and in these cases, right coronary extended beyond the crux cordis. Balanced coronary artery circulation was observed in 6/30 cases (20%). LCA dominance was found in 3/30 cases (10%). In 20/30 cases (67%) ramus osticavaesuperioris was observed. It arose from the RCA in 12/20 cases (60%) and from LCA in 8/20 cases (40%). This vessel was not found to arise from both coronary arteries in same heart. The interventricular septum was observed to receive most of its blood supply from the left anterior descending branch.

In 22/30 cases (73%) the septal blood supply was provided by branches of left descending artery and 8/30 cases (27%) by branches from the posterior descending artery.

ORIGINAL ARTICLE

DISCUSSION: In regard to the classification of type of coronary circulation into right or left dominance and balanced circulation, in this study percentages were similar to those reported by Pino et al.⁷ Frequency of right dominance was lower than those reported by Blunk⁸ and di Dio, Lima Junior et al⁹ and Falci Junior et al.¹⁰ In none of the hearts studied did the RCA and the circumflex branch of the LCA ended in parallel in posterior interventricular branches as reported before. The anterior interventricular branch ended in termino-terminal anastomosis with posterior interventricular branch of the RCA and in a frequency between those reported by Hadziselimovic¹¹ and Secerov and Cavalcanti et al.¹²

Data about the frequency of the third coronary artery is rather diverse, from 1.5% and 8% as stated by Lo and Kurija.^{13, 14} In this study the incidence of TCA was found to be 6.6% which was consistent with the result received by Villanoga and Yamagishi.^{15, 16} Hadziselimovic¹⁷ points out that even three coronary arteries may arise independently from the right aortic sinus. In 15% cases trifurcation of coronary artery was present where TCA was known as median artery reported by Sinha P et al.¹⁸ Literature describes cases with anastomosis of TCA with the anterior interventricular branch, diagonal branch, circumflex branch as well as with the branches of RCA. This study ascertained solely anastomosis of the TCA with anterior interventricular branch with formation of Vieussens arterial ring.

This arterial ring may be found by conal branch of RCA but it is less significant as it is more often enfolded with the atherosclerotic process. According to Miyazaki and Kato¹⁹ the TCA may develop after birth. Observations of the present study has revealed that TCA gives 3 branches in 50% of the cases. In this study we also observed that the TCA extend epicardially to supply apex of the heart.

The right and left coronary ostia were present at the anterior and left posterior aortic sinuses respectively in all cases and there were no variations in the locations of the ostia. Sinha²⁰ et al has reported that in 5% cases two separate ostia were found for anterior interventricular and circumflex artery. As per the documented literature the S.A. node received special arterial supply. The present findings are in accordance of studies of James and Burch.²¹

These authors have pointed out that S.A. nodal artery is the largest atrial coronary branch which originates from the RCA or LCA. This study has confirmed the presence of main septal branches of the anterior and posterior descending arteries as described by such workers as Gross (1921),²² James (1961),²³ Fulton (1965),²⁴ and Mitchell & Schwartz (1965).²⁵ The present findings are in agreement with their descriptions that the major part of the interventricular septum of all hearts is supplied by branches of anterior descending artery. In this study RCA dominance was 70% and LCA dominance was 10% and balanced dominance was 20% which were similar to those reported by Pino at al.²⁶

CONCLUSION: In all the cadaveric hearts the coronary arteries arises from the aortic sinus. The incidence of third coronary artery holds importance in clinical practice as sometimes atherosclerotic lesions are found in this vessel. The results shows that pattern of coronary supply along with anastomosis are present in the heart with some variations. The distribution was more in favour of right coronary dominance. The coronary collateral blood flow may be an important protective response to acute and chronic Ischaemia. The distribution of S.A. nodal arteries allows understanding the possible aetiology of the Sinusal Nodal Syndrome and permits the surgeon a

ORIGINAL ARTICLE

safe approach to cardiac disease. Caution should therefore be taken during surgical procedure along the anterior wall of the right ventricle and infundibulum since such a long TCA may present a surgical hazard.

REFERENCES:

1. Standring, S. Gray's Anatomy. The Anatomical Basis of Clinical Practice. Churchill Living Stone Elsevier, Spain, 40thed.2008; 960-961.
2. Sinnatamby C.S. Last's Anatomy. Regional and Applied, Churchill Living Stone Elsevier, China, 12thed. 2011; 204-205.
3. Snell, R.S. Clinical Anatomy by Regions. Lippincott Williams & Wilkins, Wolters Kluwer, South Asian Edition, India, 9th Edition, Second Indian Reprint, 2013; 86-87.
4. Singh, I. Textbook of Anatomy with Colour Atlas, Jaypee Brothers Medical Publishers, New Delhi, 4th ed. 2008; 978-979.
5. Pino, J.H. Disposicion de lasramasarterialesventriculares en corazones de individuoschilenos. An AnatNor 1987; (5):67-72.
6. Standring, S. Gray's Anatomy. The Anatomical Basis of Clinical Practice. ChurchillLivingstone Elsevier, Spain, 40thEdition, 2008; 978 -979.
7. Pino J.H. Disposicion de lasramasarterialesventriculares en corazones de individuoschilenos. An AnatNor 1987; (5):67-72.
8. Blumk, J.N. Types of coronary circulation in human hearts. Ohio State Med J, 1971 ;(67):596-607.
9. Lima, J. Tipos de circulacao e predominancia das arteriascoronariasemcoracoes de brasileiros. Rev Bras Cir Cardiovasc 1993; (8):9-19.
10. Junior, F. Estudo comparativo do padrao de circulacocoronariana entre pecasanatomicas e pacientescirurgicos. Rev HospClinFac Med S Paulo 1996; (51):224-7.
11. Hadziselimovic, H, Seceriv, D: Superficial anastomosis of blood vessels in human heart. Acta Anat. 1979; 104: 268-78.
12. Cavalcanti, JS, Oliveira, ML. Melo JR, AVP, Balaban, G, Oliveira, CLA, Oliveiea, RL. Contribuicaoaoestudo das variacoesanatomicas das arteriascoronarias. Arq Bras Cardiol 1995; 65:489-92.
13. Lo E.A., dia A., Ndiaye A., sow M.L.: Anatomy of coronary arteries. Dakar med. 1994.39(1):23-29.
14. Kurjia H.Z., Chaudhaey M.S., Olson T.R: coronary artery variation in a native Ieaqi population. Cathet. Caediovasc. Diagn 1986:12(6):386-390.
15. Vilallonga J.R: Anatomical variations of the coronary arteries: The most frequent variations. Eur.J.Anat. 2003;7(1): 29-41.
16. Yamagishi M., haze K., Tamai J., Fukami K., Beppu S., akiyama T., Miyatake K: Visualization of isolated conus artery as a major collateral pathway in patients with total left anterior descending artery occlusion. Cathet. Cardiovasc. Diagn. 1988; 15(2):95-98.
17. Hadziselimovic, H, Seceriv, D: Superficial anastomosis of blood vessels in human heart. Acta Anat. 1979; 104: 268-78.
18. Sinha P., Mehrotra N., Jethani S.L., Bindal U., Histo- Morphological study of coronary artery. J.Anat. Soc. India 58(2) 166-168 (2009).

ORIGINAL ARTICLE

19. Miyazaki, M. & Kato, M: Third coronary artery: its development and function. *Actacardiol*, 43(4): 449-57; 1988.
20. Sinha P., Mehrotra N., Jethani S.L., Bindal U., Histo- Morphological srudy of coronary artery. *J.Anat. Soc. India* 58(2) 166-168 (2009).
21. James, T.N.(1961): Anatomy of the human Sinus node. *Ant.Rec.*, 141, 109.
22. Gross, L. (1921). The blood supply of heart. Oxford university press, London.
23. James, T.N.(1961): Anatomy of the coronary arteries. Hober. New York.
24. Fulton, W.F.M. (1965). The coronary Arteries. Thomas Springfield, Illinois.
25. Mitchrll, J.R.A., and Schwartz, C.J. (1965). Arterial Disease. Blackwell, Oxford.
26. Pino, Jh, Riffo, EO, Vargas, JE. Disposicion de lasramasarterialesventriculares en corazones de individuoschilenos. *An AnatNor* 1987; 5:67-72.

AUTHORS:

1. Sanjay Kumar Sinha
2. Vipin Kumar
3. Madhu Sinha
4. Pramod Kumar Agrawal

PARTICULARS OF CONTRIBUTORS:

1. Associate Professor, Department of Anatomy, Katihar Medical College, Katihar, Bihar.
2. Assistant Professor, Department of Anatomy, Lord Buddha Koshi Medical College, Saharsa, Bihar.
3. Medical Officer, Department of Health, Madhubani, Bihar.

4. Professor and HOD, Department of Medicine, Katihar Medical College, Katihar, Bihar.

NAME ADDRESS EMAIL ID OF THE CORRESPONDING AUTHOR:

Dr. Sanjay Kumar Sinha,
Associate Professor,
Department of Anatomy,
Katihar Medical College,
Katihar-854105, Bihar.
E-mail:dr.s.k.sinha.2709@gmail.com

Date of Submission: 18/10/2014.
Date of Peer Review: 20/10/2014.
Date of Acceptance: 11/11/2014.
Date of Publishing: 20/11/2014.