

Multiple Cannulated Cancellous Screws and Dynamic Hip Screw with Derotation Screw for Fixation of Basicervical Femoral Neck Fracture in Young Adults- A Prospective Comparative Study

Munin Borgohain¹, Aswin Deepak Rajan², Abhinab Gogoi³, Sandeep Prasad⁴

¹Professor and HOD, Department of Orthopaedics, Assam Medical College, Barbari, Dibrugarh, Assam, India.

²Postgraduate Trainee, Department of Orthopaedics, Assam Medical College, Barbari, Dibrugarh, Assam, India.

³Postgraduate Trainee, Department of Orthopaedics, Assam Medical College, Barbari, Dibrugarh, Assam, India.

⁴Postgraduate Trainee, Department of Orthopaedics, Assam Medical College, Barbari, Dibrugarh, Assam, India.

ABSTRACT

BACKGROUND

In fractures of the femoral neck, anatomic reduction is compulsory and maintaining the reduction is crucial. It is an enigma to orthopaedic surgeons and a curse for an individual with complications like avascular necrosis and non-union.¹ Fracture neck of femur in young adults are uncommon and only 2-3% of all intracapsular hip fractures occur in younger adults.² There is lack of consensus in treating the young adult patients.³ Basicervical fractures of femur are relatively rare injuries which account for only 1.8–7.6% of hip fractures.⁴ Traditionally, most intracapsular neck femur fractures in young adults had been treated with multiple Cancellous Cannulated Screws (CCS) whereas inter-trochanteric (extracapsular) fractures had been managed well in the past with the Dynamic Hip Screw (DHS).

METHODS

A prospective comparative study was done in the Department of Orthopaedics at Assam Medical College, Dibrugarh for a 2 year duration from June 2017 to December 2019 with a minimum of one year follow-up. Informed consent for inclusion in the study was taken from every patient. A detailed history and thorough physical examination was done followed by relevant investigations and radiological evaluation.

RESULTS

A total of 34 patients were initially included in this study. 17 patients were treated with CCS (Group 1), 17 with DHS with DRS (Group 2). One patient in group 1 and one in group 2 was lost to follow up due to change in address / contact number and were excluded from the study for final evaluation.

CONCLUSIONS

Basicervical fractures act as an unstable extra-capsular fracture rather than a stable intracapsular fracture neck of femur. The present study supports the hypothesis that this type of fracture neck of femur surely needs anatomical reduction and fixation for which Dynamic Hip Screw with derotation screw is a best implant in terms of both radiological and functional outcome. Although initial clinical outcome scores were better in DHS group, both implants have almost similar outcome in long term follow up. However, it is difficult to draw a common conclusion from such a small sample size. A larger sample size is probably needed to identify the definitive method for these fractures.

KEYWORDS

Fracture Neck of femur, Basicervical, Cannulated Cancellous Screw, Dynamic Hip Screw

Corresponding Author:

Dr. Aswin Deepak Rajan,

Postgraduate Trainee,

Department of Orthopaedics,

Assam Medical College,

Barbari, Dibrugarh- 786002,

Assam, India.

E-mail: aswinderajan@gmail.com

DOI: 10.18410/jebmh/2020/62

Financial or Other Competing Interests:
None.

How to Cite This Article:

Borgohain M, Rajan AD, Gogoi A, et al.

Multiple cannulated cancellous screws

and dynamic hip screw with derotation

screw for fixation of basicervical femoral

neck fracture in young adults- a

prospective comparative study. J. Evid.

Based Med. Healthc. 2020; 7(6), 292-

296. DOI: 10.18410/jebmh/2020/62

Submission 20-01-2020,

Peer Review 25-01-2020,

Acceptance 06-02-2020,

Published 10-02-2020.



BACKGROUND

In fractures of the femoral neck, anatomic reduction is compulsory and maintaining the reduction is crucial. It is an enigma to orthopaedic surgeons and curse for an individual with complications like avascular necrosis and non-union.¹ Fracture neck of femur in young adults are uncommon and only 2-3% of all intracapsular hip fractures occur in younger adults.² There is lack of consensus in treating the young adult patients.³ Basicervical fractures of femur are relatively rare injuries which account for only 1.8-7.6% of hip fractures.⁴ Traditionally, most intracapsular neck femur fractures in young adults had been treated with multiple Cancellous Cannulated screws (CCS) whereas inter-trochanteric (extracapsular) fractures had been managed well in the past with the Dynamic Hip Screw (DHS). But since the basicervical fractures are an intermediate between them, so a controversy exists whether to use CCS or DHS for stabilization of these fractures. Moreover, these fractures have long been considered to be inherently unstable which makes the ideal choice of implant for their fixation more difficult.⁵ The strength for maintaining the reduction is not same in both cannulated screws and dynamic hip screw (DHS) but they have the capacity of achieving compression in the fracture site. However there was limited clinical evidence to suggest superiority of either implant in terms of avascular necrosis, non-union and need for revision surgery.⁶ No study has been documented in literature to the best of our knowledge comparing the clinical outcome of the most common implants used to treat basicervical fractures of neck of femur in young adults, Hence the aim of this study was to compare the results with fixations of the femoral neck fractures with cannulated screws versus dynamic hip screw with derotation screw and attempts to fill the void in the literature and help arrive at a conclusion regarding the usefulness of these two implants in these fractures.

METHODS

A prospective comparative study was done in our department of Orthopaedics at Assam medical college, Dibrugarh for 2 year duration from June 2017 to December 2019 with a minimum of one year follow-up. Informed consent for inclusion in the study was taken from every patient. A detailed history and thorough physical examination was done followed by relevant investigations and radiological evaluation. Radiographs of the affected hip in antero-posterior (AP) and lateral views as well as AP view of pelvis with both hips in 15 degrees of internal rotation were taken. The patients were divided into two groups by a simple randomization method. Group 1 was designated as the CCS group and Group 2 as the DHS group and the implant for fixation was accordingly decided.

Inclusion Criteria

1. Acute basicervical Femoral neck – fracture duration less than 3 weeks.

2. Age group from 18 to 65 years.
3. Patient willing to undergo surgery.
4. No associated fracture in both lower limbs.

Exclusion Criteria

1. Patients with age less than 18 years or more than 65 years.
2. Compound fractures, Polytrauma cases.
3. Subcapital and transcervical fractures.
4. Neglected fractures greater than 3 weeks.
5. Pathological fractures.
6. Fractures irreducible by closed methods.
7. History of previous hip fracture or hip surgery.
8. Patient not willing to undergo surgery.

Operative Procedure

After pre-anaesthetic check-up and clearance, patients were taken up for surgery as early as possible. All patients received intravenous ceftriaxone and amikacin sulphate before the procedure and for at least 72 h postoperatively. Patients were given spinal/epidural anaesthesia according to patient's fitness. Surgery was done in supine position in all patients on a standard fracture table with the unaffected limb held in lithotomy position. Consecutively admitted patients with acute basicervical fracture of neck of femur fulfilling the inclusion and exclusion criteria were operated by the same surgeon using three 6.5 mm partially threaded cancellous cannulated screws placed in an inverted triangle fashion (group 1) or a DHS with a derotation screw (group 2). Fractures in both groups are closely reduced by applying longitudinal traction as well as lateral traction and then internally rotated with abduction at hip.

In patients treated by cannulated screws, the proximal femur is approached. Through limited longitudinal stab lateral incision from just distal to the greater tubercle. Then insertion of guide pin along the anterior aspect of the neck to determine the amount of anteversion, and using pin angled guide on the lateral aspect of the thigh over femur for insertion of the 2 mm guide pins in to the femoral neck in a triangular configuration, they were kept about 5 mm from the subchondral bone, and the position was confirmed by image intensifier on AP and lateral views. Self-tapping 6.5 mm partially threaded cancellous cannulated screws were inserted and tightened sequentially, and the position confirmed on C-arm. At the end of fixation, the guide pins were removed, securing good haemostasis, stab incisions are closed by non-absorbable suture material.

In patients treated by dynamic hip screw, proximal femur is approached through longitudinal lateral incision from just distal to the greater tubercle to 6-8 cm and extended slightly distally for insertion of side plate then a guide pin to determine the amount of anteversion was also used as in previous group, a second 3.2 mm guide pin was inserted centrally in to the femoral neck 5 mm from subchondral bone using appropriate angle guide, and confirmed on AP and lateral views, another pin parallel and cephalad to the central pin was used to prevent femoral head rotation during reaming. A 6.5 mm cannulated cancellous

partially threaded derotation screw was inserted superiorly before reaming for the DHS. A triple reamer set was assembled to 5 mm shorter than the length of central pin, thus keeping tip apex distance less than 25, reaming was done over the central pin, 12.7 mm taper was used for tapping, insertion of 12.7 mm head screw was done, then 135 degree side plate with 2-4 holes was inserted and then the plate fixed to the shaft with ordinary 4.5 mm cortical screw, a compression screw was inserted through the barrel of the side plate to attach the head screw to make compression across the fracture site. Finally, the superior pin was removed, and the wound was closed in layers over suction drain.

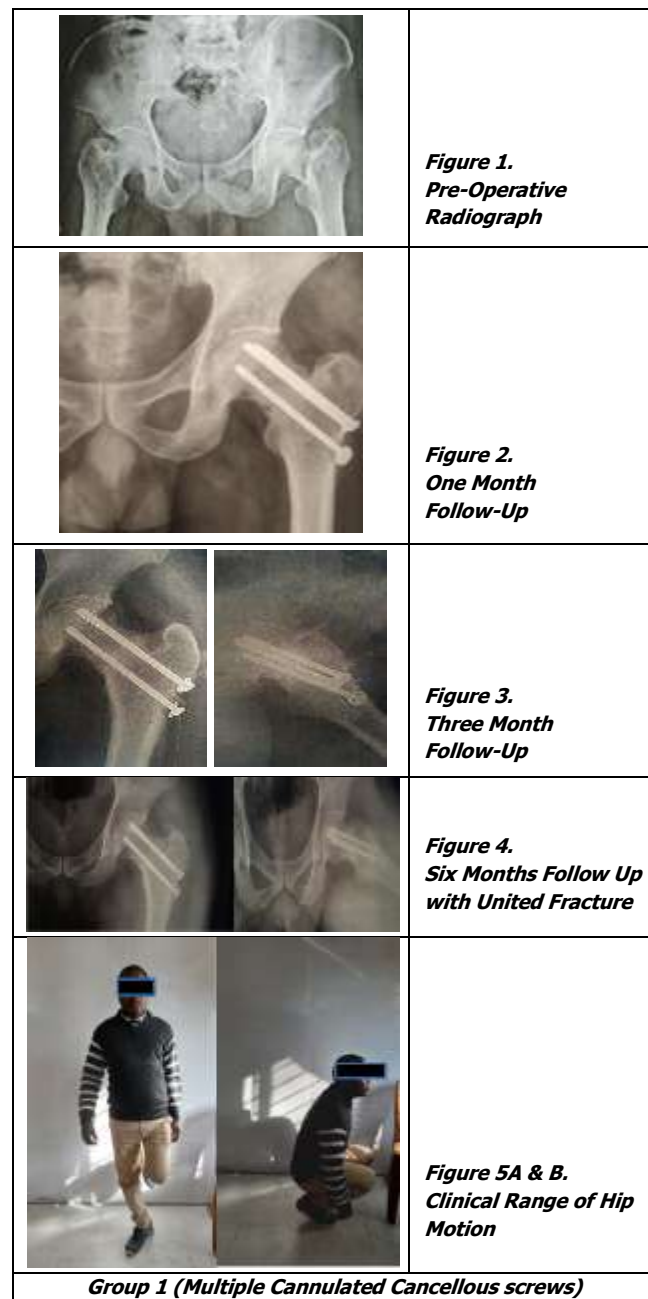
Intraoperative blood loss, operative time and incision size were noted in both the groups. Toe-touch weight bearing mobilization was started using crutches or walker on the second or third day postoperatively in both the groups and the patients were followed up at 1 month, 3 months, 6 months and then upto 1 year after the operation to note the clinic-radiological outcome.

Radiological union was assessed using plain radiographs of the pelvis in an anteroposterior view with hips in 15 degree internal rotation and lateral view. Radiographically visible trabeculations across the fracture line were considered as union, whereas no radiographically visible trabeculations across the fracture line, or re-displacement of the fracture or progressive displacement requiring a second operation were considered non-union. When sound bony union was achieved as ensured by the radiograph, full weight bearing was allowed. Complications were recorded like infection, implant failure in the form of breakage of the implant, loosening or migration of the implant, non-union and avascular necrosis (AVN). Clinical evaluation of results was done using modified Harris Hip Score.⁷ The results were classified excellent, good, fair or poor according to points obtained as follows: Excellent: HHS between 90 and 100; Good: HHS between 80 and 89; Fair: HHS between 70 and 79; Poor: HHS less than 70.

RESULTS

A total of 34 patients were initially included in this study. 17 patients were treated with CCS (group 1), 17 with DHS with DRS (group 2). One patient in group 1 and one in group 2 was lost to follow up due to change in address / contact number and were excluded from the study for final evaluation. The study included 22 men and 12 women with a mean age of 47.5 years (range 18-65 years). The most common mode of injury was by motor vehicle accident followed by fall from height and fall on ground in that order. Mean duration from trauma to surgery was 8 days, 10 days in CCS (group 1), DHS with DR (group 2) respectively and this was found to be insignificant statistically. Mean size of incision was 2.1 ± 0.4 cm in CCS group, 6.1 ± 0.9 cm in DHS group. Average duration of surgery was 36.1 minutes in group 1 and 43.6 minutes in group 2. The variability in all

these parameters among the 2 groups was statistically significant (p <0.05) I favour of group 1 (CCS). Mean time for fracture union was 14.4, 13.9 weeks in group 1 and group 2 respectively and this difference was statistically significant (p <0.01). At Initial follow ups (1 month, 3 month, 6 month) the mean Harris hip scores was significantly higher in DHS group (p <0.05). But at final follow up mean Harris hip scores was not significant showing that the long term outcome at 1 year is similar in both the groups.








Complications	CCS (n = 16)* <Group 1>	DHS (n = 16)* <Group 2>
Superficial infection	0	1(6.25%)
Screw back out (≥20mm)	1(6.25%)	1(6.25%)
Superior screw cut out	0	0
Varus collapse	2(12.5%)	0
Broken screws	2(12.5%)	0
Joint penetration	0	0
Non-union	1(6.25%)	0
AVN	0	0

Table 1. Intraoperative and Postoperative Complications
*One patient in group 1 and one in group 2 - lost follow up

Mean HHS at	Group 1 CCS (n = 16)	Group 2 DHS (n = 16)	p Value
1 month	73.53	83.28	p < 0.05)
3 months	75.07	85.80	p < 0.05)
6 months	80.49	86.43	p < 0.05)
1 year	87.50	88.45	Not significant

Table 2. Showing Results at Final Follow Up

	Figure 6. Preoperative Radiograph (AP and Lateral View)
	Figure 7. One Month Follow-Up
	Figure 8. 3 Months Follow-Up
	Figure 9. Complete Union
	Figure 10A & B. Clinical Range of Motion

Group 2 (Dynamic Hip Screw with Derotation Screw)

DISCUSSION

Fracture neck of femur is increasingly common and still imperfectly treated injury. The available literature don't have clear consensus regarding the gold standard modality of fixation of basicervical type of fracture neck of femur in adults. Results after femoral neck fractures fixation depend upon the age of the patient, amount of displacement, adequacy of reduction and adequacy of internal fixation primarily. Estimation of exact chronological and physiological age of the patient is important to frame a treatment plan. Better to do an Internal fixation than arthroplasty in young

adult patients considering the need for revision of arthroplasty in future and also preservation of the native bone.^{8,9} In this study, the incidence of basicervical fractures was more in men as compared to women and mean age was 47.5 years with most common mode of injury being motor vehicle collision. This was similar to the findings of Hu et al.¹⁰ The duration of surgery and mean size of incision was least in patients treated with CCS thus leading to the least post-operative infections and fall in Hb compared to cases treated with DHS & DR, but incidence of post-operative complications was highest in CCS group which included varus collapse in two cases, broken screws in two case and non-union in 1 case. These findings had a coincidence with the findings of Imren et al.,¹¹ Blair et al.¹² and Deneka et al.¹³ Who concluded that fracture fixation was more stable in DHS as compared to CCS. Screw backout ≥ 20 mm was noted in both of our groups each of one case. No case of AVN was noted in our study and this was similar to the findings of most other studies probably signifying that basicervical fractures are extracapsular type of fractures. Finally, DHS group having the best outcome scores as compared to CCS group at short follow ups. But at final follow up after the union achieved the difference was not significant statistically showing that the long term outcome is similar in both groups.

Limitations

The small sample size of the study may be the drawback as higher number of cases in each group is required for effective comparison and analysis of results.

CONCLUSIONS

Basicervical fractures act as unstable extra-capsular fractures rather than stable intracapsular fractures of neck of femur. The present study support the hypothesis that this type of fracture neck of femur surely needs anatomical reduction and fixation for which Dynamic Hip Screw with derotation screw is a best implant in terms of both radiological and functional outcome. Although initial clinical outcome scores were better in DHS group, both implants have almost similar outcome in long term follow up. However, it is difficult to draw common conclusions from such a small sample size. A larger sample size is probably needed to identify the definitive method for these fractures.

REFERENCES

[1] Bachiller FGC, Caballer AP, Portal LF. Avascular necrosis of the femoral head after femoral neck fracture. Clin Orthop Relat Res 2002;399:87-109.
 [2] Zetterberg C, Elmerson S, Andersson GB. Epidemiology of hip fractures in Goteborg, Sweden, 1940-1983. Clin Orthop Relat Res 1984;191:43-52.
 [3] Gupta M, Arya RK, Kumar S, et al. Comparative study of multiple cancellous screws versus sliding hip screws in

- femoral neck fractures of young adults. *Chin J Traumatol* 2016;19(4):209-212.
- [4] Saarenpää I, Partanen J, Jalovaara P. Basicervical fracture--a rare type of hip fracture. *Arch Orthop Trauma Surg* 2002;122(2):69-72.
- [5] Chen CY, Chiu FY, Chen CM, et al. Surgical treatment of basicervical fractures of femur--a prospective evaluation of 269 patients. *J Trauma* 2008;64(2):427-429.
- [6] Aminian A, Gao F, Fedoriw WW, et al. Vertically oriented femoral neck fractures: mechanical analysis of four fixation techniques. *J Orthop Trauma* 2007;21(8):544-548.
- [7] Banaszkiwicz P. Traumatic arthritis of the hip after dislocation and acetabular fractures: treatment by mold arthroplasty: an end-result study using a new method of result evaluation. *Classic Papers in Orthopaedics* 2014:13-17.
- [8] Shah AK, Eissler J, Radomisli T. Algorithms for the treatment of femoral neck fractures. *Clin Orthop Relat Res* 2002;399:28-34.
- [9] Lee RH. Femoral neck fractures. *Br Med J* 1977;1(6054):171-172.
- [10] Hu SJ, Yu GR, Zhang SM. Surgical treatment of basicervical intertrochanteric fractures of the proximal femur with cephalomedullary hip nails. *Orthop Surg* 2013;5(2):124-129.
- [11] Imren Y, Gürkon V, Bilsel K, et al. PF1 biomechanical comparison of dynamic hip screw, proximal femoral nail, cannulated screw, and monoaxial external fixation in the treatment of basicervical femoral neck fractures. *Injury* 2013;44(Suppl 2):S37.
- [12] Blair B, Koval KJ, Kummer F, et al. Basicervical fractures of the proximal femur. A biomechanical study of 3 internal fixation techniques. *Clin Orthop Relat Res* 1994;305:256-263.
- [13] Deneka DA, Simonian PT, Stankewich CJ, et al. Biomechanical comparison of internal fixation techniques for the treatment of unstable basicervical femoral neck fractures. *J Orthop Trauma* 1997;11(5):337-343.