

HIP PATHOLOGY FINDINGS ON MAGNETIC RESONANCE IMAGING- A PROSPECTIVE STUDY

Hari Ram¹, Ravinder Kumar², Arpit Vashisht³, Sahil Mehar⁴, Viral Rashminbhai Soni⁵, Shivam Batra⁶, Sheena Daswani⁷, Prateek Pate⁸

¹Assistant Professor, Department of Radiodiagnosis, Geetanjali Medical College and Hospital / Geetanjali University, Udaipur, Rajasthan, India.

²Professor, Department of Radiodiagnosis, Geetanjali Medical College and Hospital / Geetanjali University, Udaipur, Rajasthan, India.

³Third Year Postgraduate Student, Department of Radio-diagnosis, Geetanjali Medical College and Hospital / Geetanjali University, Udaipur, Rajasthan, India.

⁴Third Year Postgraduate Student, Department of Radiodiagnosis, Geetanjali Medical College and Hospital / Geetanjali University, Udaipur, Rajasthan, India.

⁵Third Year Postgraduate Student, Department of Radiodiagnosis, Geetanjali Medical College and Hospital / Geetanjali University, Udaipur, Rajasthan, India.

⁶Second Year Postgraduate Student, Department of Radiodiagnosis, Geetanjali Medical College and Hospital / Geetanjali University, Udaipur, Rajasthan, India.

⁷Second Year Postgraduate Student, Department of Radiodiagnosis, Geetanjali Medical College and Hospital / Geetanjali University, Udaipur, Rajasthan, India.

⁸Third Year Postgraduate Student, Department of Radiodiagnosis, Geetanjali Medical College and Hospital / Geetanjali University, Udaipur, Rajasthan, India.

ABSTRACT**BACKGROUND**

Magnetic Resonance Imaging (MRI) has been one of the most spectacular advances in medicine and has practically revolutionized the diagnosis of hip pathologies. This acceptance was initially due to its high sensitivity and specificity in detection of avascular necrosis of the femoral head. Since then however, MR imaging has also proved efficacious in the evaluation of primary musculoskeletal tumours, arthropathies, trauma, marrow replacement processes and osteomyelitis.

The objective of the study is to study usefulness of MRI in patients presenting with symptoms suggestive of hip pathologies.

MATERIALS AND METHODS

It was a cross-sectional study carried out in a tertiary care institute from July 2015 to November 2017. A total of 80 cases with hip pathology attending Orthopaedics OPD participated in the study. There were bilateral hip pathologies in 27 patients, so a total of 107 pathological hips were studied. All the participants were subjected to MRI scan.

RESULTS

In present study, painful hip was the most common presenting symptom in 95% followed by restricted movement - 89% and gait abnormality-79%. Avascular necrosis (AVN) femoral head was the most common pathology detected comprising 33 of the 80 cases (66%). The next most common abnormality detected was infective arthritis (25%). Bone tumours together comprise 11% of patients. Three patients of sacroiliitis were included in the study because they presented with hip pain.

CONCLUSION

MRI showed exquisite sensitivity in detecting bone marrow oedema, cartilage, labrum, synovium, joint effusion, necrosis as well as extension of the tumours. With MRI, one can stage the hip pathology to prognosticate and influence therapeutic decisions.

KEYWORDS

Avascular Necrosis, Hip Pathology, Magnetic Resonance Imaging.

HOW TO CITE THIS ARTICLE: Ram H, Kumar R, Vashisht A, et al. HIP pathology findings on magnetic resonance imaging - a prospective study. J. Evid. Based Med. Healthc. 2018; 5(42), 2938-2943. DOI: 10.18410/jebmh/2018/601

Financial or Other, Competing Interest: None.
Submission 14-08-2018, Peer Review 17-08-2018,
Acceptance 14-09-2018, Published 09-10-2018.

Corresponding Author:

Dr. Ravinder Kumar,
Professor, Department of Radio-diagnosis,
Geetanjali Medical College and Hospital / Geetanjali University,
Udaipur, Rajasthan, India.

E-mail: kundu19@yahoo.co.in

DOI: 10.18410/jebmh/2018/601

**BACKGROUND**

The hip joint is a major weight bearing joint with significant mobility. Painful hip is a common disabling musculoskeletal symptom affecting all age groups. The differential diagnosis is exhaustive, probing a diagnostic challenge, including juxta-articular, intra-articular aetiologies as well as referred pain mainly from spine or sacroiliac joints. Currently, MRI is the modality of choice (following plain radiography) for imaging AVN, radiographically occult fractures, marrow

replacement disorders, musculoskeletal neoplasms, and osteomyelitis involving the hip.^{1,2}

Because of the presence of different operative approaches and treatment strategies for different hip pathologies, accurate preoperative diagnosis became a very important goal. With the limited utility of CT scan in the differential diagnosis of various hip pathologies, MRI is generally the investigation of choice in characterization of them.

The present study emphasizes the role of MRI in the evaluation of hip pathologies. It focuses on the spectrum of different patterns of appearance of various hip pathologies on MRI scan, maximizing its diagnostic potential in the work-up of hip disease.

MATERIALS AND METHODS

The present cross-sectional study was carried out in Geetanjali Medical College and Hospital, Udaipur, from July 2015 to November 2017. The permission from the institute ethical committee was sought. All the cases with hip pathology attending Orthopaedics OPD and consenting to participate were included in the study. All the consenting participants were subjected to MRI scan. Predesigned and pretested questionnaire was used to capture demographic and findings from MRI scan.

Inclusion Criteria

The study included all patients presenting with complain of painful hip joint, irrespective of age or sex.

Exclusion Criteria

Patients with contraindication for MRI like pacemakers, recent metallic implants, aneurysmal clips, cochlear implants & any non-MR compatible prosthetic implant would be excluded from the study.

The study was performed on 1.5 Tesla Magnetom Symphony Maestro class (Manufactured by Siemens AG Co., Erlangen). In all patients, T1W images were obtained using short repetition (TR) and echo delay (TE) times (TR=400-1000msec, TE=20-25 msec), and T2W images were obtained using long TR/TE (TR=2000-2500 msec, TE=60-100msec). STIR and PD SPAIR images were also obtained whenever needed.

Intravenous contrast medium was administered using Gd-DTPA if required, 0.1 mmol/ Kg, given manually by a slow intravenous injection. Post contrast T1 weighted axial, coronal and Sagittal sequences were performed.

MRI findings were noted and recorded. Collected data was presented in the form of tables and diagrams. Frequency and percentages were calculated wherever applicable. The results of this study were analysed and compared with other available studies in literature.

RESULTS

The present study included 80 cases of patients with different hip pathologies. Following observations were made according to age, sex, symptoms and MR appearances of the various lesions and the study data were analysed.

Final Diagnosis	No. of Pts.	Percentage
Avascular necrosis	32	40
Septic arthritis	20	25
Stress fracture	2	2.5
Transient osteoporosis	1	1.25
Degenerative osteoarthritis	2	2.5
DDH	3	3.75
Perthes disease	1	1.25
Transient synovitis	3	3.75
Sacroiliitis	3	3.75
Traumatic neck fracture	3	3.75
Osteoid osteoma	2	2.5
Giant cell tumor	2	2.5
Aneurysmal bone cyst	1	1.25
Chondrosarcoma	1	1.25
Osteochondroma	1	1.25
Ewing's sarcoma	1	1.25
Fibrous dysplasia	1	1.25
Lipoma	1	1.25

Table 1. Diagnosis and Frequency of Distribution of Lesions (n=80)

The most common pathology for which MRI hip advised was AVN (40%). Next common is septic arthritis 25%. Bone tumours together comprises 11% of patients. Three patients of sacroiliitis were included in the study because they presented with hip pain.

In this study most of patients were below 60 years of age with largest group between 31-40 years (24% of all patients). Youngest patient was 11 months old having transient synovitis and the oldest patient was 75-year-old having chondrosarcoma. Most common age group having AVN femoral head was in the range of 31-50 yrs which comprised 66% of the series. Most common age group having septic arthritis was 11-20 yrs. which comprised 45% of the series.

Out of total 80 patients with different hip pathologies, 71% were male and 29% were female patients. Among AVN 79% patients were male and 21% were female. Among bone tumours 89% of the patients were male and 11% were female. In infective patients 65% were male and 35% were females.

In this study, most common presentation was pain in hip joint (95%) followed by restricted movement (89%) and gait abnormality (79%). Other complains in descending order of frequency were local swelling (45%) and fever (22%). The most common complaint in septic arthritis and infective hip joint pathology was hip joint pain associated with fever in 90% of patients.

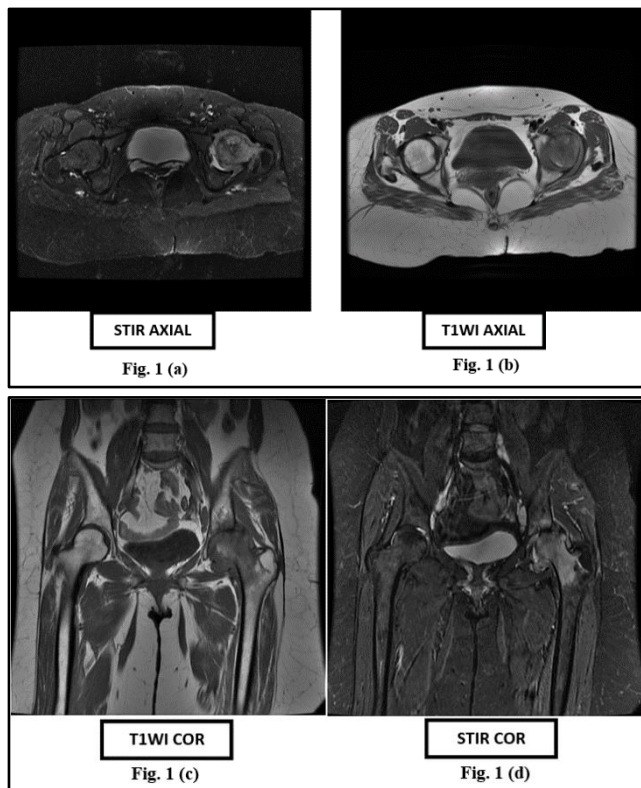
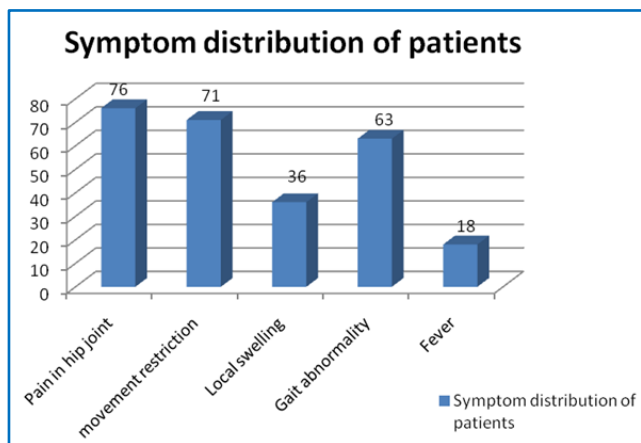


Figure 1(a-d). Septic Arthritis: Axial and Coronal Images show Abnormal Marrow Signals Involving Left Femoral Head and Acetabulum Appearing Hypointense on T1 and Hyper Intense on STIR Sequence Associated with Mild Ipsilateral Joint Effusion Suggesting Changes of Septic Arthritis.



Graph 1. Symptom Distribution of Patients

MRI Findings	No. of Lesions	%
Hip joint effusion	36	66
Loss of articular cartilage	23	42
Joint space reduction	18	33
Bone marrow oedema	40	74
Subchondral fracture	24	44
Osteophytes	6	11
Subchondral cyst	6	11
Marginal irregularity	8	15
Collapse of head	12	22
Double line sign	30	55

Table 2. MRI Findings in AVN (N=54)

In the present study most common MRI finding of AVN was bone marrow oedema which was present in 74% of the lesions followed by joint effusion 66%. Double line sign was seen in 55% of the lesions followed by subchondral fracture 44%, loss of articular cartilage in 42% and joint space reduction in 33% of patients.

Class	No. of Lesions	%
Class A	9	16
Class B	6	11
Class C	22	41
Class D	17	32

Table 3. Distribution of AVN Cases According to MRI Class (N=54)

Class C was the most common class of AVN present in 41% of the lesions followed by class D 32%.

MR Diagnosis	Grade-1	Grade-2	Grade-3	Total
AVN+Perthes disease (n=54)	17	19	0	36 (66%)
Septic/Infective aetiology (n=20)	0	8	10	18 (90%)
Transient synovitis (n=3)	1	2	0	3 (100%)

Table 4. Joint Effusion

Grade 1 and 2 joint effusion was present in 66% of hip joints affected with AVN. 34% of hips with AVN don't have joint effusion. 90% of joints with septic arthritis had grade 2 and 3 joint effusion. Effusion is of higher grade in septic arthritis than AVN. All patients with transient synovitis had joint effusion.

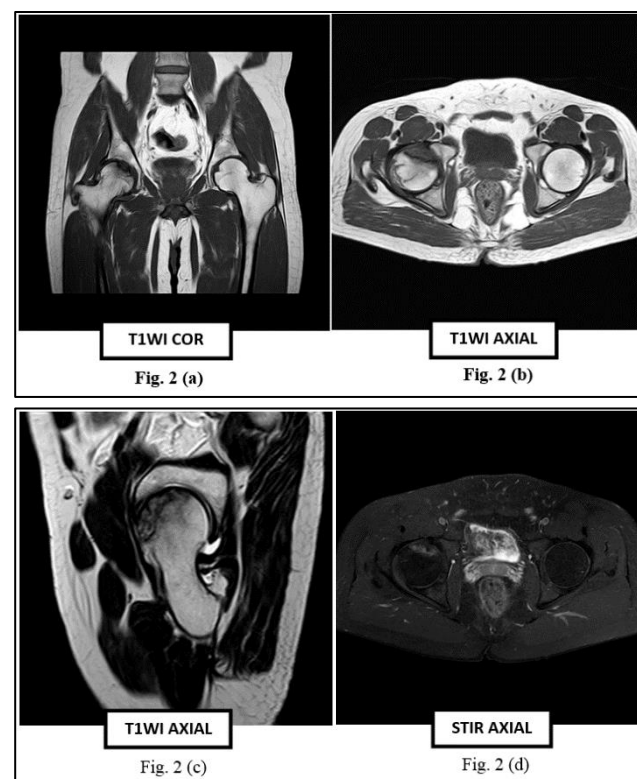


Figure 2 (a-d): Avascular Necrosis (AVN): Axial, Sagittal and Coronal Images show Abnormal Marrow Signals Involving Right Femoral Head Appearing Hypointense on T1 and Hyper Intense on STIR Sequence Associated with Subarticular Collapse Suggesting Changes of Stage III AVN Right Femoral Head.

Changes of Osteoarthritis	No. of Pts.	Percentage %
Joint space narrowing	35	33
Subchondral cyst	8	7
Osteophyte formation	11	10

Table 5. Changes of Osteoarthritis on MRI (n=107)

In the present study, most common changes of osteoarthritis is joint space reduction noted in 33% of hips studied.

MRI Findings	No. of Lesions	%
Hip joint effusion	18	90
Synovial thickening	7	35
Synovial enhancement	18	90
Fluid outpouching / grade 3 effusion	10	50
Intramuscular collections	12	60
Erosive bone destruction	10	50
Bone marrow oedema	16	80

Table 6. MRI Findings in Infective Arthritis (N=20)

The frequency of MRI findings in septic joints was as follows: synovial enhancement (90%), joint effusions (90%), intramuscular collections (60%), erosive bone destruction (50%), fluid outpouching (50%), and synovial thickening (35%). The marrow showed bare area changes are associated with (80%) of infective arthritis.

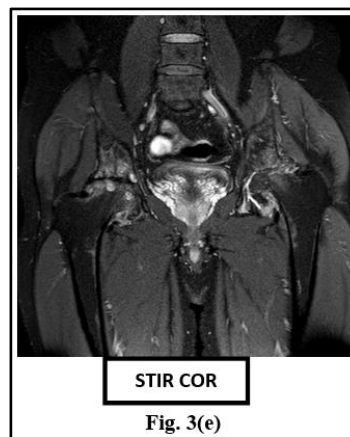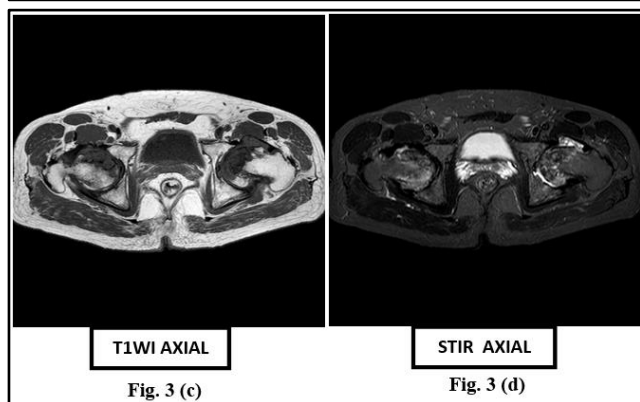
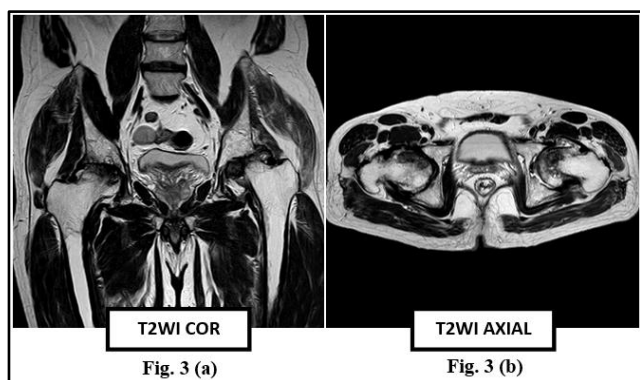


Fig. 3(e)

Figure 3 (a-e). Bilateral Avascular Necrosis with Osteoarthritis: Axial, and coronal images show abnormal marrow signals involving heads of bilateral femora appearing hypointense on T1 and hyper intense on STIR sequence associated with subarticular collapse. There is associated irregularity of articular surfaces of bilateral acetabula. These findings are suggestive of changes of stage V bilateral AVN with osteoarthritis.

DISCUSSION

Avascular Necrosis- MRI is a highly sensitive modality for diagnosing AVN. In our study, avascular necrosis (AVN) turned out to be the most common hip pathology (40%) with age varying from 6 years to 69 years and a male:female ratio of 3.7:1. The most common age group is 31-40 years which comprised 39% of the cases followed by 27% in 41-50 and 12% in 21-30 years age group. AVN usually occurs in patients in the third to fifth decade's unless predisposing conditions exist that place different age groups at risk i.e., LCP and slipped capital femoral epiphysis. In a study by Jacobs et al reported age range of patient was 15 to 83 years with majority were less than 50 years.³ Similarly, in our study the mean age of AVN presentation was 34.5 years in concordance with study of Khanna et al.⁴

In present study 79% patients were male and 21% were female; Patterson et al in their study on AVN had 83% male and 17% female patients.⁵ Majority of patients presented with hip joint pain (95%) followed by restricted movement in (89%) and gait abnormality in(79%) of patients.

Risk Factors	Present study		Jacobs et al % (n=269)
	No. of Patients (n=33)	% of Patients	
Alcohol	8	25	39
Steroid	4	12	27.8
Trauma	4	12	---
Sickle cell anaemia	2	6	3
Pancreatitis	2	6	4
PLHA	3	9	--
OCP	1	3	--
Hemosiderosis	1	3	--

Perthes disease	1	3	--
Idiopathic	8	24	--
Table 7			

We had three patients in our study who were HIV positive and diagnosed having AVN of femoral head, two of them were on HAART. Kirk D. Miller et al⁶ documented an extraordinarily and unexpectedly high occurrence of osteonecrosis of the hip in HIV infected patients (4.4%).

Clinical Presentation

In present study painful hip was the most common presenting symptom in 95% followed by restricted movement - 89% and gait abnormality-79% which is in concordance with the study of Stainberg et al⁷ who concluded that 77% of patients of AVN are having pain as the chief complaint.

Present Study (n=33)		Patterson et al % (n=52)
Bilateral AVN	% of Bilateral AVN	
21	63%	64
Table 8. Side Distribution		

One hip was affected by Perthes disease. In present study bilateral AVN was present in 21 patients (63%). So, this study matches with results of study of Patterson et al,⁵ bilateral (64%) however bilateral AVN may not match in their class, so AVN is either progressing with a different speed in either hips or it might have been started early in one hip.

Bone Marrow Oedema

In present study bone marrow oedema was found in 40 (74%) of the lesions. All patients having bone marrow oedema have pain. Koo K H, et al⁸ in a study concluded that combination of AVN femoral head and bone marrow oedema is strongly associated with pain. Guo-Shu Huang, et al⁹ concluded that the peak of bone marrow oedema occurred in stage III disease (72%); Kim et al¹⁰ reported that bone marrow oedema was most often found in hips with stage III disease (88%).

Secondary Osteoarthritic Changes

Secondary osteoarthritic changes include narrowing of joint space, osteophytes formation and subchondral cysts. Narrowing of joint space and subchondral cyst formation was better detected on MRI than on radiographs due to its multiplanar capacity and better resolution. In the present study most common changes of osteoarthritis is joint space reduction noted in 33% of hips studied.

Septic Arthritis

Septic arthritis is a common disease. Any delay in diagnosis of septic arthritis may increase morbidity and lead to complications such as bone and cartilage destruction, osteonecrosis, secondary osteoarthritis, osteomyelitis, and

eventually ankyloses.⁹ Some patients may present with subtle findings and have inconclusive findings of laboratory studies. Moreover, no single test has shown itself to be of sufficient diagnostic accuracy to serve as a definitive test for musculoskeletal infection. MRI has been increasingly used to evaluate musculoskeletal infections¹¹ because it is useful for evaluating bone marrow, soft tissues and joints. MRI findings in patients with septic joints have been described as abnormal as early as 24 hr after the onset of infection. The sensitivity and specificity of gadopentetate dimeglumine-enhanced MRI with fat suppression were found to be 100% and 77%, respectively, for the detection of septic arthritis.¹² Synovial enhancement and the presence of a joint effusion have been reported to have the highest correlation with the clinical diagnosis of a septic joint. Patients with tuberculous arthritis may have more bone erosions and less marrow-signal abnormality on MRI than patients with pyogenic arthritis. Tuberculous arthritis usually presents as mono-arthritis and is predominantly a synovial disease, with synovitis and effusion being the common features. Hypo-intense synovium on T2W images suggestive of granuloma, is a distinguishing feature, which along with central erosions, bone chips and rim enhancing abscesses, may differentiate tuberculous arthritis from other mono-articular inflammatory (JRA, RA, PVNS, HP) and infective arthritis (septic arthritis).

Bone erosion are more common in patients with tuberculous arthritis than in those with pyogenic arthritis, while subchondral marrow signal intensity abnormality are seen more frequently in patients with pyogenic arthritis than in those with tuberculous arthritis. On T2-weighted images, there is no significant difference between the synovial lesion signal intensities of tuberculous arthritis and pyogenic arthritis.

This investigation had significant limitations, including the small sample size and lack of true MRI criteria for synovial thickening. There was also significant population bias as to which patients were imaged and at what time over the course of their disease.

Accepting these limitations, we conclude that synovial enhancement and joint effusions had the highest correlation with the clinical diagnosis of septic joint.

Stress Fractures

Fractures produce an immediate change in the appearance of marrow, which is easily identified at MR imaging. Stress fractures occur commonly around the hips and in the pelvis. We had studied two patients with stress fractures both of them are middle aged females; one had bilateral affection. All the three lesions are classically linear low signal surrounded by bone marrow oedema and involves medial cortex of femoral neck.

Femoral Neck Fractures

On T2-weighted and STIR images, the low-signal-intensity line is surrounded by a variable amount of high-signal-intensity marrow oedema. We studied three patients of occult femoral neck fracture which were not seen on X-rays

and were diagnosed on MRI on the basis of hypointense fracture line and surrounding bone marrow oedema.

Primary Musculoskeletal Neoplasms

MR imaging depicts pathologic cellular tumours as low signal intensity on T1-weighted images, similar to that of muscle, and as high signal intensity on T2-weighted images, generally equal to or greater than that of fat. Fibrotic areas are low in signal intensity on both T1- and T2-weighted images, and fat within a tumor always has signal intensity equal to that of subcutaneous fat. We studied 10 patients of primary musculoskeletal neoplasm with reasonable accuracy.

Limitations of MRI

- Limited availability, high cost.
- MRI cannot be performed in patients with cardiac pacemakers, intracranial clips and claustrophobia.
- Problems related to mispositioning can lead to misrepresentation.
- Children may require sedation due to long imaging times.
- Detection after surgery to repair a hip fracture may be difficult because of the orthopaedic hardware, which creates significant image distortion.

CONCLUSION

MRI is an excellent modality in diagnosis, staging, deciding the extent, severity and complications and predicting prognosis of AVN of the femoral head being far superior to radiography in all terms (except the cost and when prosthesis causing contradiction for MRI hip). It showed exquisite sensitivity in detecting bone marrow oedema, cartilage, labrum, synovium, joint effusion, necrosis as well as extension of the tumours. Sometimes even in patients with reaction to iodinated contrast media in whom CT is contraindicated, MRI proves invaluable. Since joint preserving measures have much better scope when diagnosis of AVN is made early in the course of disease & since result of joint replacement therapy are poorer in young age groups, diagnosis of AVN as early as possible is critical to prevent or delay progression of disease & MR being

imaging modality earliest to diagnose AVN is thus a hip joint saving imaging modality.

REFERENCES

- [1] Stoica Z, Dumitrescu D, Popescu M, et al. Imaging of avascular necrosis of femoral head: familiar methods and newer trends. *Curr Health Sci J* 2009;35(1):23-28.
- [2] Verbeeten KM, Hermann KL, Hasselqvist M, et al. The advantages of MRI in the detection of occult hip fractures. *Eur Radiol* 2007;15(1):165-169.
- [3] Jacobs B. Epidemiology of traumatic and nontraumatic osteonecrosis. *Clin Orthop Relat Res* 1978;130:51-67.
- [4] Khanna A, Yoon TR, Mont MA, et al. Femoral head osteonecrosis: detection and grading by using a rapid MR imaging protocol. *Radiology* 2000;217(1):188-192.
- [5] Patterson RJ, Bickel WH, Dahlin DC. Idiopathic avascular necrosis of the head of the femur. A study of fifty two cases. *J Bone Joint Surg Am* 1964;46:267-282.
- [6] Miller KD, Masur H, Jones EC, et al. High prevalence of osteonecrosis of the femoral head in HIV infected adults. *Ann Intern Med* 2002;137(1):17-25.
- [7] Steinberg ME, Hayken GD, Steinberg DR. A quantitative system for staging avascular necrosis. *J Bone Joint Surg Br* 1995;77(1):34-41.
- [8] Koo KH, Ahn IO, Kim R, et al. Bone marrow edema and associated pain in early stage osteonecrosis of the femoral head: prospective study with serial MR images. *Radiology* 1999;213(3):715-722.
- [9] Huang GS, Chan WP, Chang YC, et al. MR imaging of bone marrow edema and joint effusion in patients with osteonecrosis of the femoral head: relationship to pain. *AJR* 2003;181(2):545-549.
- [10] Kim YM, Oh HC, Kim HJ. The pattern of bone marrow oedema on MRI in osteonecrosis of the femoral head. *J Bone Joint Surg Br* 2000;82(6):837-841.
- [11] Mitchell M, Howard B, Haller J, et al. Septic arthritis. *Radiol Clin North Am* 1988;26:1295-1313.
- [12] Hopkins KL, Li KC, Bergman G. Gadolinium-DTPA-enhanced magnetic resonance imaging of musculoskeletal infectious processes. *Skeletal Radiol* 1995;24(5):325-330.