

Tips and Tricks for Surgical Management of Opacified IOL

Mahesha Sarpangala¹, Vidya Sastry², Shwetha Suryakanth³

¹Consultant, Department of Cataract, Sankara Eye Hospital, Shimoga, Karnataka. ²Cataract Fellow, Department of Cataract, Sankara Eye Hospital, Shimoga, Karnataka. ³DNB Student, Department of Ophthalmology, Sankara Eye Hospital, Shimoga, Karnataka.

INTRODUCTION

The opacification of hydrophilic acrylic IOLs is a serious complication of unknown etiology, with the only effective treatment being lens explantation and replacement, preferably with a lens of some different material.¹ IOL exchange for opacified lens can be difficult and challenging. Surgery may not always go on according to the pre-operative plan and the surgeon must be ready with an alternative during surgery. We present a series of cases of IOL opacification that posed challenges in diagnosis and the various surgical management techniques.

Corresponding Author:

*Dr. Mahesha S,
Sankara Eye Hospital,
Thirthahalli Road, Harakere,
Shimoga- 577202, Karnataka.
E-mail: maheshbhat@sankaraeye.com
DOI: 10.18410/jebmh/2019/690*

*Financial or Other Competing Interests:
None.*

PRESENTATION OF CASE

CASE 1

66 year old lady presented to our outreach camp with complaints of defective vision in left eye since 4-5 months. At the campsite, she didn't give any history of surgery. On torch light examination, she was found to have dense lenticular opacity in her left eye and a diagnosis of black cataract in left eye was made. She was selected for cataract surgery and brought to the base hospital. At the base hospital, her visual acuity in the left eye was 4/60 not improving with pinhole. Slit lamp examination showed presence of posterior chamber intraocular lens with anterior capsular phimosis and opacification of the IOL. At this juncture, on further enquiry, the patient reported history of cataract surgery few years earlier. She could not remember any details of the surgery or post-operative period.

How to Cite This Article:

*Sarpangala M, Sastry V, Suryakanth S.
Tips and tricks for surgical management
of opacified IOL. J. Evid. Based Med.
Healthc. 2019; 6(52), 3297-3300. DOI:
10.18410/jebmh/2019/690*

*Submission 04-12-2019,
Peer Review 06-12-2019,
Acceptance 16-12-2019,
Published 30-12-2019.*



Management

IOL exchange in the left eye was planned after optical biometry and counseling. During surgery the IOL was found to be adherent to the bag with extensive fibrosis of the capsule to the IOL. Hence the IOL was removed along with capsular bag. Automated anterior Vitrectomy was done and iris claw lens implantation was done. The IOL removed was found to be an Acrylic lens with closed loop haptic. The best corrected visual acuity was 6/12 at the first post-operative visit.

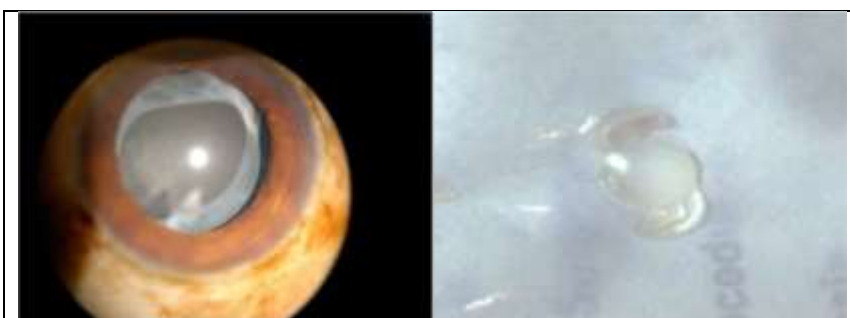


Image 1. Dilated Examination Showing the Capsulorrhexis Margin and the Opacified IOL, and Explanted IOL

CASE 2

64-year-old lady presented with defective vision in her right eye since 5 months. She gave history of cataract surgery in her right eye 1 year earlier, with good visual recovery. She could perceive light with accurate projection of rays in her right eye. On undilated examination, the appearance was that of a mature cataract. On dilatation the capsulorrhexis margin was seen with an opacified IOL above the capsule.

Management

IOL exchange was advised. During surgery the IOL was found to be in the sulcus. It was explanted without disturbing the bag and a rigid PMMA IOL was placed in the sulcus. Thus explanting an IOL from the sulcus and careful implantation of the new lens in the sulcus can prevent damage to the capsular bag. The explanted IOL was found to be foldable lens, probably made from hydrophilic Acrylic material. Her BCVA after IOL exchange improved to 6/12.



Image 2. Opacified IOL and the Explanted Acrylic Lens

CASE 3

61 year old male presented with history of decreased vision in left eye since 1 year. He gave a past history of surgery in left eye 3 years back. The best corrected visual acuity (BCVA) in the left eye was 6/18. On examination opacification of the IOL was observed in his left eye.

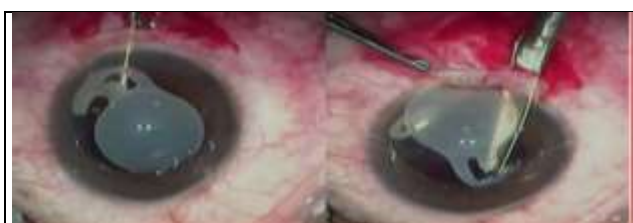

Image 3. Surgical Image Showing Removal of the Optic and Retaining the Haptics within the Capsular Bag

Management

Patient was advised to undergo IOL exchange. Temporal sclero-corneal tunnel was made and the IOL was mobilized under visco-elastic substance. During the rotation of the lens one haptic was freely mobile as it was in the sulcus but the other haptic was in the bag and was firmly adherent to the capsule. Attempts to pull the Haptic was causing zonular stress. Hence one of the haptics and optic was removed with IOL cutting scissors and one haptic was left inside the capsular bag. A single piece PMMA lens was implanted in the sulcus. The lens removed from the eye was a single piece foldable IOL. The patient recovered well from the surgery with post-operative best corrected visual acuity (BCVA) of 6/9.

CASE 4

73 year old male, came with the history of blurring of vision in right eye since 4 months. He gave a past history of surgery in right eye two years back. The best corrected visual acuity in his right eye was 6/18. Anterior segment evaluation showed an opacified intraocular lens and YAG capsulotomy opening in the posterior capsule.

Management

Lens exchange was planned and patient was counseled accordingly. During surgery the IOL was mobilized and one of the haptics was dialed out into the anterior chamber. However, the other haptic being adherent to the capsular bag could not be mobilized into the anterior chamber. McPherson forceps was used to hold the optic and the other haptic was cut with IOL cutting scissors. Surgeon noticed a large YAG capsulotomy opening in the posterior capsule without any vitreous disturbance. Hence a rigid IOL was placed in the sulcus instead of a foldable lens in the bag. Post operatively the patient had a best corrected visual acuity of 6/9.



Image 4. Haptic Dialed into Anterior Chamber and Removal of One Haptic and Optic from the Eye

PATHOLOGICAL DISCUSSION

The opacification of an IOL is a potential complication of cataract surgery. One major cause of lens opacification can be calcification of the lens² The formation of calcium deposits consisting of calcium phosphate salt may be attributed to the fact that aqueous humor is supersaturated with calcium crystalline. Calcification may be on the outer surface or in the inner part of the IOL.³ Though all types of IOL can undergo opacification, Hydrophilic Acrylic IOLs are commonly known to opacify due to deposition of Calcium phosphate crystals on the optic.⁴ Hydrophobic Acrylic IOLs are known to opacify, called glistening due to the formation of small fluid-filled vacuoles within the optic of the IOL.

Silicone IOLs are known to undergo brownish discoloration due to scattering of light from a layer of water vapour within the IOL that may have diffused into the Silicone material.⁵ Asteroid hyalosis is a common association with opacification of IOL, especially in patients with silicone lens.^{6,7} However in silicone IOL, calcium deposits accumulate on the posterior IOL surface and are amenable to removal by Nd: YAG laser treatment. Moussa et al.⁸ introduced a technique of manual removal of calcium deposits from the posterior surface of silicone IOL using a nickel-titanium loop. Opacification of IOLs occur due to patient associated causes like asteroid hyalosis, uveitis; the manufacturing process &

the method of IOL storage; surgical technique and adjuvants, or a combination of these factors.⁹

IOL explantation and exchange is technically difficult procedure associated with complications like corneal endothelial cell loss, aggravation of refractive error, zonular dehiscence, IOL tilting, and decentration.¹⁰⁻¹²

DISCUSSION OF MANAGEMENT

Case 1- IOL Fibrosed within the Capsular Bag

In our first case we removed the lens with the bag due to total fibrosis of the lens with the capsule and implanted an iris claw lens after anterior vitrectomy. IOL exchange surgery is associated with various complications. Yu et al. reported posterior capsule ruptures (13%) and zonular dehiscence (20%) in a series of explantations of opacified Hydroview IOLs.¹³

Case 2- IOL in the Sulcus

In the second case, the opacified IOL in the sulcus was explanted in toto without disturbing the bag and replaced with IOL in sulcus, as the anterior capsule had already fused with the posterior capsule. Several studies report that IOL implantations within the capsular bag and within the ciliary sulcus were found equally effective and safe in a 5-year follow-up period.¹⁴⁻¹⁶

Case 3- Haptics of IOL Adherent to the Capsular Bag

In the third case scenarios, one of the haptics were left behind in the capsular bag and a PMMA IOL was implanted in sulcus.

Case 4- One Haptic Adherent to the Capsule with Previous YAG Capsulotomy Opening in the Posterior Capsule

The fourth case had a fibrosed haptic within the capsular bag, and hence optic and one haptic was removed. However, there was a large opening in the posterior capsule which made the surgeon decide to plan a rigid IOL in the sulcus instead of a foldable IOL within the bag.

Lee et al¹⁷ reported a new technique in which the intraocular opacified lens was exchanged with removal of the optic only to avoid zonular dehiscence. One or both haptics were left in the capsule and new foldable IOLs were implanted into the bag (39%) or into the ciliary sulcus (57%) and zonular dehiscence developed in 4% of eyes. They observed no complication associated with haptic dislocation with the positioning of a newly implanted IOL. We followed a similar technique in our surgery. IOL opacification is often a missed or misdiagnosed entity that puts the patient into lot of unnecessary treatments like repeated YAG capsulotomies thinking it to be posterior capsular opacity and even vitrectomy mistaking it as unresolving vitreous hemorrhage. Hence detailed evaluation and timely surgical intervention can help in giving better visual outcomes to the patients.

REFERENCES

- [1] Neuhann IM, Neuhann TF, Szurman P, et al. Clinicopathological correlation of 3 patterns of calcification in a hydrophilic acrylic intraocular lens. *J Cataract Refract Surg* 2009;35(3):593-597.
- [2] Gartaganis SP, Kanellopoulou DG, Mela EK, et al. Opacification of hydrophilic acrylic intraocular lens attributable to calcification: investigation on mechanism *Am J Ophthalmol* 2008;146(3):395-403.
- [3] Choi SM, Yang WK, Yoo YW, et al. Effect of surface modification on the in vitro calcium phosphate growth on the surface of poly(methyl methacrylate) and bioactivity. *Colloids Surf B Biointerfaces* 2010;76(1):326-333.
- [4] Ronge LJ. Opacification of IOLs: a problem often misdiagnosed? <http://www.aao.org/publications/eyenet/200509/cataract.cfm>.
- [5] Goodall KL, Ghosh YK. Total opacification of intraocular lens implant after uncomplicated cataract surgery: a case series. *Arch Ophthalmol* 2004;122(5):782-284.
- [6] Foot L, Werner L, Gills JP, et al. Surface calcification of silicone plate intraocular lenses in patients with asteroid hyalosis. *Am J Ophthalmol* 2004;137(6):979-987.
- [7] Matsumura K, Takano M, Shimizu K, et al. Silicone intraocular lens surface calcification in a patient with asteroid hyalosis. *Jpn J Ophthalmol* 2012;56(4):319-323.
- [8] Moussa K, Leng T, Oatts JT, et al. Manual removal of intraocular lens silicone oil droplets and dystrophic calcifications using a nitinol loop: a case series. *Ophthalmic Surg Lasers Imaging Retina* 2017;48(5):422-426.
- [9] Werner L. Causes of intraocular lens opacification or discoloration *J Cataract Refract Surg* 2007;33(4):713-726.
- [10] Mamalis N, Brubaker J, Davis D, et al. Complications of foldable intraocular lenses requiring explantation or secondary intervention--2007 survey update. *J Cataract Refract Surg* 2008;34(9):1584-1591.
- [11] Oh SY, Lee SJ, Park JM. Comparison of surgical outcomes of intraocular lens refixation and intraocular lens exchange with perfluorocarbon liquid and fibrin glue-assisted sutureless scleral fixation. *Eye (Lond)* 2015;29(6):757-763.
- [12] Fernández-Buenaga R, Alió JL, Pinilla-Cortés L, et al. Perioperative complications and clinical outcomes of intraocular lens exchange in patients with opacified lenses. *Graefes Arch Clin Exp Ophthalmol* 2013;251(9):2141-2146.
- [13] Yu AKF, Ng AS. Complications and clinical outcomes of intraocular lens exchange in patients with calcified hydrogel lenses. *J Cataract Refract Surg* 2002;28(7):1217-1222.
- [14] Gashau AG, Anand A, Chawdhary S. Hydrophilic acrylic intraocular lens exchange: five-year experience. *J Cataract Refract Surg* 2006;32(8):1340-1344.

- [15] Leysen I, Bartholomeeusen E, Coeckelbergh T, et al. Surgical outcomes of intraocular lens exchange: five-year study. *J Cataract Refract Surg* 2009;35(6):1013-1018.
- [16] Marques FF, Marques DM, Osher RH, et al. Longitudinal study of intraocular lens exchange. *J Cataract Refract Surg* 2007;33(2):254-257.
- [17] Lee SJ, Sun HJ, Choi KS, et al. Intraocular lens exchange with removal of the optic only. *J Cataract Refract Surg* 2009;35(3):514-518.