

Study of Clinical Findings and Treatment Outcomes of Rhino-Orbital-Cerebral Mucormycosis at a Tertiary Care Center in Central India

Kavita Anand Dhabarde¹, Pallavi Madhusudan Doble², Nehali Sureshchandra Pant³, Nisha Vilas Rahul⁴

^{1, 2, 3, 4} Department of Ophthalmology, Government Medical College, Nagpur, Maharashtra, India.

ABSTRACT

BACKGROUND

Mucormycosis is a potentially lethal angioinvasive fungal infection. Increasing incidence of rhino-orbital-cerebral mucormycosis in setting of corona virus disease-19 (COVID-19) during second wave in India and elsewhere has become a matter of immediate concern. This study was done to assess the clinical findings and treatment outcomes of rhino-orbital-cerebral-mucormycosis presenting to a tertiary care center in central India.

METHODS

This is a longitudinal study. We observed 38 COVID-19 associated mucormycosis cases. Their demographic data, clinical manifestations, underlying systemic conditions, microbiological and radiological reports, medical treatments and surgical interventions were recorded and analysed.

RESULTS

Common ocular presenting features were ophthalmoplegia (68 %), proptosis (44 %), periorbital swelling (13 %), diminution of vision (37 %), central retinal arterial occlusion (2.5 %), optic atrophy (2.5 %). Visual acuity at 1 month after surgery was compared with that at presentation and was found unchanged in 27 patients, improved in 3 patients and deteriorated in 6 patients. Functional outcome was evaluated in terms of ocular movements, and it was found that ocular movements were same as presentation in 30 patients, improved in 3 patients and deteriorated in 3 patients at follow up one month after surgery. Radiological outcome was evaluated, and it was found that residual disease was present in 4 patients and absent in 32 patients. Mortality was found in 2 patients at 1 month follow-up period.

CONCLUSIONS

Early diagnosis, blood sugar levels control, urgent systemic antifungal therapy and sinus debridement surgery are lifesaving in cases of COVID-19 associated mucormycosis.

KEYWORDS

Mucormycosis, COVID-19, Diabetes Mellitus, Ophthalmoplegia, Orbital Apex Syndrome, Orbital Cellulitis, Proptosis

Corresponding Author:

Dr. Pallavi Madhusudan Doble,
C/o. Madhusudan Dolbe, Ward No. 16,
Behind Bus-stop, Near APMC, Karanja
(Ghadge), District Wardha-442203,
Maharashtra, India.
E-mail: pallavidoble23@gmail.com

DOI: 10.18410/jebmh/2021/628

How to Cite This Article:

Dhabarde KA, Doble PM, Pant NS, et al.
Study of clinical findings and treatment
outcomes of rhino-orbital-cerebral
mucormycosis at a tertiary care center in
Central India. J Evid Based Med Healthc
2021;8(40):3464-3469. DOI:
10.18410/jebmh/2021/628

Submission 26-08-2021,
Peer Review 03-09-2021,
Acceptance 26-09-2021,
Published 04-10-2021.

Copyright © 2021 Kavita Anand
Dhabarde et al. This is an open access
article distributed under Creative
Commons Attribution License
[Attribution 4.0 International (CC BY
4.0)]

BACKGROUND

Mucormycosis is an acute, fulminating, often fatal fungal infection caused by fungi of family Mucoraceae and is seen in diabetic and immunocompromised patients.^{1,2} Mucormycosis is categorized as rhino-orbital-cerebral, pulmonary, cutaneous, gastrointestinal, or disseminated, depending upon organ involvement; the most common form is rhino-orbital-cerebral. The incidence of mucormycosis has rapidly increased in the setting of COVID 19 and has become the matter of immediate concern. The fungal hyphae of Mucoraceae family are angioinvasive, invades blood vessels, causes necrotizing vasculitis and thrombosis resulting in extensive tissue infarcts and necrosis.³ The disease usually starts in the nose and sinuses after inhalation of fungal spores. It proliferates and spreads to the paranasal sinuses (sino-nasal mucormycosis), and then to the orbit by direct extension or through hematogenous route (sino-orbital mucormycosis). It can also spread to the brain (sino-orbital-cerebral mucormycosis). Although primary site of inoculation is nose and paranasal sinuses, the patients usually initially present to the ophthalmologists with ocular signs and symptoms.⁴ Diabetes mellitus, use of corticosteroids, broad spectrum antibiotics and other immunosuppressive agents for treatment of moderate to severe cases of COVID-19, excessive stress of infection, long term O₂ therapy, inability to maintain nasal and oral hygiene during the course of treatment are some of the risk factors suspected to contribute to COVID associated rhino-orbital-cerebral mucormycosis.^{5,6,7}

Systemic amphotericin B with surgical debridement of sinuses and control of systemic conditions remains the mainstay of treatment.^{8,9,10,11} In this study, we have observed and evaluated clinical characteristics and treatment outcomes of 38 cases of COVID associated rhino-orbital-cerebral mucormycosis.

Objectives

Primary Objective

To study clinical findings and treatment outcomes of rhino-orbital-cerebral mucormycosis.

Secondary Objective

To compare treatment outcomes of rhino-orbital-mucormycosis with computed tomography (CT) severity score.

METHODS

A longitudinal study of thirty-eight cases of COVID-19 associated rhino-orbital-cerebral mucormycosis presenting to tertiary care center in central India from 1st May 2021 to 31st May 2021 was performed. Their clinical presentations, laboratory investigations and treatment received were analyzed. Comprehensive workup at presentation included detailed history regarding COVID treatment, comprehensive ocular examination (visual acuity, anterior segment evaluation, posterior segment evaluation, ocular

movements), otorhinolaryngological and neurological examination to assess the severity of the disease. Depending upon CT severity score (CTSS) during the course of COVID 19 disease, patients were categorized into mild (CTSS < 8), moderate (CTSS - 8 - 15), and severe cases (CTSS >15).

Diagnosis of mucormycosis was made on the basis of CT scan/magnetic resonance imaging (MRI) of paranasal sinuses, orbit and brain [Figure 2(d)], demonstration of fungal hyphae on KOH preparations, lactophenol cotton blue staining and PAS staining [Figure 2 (a, b, c)] of specimens obtained from nasal cavity and paranasal sinuses. Mucormycosis was defined by clinico-radiological suspicion with visualisation of broad branched aseptate fungal hyphae on KOH mount direct microscopy and histopathology specimen by fungal stains. All patients received intravenous amphotericin B as soon as diagnosis of mucormycosis was done in a dose of 1 mg/kg/day. Renal functions were monitored. Diabetes was controlled with insulin therapy. Trans-nasal endoscopic radical debridement of involved sinuses was done in all patients and specimen was obtained and sent for histopathology and culture. Endoscopic debridement of sinuses along with orbital decompression and orbital exenteration was done depending upon the involvement of sinuses and orbit in radiological reports.

Patients were followed up for a period of 1 month. Treatment outcome was measured in terms of visual, functional, radiological outcome and mortality at 1 month post-operatively. Visual outcome was evaluated in terms of unchanged, improved or deteriorated visual acuity as compared to that at presentation. Functional outcome was evaluated in terms of unchanged, improved or deteriorated ocular movements as compared to that at presentation. Radiological outcome was evaluated in terms of presence or absence of residual disease.

Statistical Analysis

Statistical analysis was done using chi-square test to assess association between treatment outcome of COVID-19 associated mucormycosis and severity of COVID-19 disease based on CT severity score. Visual outcome, functional outcome and radiological outcomes were compared with CT severity scores of the patients (during the course of COVID-19 disease).

RESULTS

There were 38 patients in total which included 28 male and 10 females with mean age of 49.3 years (range 21 to 73 years). Lag time between the onset of symptoms and presentation was 2 to 15 days. 27 patients (71 %) had type 2 diabetes mellitus of which 10 were recently diagnosed with diabetes mellitus (37 %) and 17 patients were known cases of diabetes with duration of diabetes ranging from 3 years to 10 years, out of which 3 patients were on irregular medications. 15 patients (40 %) were known cases of systemic hypertension and were receiving anti-hypertensive treatment. 1 patient was human immunodeficiency virus

(HIV) positive receiving anti-retroviral therapy, 1 patient was HBsAg positive. Of the 38 patients, 30 patients (78.9 %) were given systemic steroid as a part of treatment for COVID 19 disease. Out of these 30 patients, 23 patients (77 %) received injectable intra-venous methylprednisolone for a period ranging from 5 to 15 days, 7 patients (23 %) received oral prednisolone. Oxygen therapy was given to 16 patients (42 %) during hospital stay as a part of COVID-19 treatment. Injection remdesivir was given to 16 patients (42 %) as a part of COVID-19 management. Based on CT severity score, 16 mild cases, 15 moderate cases and 7 severe cases of COVID 19 infection were noted. Common ocular presenting features were ophthalmoplegia 26 cases (68 %), proptosis 17 cases (44 %), orbital cellulitis 5 cases (13 %), diminution of vision 14 cases (37 %), central retinal arterial occlusion 1 case (2.5 %), optic atrophy 1 case (2.5 %) [Table 1]. Photographs of clinical presentations of two patients, one with ophthalmoplegia and other with orbital cellulitis are shown in figure 1.

Sex	Male, n (%)	28 (74 %)
	Female	10 (26 %)
	Age (in years) mean (range)	49.3 (21-73)
	Diabetes mellitus, n (%)	27 (71 %)
	Hypertension, n (%)	15 (40 %)
	HIV infection n (%)	1 (2.5 %)
	HBsAg infection n (%)	1 (2.5 %)
	Systemic corticosteroids for COVID 19 management n (%)	30 (79 %)
	Oxygen therapy for COVID-19 management n (%)	16 (42 %)
	Inj. Remdesivir for COVID-19 management n (%)	16 (42 %)
	COVID 19 Severity (CTSS)	
	Mild (< 8) n (%)	16 (42 %)
	Moderate (8 - 15) n (%)	15 (40 %)
	Severe (> 15) n (%)	7 (18 %)
Clinical presentation	Ophthalmoplegia n (%)	26 (68 %)
	Proptosis n (%)	17 (44 %)
	Diminution of vision n (%)	14 (37 %)
	Orbital cellulitis n (%)	5 (13 %)
	Central retinal arterial occlusion, n (%)	1 (2.5 %)
	Optic atrophy, n (%)	1 (2.5 %)
	Cerebral involvement n (%)	4 (10.5 %)

Table 1. Epidemiology, Risk Factors and Clinical Presentations

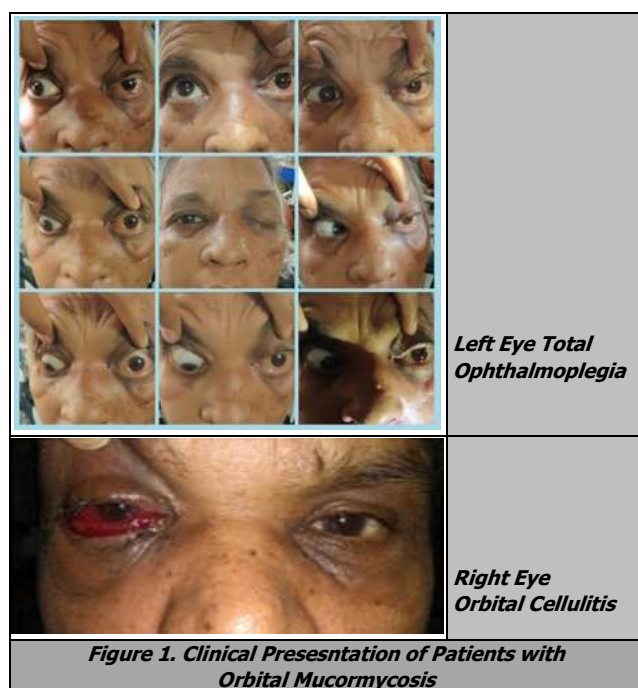

Figure 1. Clinical Presentation of Patients with Orbital Mucormycosis

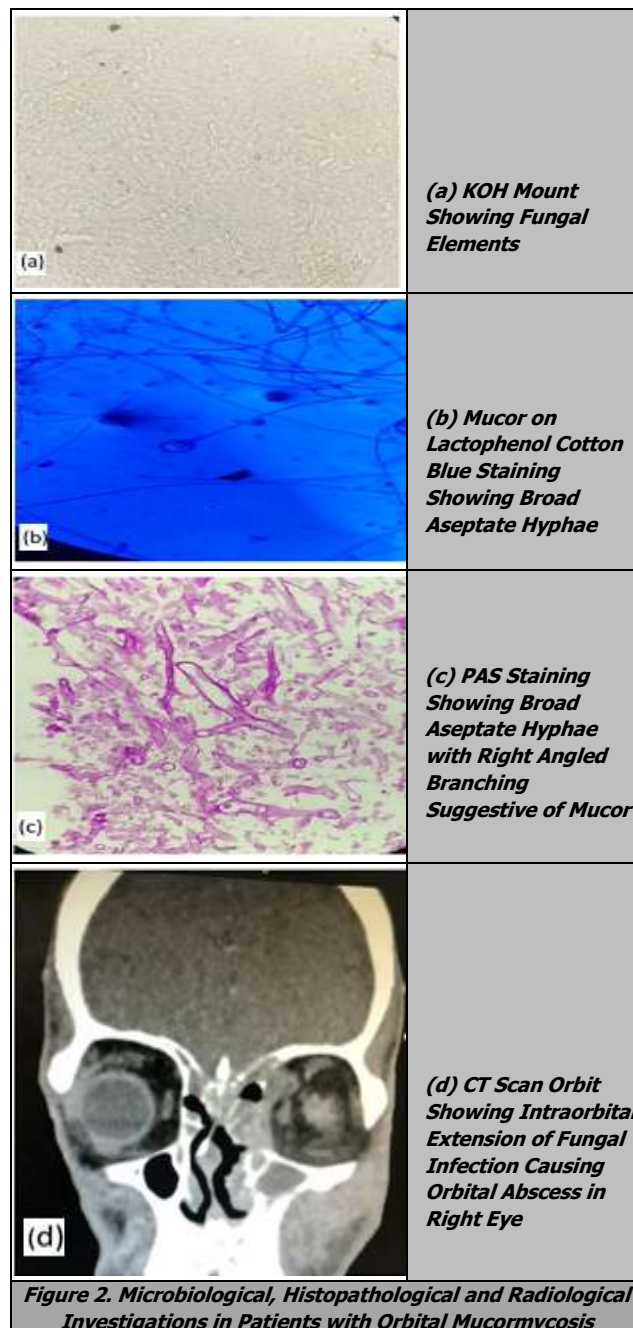


Figure 2. Microbiological, Histopathological and Radiological Investigations in Patients with Orbital Mucormycosis

Surgeries Performed	n (%)
Endoscopic debridement of sinuses	10 (26 %)
Endoscopic debridement of sinuses with maxillectomy with orbital decompression	25 (66 %)
Endoscopic debridement of sinuses with maxillectomy with orbital exenteration	3 (8 %)

Table 2. Management of Mucormycosis

Diagnosis of mucormycosis was made depending on microbiological, histopathological reports of clinical specimens obtained from nasal cavity and paranasal sinuses and CT scan/magnetic resonance imaging of paranasal sinuses, orbit and brain. Photographs of investigations are shown in figure 2. KOH mount showing fungal elements [figure 2a], lactophenol cotton blue staining showing broad aseptate hyphae which is suggestive of Mucor species [figure 2b], PAS staining showing broad aseptate hyphae with right angled branching suggestive of Mucor [figure 2c],

CT scan orbit showing intra-orbital extension of fungal infection causing orbital abscess [figure 2d].

Visual Outcome					χ ² = chi ² value = 17.3250 P = 0.002 (Highly significant)
CT Severity Score					
Mild (< 8) Moderate (8 - 15) Severe (16 - 25)					
Unchanged	27 (71 %)	14 (87.50 %)	12 (80.00 %)	1 (20 %)	
Improved	3 (7.9 %)	1 (6.25 %)	2 (13.33 %)	0	
Deteriorated	6 (15.8 %)	1 (6.25 %)	1 (6.25 %)	4 (80 %)	
Total	36	16	15	5	
Functional Outcome					χ ² = chi ² value = 20.74 P < 0.001 (Highly significant)
CT Severity Score					
Mild (< 8) Moderate (8 - 15) Severe (16 - 25)					
Unchanged	30 (78.9 %)	14 (87.50 %)	14 (93.33 %)	2 (40 %)	
Improved	3 (7.9 %)	2 (12.50 %)	1 (6.67 %)	0	
Deteriorated	3 (7.9 %)	0	0	3 (60 %)	
Total	36	16	15	5	
Radiological Outcome					χ ² = chi ² value = 8.0727 P = 0.018 (Significant)
CT Severity Score					
Mild (< 8) Moderate (8 - 15) Severe (16 - 25)					
No residual disease	32 (84.2 %)	16 (100 %)	14 (93.33 %)	3 (60 %)	
Residual disease present	4 (10.5 %)	0	1 (7.67 %)	2 (40 %)	
Total	36	16	15	5	

Table 3. Treatment Outcome and It's Correlation with CT Severity Score

All patients received intravenous amphotericin B in a dose of 1 mg/kg/day. Primary surgery was performed in all 38 patients (100 %). Secondary surgery was performed in 8 patients (21 %). Surgeries performed were endoscopic debridement of sinuses, endoscopic debridement with maxillectomy with orbital decompression, endoscopic debridement with orbital exenteration depending upon extent of disease [Table 2]. Visual acuity at 1 month after the surgery was compared with that at presentation and was found unchanged in 27 patients (71 %), improved in 3 patients (7.9 %) and deteriorated in 6 patients (15.8 %). Functional outcome was evaluated in terms of ocular movements at 1 month post-operatively with that at presentation and it was found that ocular movements were same as presentation in 30 patients (78.9 %), improved in 3 patients (7.9 %) and deteriorated in 3 patients (7.9 %). Radiological outcome was evaluated in terms of presence or absence of residual disease at 1 month after surgery and was found that residual disease was present in 4 patients (10 %) and absent in 32 patients (84.2 %). Mortality was found in 2 patients (5.2 %) at 1 month follow up period after the surgery [Table 5]. Patient's visual outcome, functional outcome and radiological outcome was corelated with CT severity score during the course of COVID-19 disease [Table3]. Statistical analysis was done using chi square test. When visual outcome was compared with CT severity score, it was found that, chi square value was 17.325, P value was 0.002, which was highly significant suggesting strong correlation between CT severity score and visual outcome i.e. visual outcome was poor in patients with high CTSS value while it was good in patients with low CT severity score value. The more was the CT severity score, a greater number of patients had deterioration of visual acuity. On comparing functional outcome with CT severity score, it was found that, chi square value was 20.74, P value being <

0.001, which was highly significant again suggesting strong correlation between CT severity score and functional outcome. Functional outcome was poor in patients with high CT severity score value while it was good in patients with low CTSS value. Radiological outcome comparison with CT severity score showed significant correlation with P value being 0.018.

DISCUSSION

Mucormycosis is an opportunistic, potentially lethal, angioinvasive fungal infection predisposed by uncontrolled diabetes mellitus, corticosteroids, immunosuppressive therapy, primary or secondary immunodeficiency. It can affect nose, sinus orbit, central nervous system (CNS), lung, gastrointestinal tract, skin, jaw bones, heart, kidney and mediastinum. Of these, rhino-orbital- cerebral mucormycosis is the most common presentation. Rhino-orbital mucormycosis is an aggressive opportunistic fungal infection of immuno-compromised debilitated patients. The ubiquitous naturally occurring fungus presents as a rhino-orbital-cerebral infection in those with weak innate immunity to fight the external invading pathogen. Complex interplay of multiple factors, including comorbidities, use of immunosuppressive therapy, risk of hospital-acquired infections and alteration of immune system by COVID-19, may be responsible for co-infections. There are specific pathophysiological features of COVID-19 that may predispose an individual to secondary fungal infections. First, there is immune dysregulation with reduced numbers of T lymphocytes, CD4+ T cells, CD8+ T cells, and markedly higher levels of interleukin (IL)-2 receptor, IL-6, IL-10 and tumour necrosis factor-alpha.

Thus, COVID-19 disease is associated with a significant incidence of secondary infections probably due to immune dysregulation. The incidence of rhino-orbital-cerebral mucormycosis has rapidly increased in the setting of second wave of COVID-19 pandemic. It appears to be the intersection of two crises: the one of COVID-19 and the other of poorly controlled blood sugar levels (either due to diabetes mellitus or steroid induced hyperglycaemia). Mucormycosis is considered as an emergency owing to the rapidly aggressive and invasive nature of fungus. Early recognition and prompt treatment is necessary. Physicians should be aware of the possibility of invasive secondary fungal infections in patients with pre-existing risk factors and should enable early diagnosis and treatment with subsequent reduction of morbidity and mortality. Microbiological diagnosis, control of underlying systemic condition, and antimicrobial therapy with debridement of necrotic tissue has remained the mainstay of management of rhino-orbital-cerebral mucormycosis over the years.

The infection begins with inhalation of spores into the oral and nasal cavity. In persons with an intact immune system, infection rarely develops because the fungal spores are phagocytosed by the macrophages. However, in individuals with uncontrolled diabetes mellitus and with immunocompromised status, infection develops as their immune system is weak. From here, infection spreads to

paranasal sinuses and orbit via ethmoid and maxillary sinuses or through the nasolacrimal duct resulting in orbital cellulitis. The infection may extend posteriorly to orbital apex, leading to orbital apex syndrome leading to severe vision loss. The fungus may gain access to the cavernous sinus and to the brain parenchyma through cribriform plate, orbital apex or orbital vessels causing threat to life. Histopathology, direct microscopy and culture from clinical specimen are major diagnostic modalities for mucormycosis.^{12,13}

Diagnosis of mucormycosis was made on the basis of CT scan/MRI of paranasal sinuses, orbit and brain [Figure 2(d)], demonstration of fungal hyphae on KOH preparations, lactophenol cotton blue staining and PAS staining [Figure 2 (a, b, c)] of specimens obtained from nasal cavity and paranasal sinuses. All patients received systemic antifungals (Amphotericin B), control of blood sugar levels and other systemic conditions was done. Primary surgery was performed in all 38 patients. Secondary surgery was performed in some patients as per requirement. Surgeries performed included endoscopic debridement of sinuses, orbital decompression, orbital exenteration depending upon involvement on Ct scan or MRI.

In our study of 38 patients of COVID-19 associated rhino-orbital mucormycosis, mean age of presentation was 49.3 years and males were more commonly affected 28 cases (74 %) than females 10 cases (26 %). Common ocular presentations were ophthalmoplegia (68 %), proptosis (44 %), diminution of vision (37 %), orbital cellulitis (13 %), central retinal arterial occlusion (2.5 %), optic atrophy (2.5 %). Cerebral involvement was seen in 4 patients (10.5 %). 27 patients (71 %) were having diabetes mellitus and 30 patients (79 %) received steroids as a part of COVID-19 management. 16 patients (42 %) had history of oxygen therapy, 16 patients (42 %) received Inj. remdesivir during COVID-19 management. 15 patients (40 %) had history of hypertension, while 1 patient (2.5 %) was HIV infected and was receiving anti-retroviral therapy. Thus, raised blood sugar levels either due to diabetes mellitus or steroid induced hyperglycaemia was the most common predisposing factor. Statistical analysis of our study showed highly significant correlation between CT severity score and visual and functional outcome, while significant correlation between CT severity score and radiological outcome. With increase in CT severity score of patients, there was deterioration of visual, functional and radiological outcome of COVID-19 associated mucormycosis.

Diagnosis of rhino-orbital-cerebral mucormycosis in early stages needs a high degree of suspicion. Diagnosis of mucormycosis was made from radiological findings, microbiological and histopathological reports. Surgical debridement of sinuses along with orbital decompression, orbital exenteration whenever necessary, systemic antifungals and treatment of systemic conditions remained the mainstay of treatment of rhino-orbital-cerebral mucormycosis. Antifungal therapy is a hallmark lifesaving intervention in mucormycosis and liposomal amphotericin B is the recommended first line drug. Posaconazole and isavuconazole are the salvage drugs in case of intolerance or poor general condition. Given the acute and aggressive

nature of mucormycosis, timely diagnosis and prompt antifungal therapy along with surgical debridement of sinuses is highly recommended in order to decrease the mortality.

CONCLUSIONS

Invasive rhino-orbital-cerebral mucormycosis is a severe fatal infection requiring multidisciplinary approach. Ophthalmoplegia, proptosis, decreased vision were the main clinical findings in our study. Timely and proper treatment by surgery and systemic antifungals could save the vision in majority of the patients. Early diagnosis, control of blood sugar levels, urgent systemic antifungal therapy and sinus debridement surgery are life-saving in cases of COVID-19 associated mucormycosis.

Limitations of the Study

We acknowledge the limitation of our study, which is short period of follow up. It is possible that patients may have recurrence of disease or mortality due to disease after a long follow-up period. Since, our follow-up period was only 1 month, the recurrence of disease and mortality rate after a long follow-up period could not be studied.

Declaration of Patient Consent

The authors certify that they have obtained all appropriate patient consent forms. In the form, patients have given their consent for their images and other clinical information to be reported in journal.

Data sharing statement provided by the authors is available with the full text of this article at jebmh.com.

Financial or other competing interests: None.

Disclosure forms provided by the authors are available with the full text of this article at jebmh.com.

We acknowledge Dr. R.S. Joshi (Professor and Head, Department of Ophthalmology, GMCH Nagpur) for permitting us to do the study. We are grateful to Dr. Suresh More (Statistician) for helping us in doing statistical analysis. We also express our gratitude to staff from Department of Otorhinolaryngology, Neurosurgery, Radiology, Microbiology and Pathology for helping us in doing the study. We also thank our patients who participated in the study.

REFERENCES

- [1] Yohai RA, Bullock JD, Aziz AA, et al. Survival factors in rhino-orbital-cerebral mucormycosis. *Surv Ophthalmol* 1994;39(1):3-22.
- [2] Uğurlu ŞK, Selim S, Kopar A, et al. Rhino-orbital mucormycosis: clinical findings and treatment outcomes of four cases. *Turk J Ophthalmol* 2015;45(4):169-174.
- [3] Kohn R, Hepler R. Management of limited rhino-orbital mucormycosis without exenteration. *Ophthalmology* 1985;92(10):1440-1444.

- [4] Ferry AP, Abedi S. Diagnosis and management of rhino-orbitocerebral mucormycosis (phycomycosis). A report of 16 personally observed cases. *Ophthalmology* 1983;90(9):1096-1104.
- [5] Mehta S, Pandey A. Rhino-orbital mucormycosis associated with COVID-19. *Cureus* 2020;12(9):e10726.
- [6] Singh AK, Singh R, Joshi SR, et al. Mucormycosis in COVID-19: a systematic review of cases reported worldwide and in India. *Diabetes Metab Syndr* 2021;15(4):102146.
- [7] Al-Tawfiq JA, Alhumaid S, Alshukairi AN, et al. COVID-19 and mucormycosis superinfection: the perfect storm. *Infection* 2021:1–21.
- [8] Skiada A, Lass-Floerl C, Klimko N, et al. Challenges in the diagnosis and treatment of mucormycosis. *Med Mycol* 2018;56(suppl 1):93-101.
- [9] Gupta S, Goyal R, Kaore NM. Rhino-Orbital-Cerebral mucormycosis: battle with the deadly enemy. *Indian J Otolaryngol Head Neck Surg* 2020;72(1):104-111.
- [10] Pilmis B, Alanio A, Lortholary O, et al. Recent advances in the understanding and management of mucormycosis. *F1000Res* 2018;7:F1000.
- [11] Sen M, Lahane S, Lahane TP, et al. Mucor in a viral land: a tale of two pathogens. *Indian J Ophthalmol* 2021;69(2):244-252.
- [12] Werthman-Ehrenreich A. Mucormycosis with orbital compartment syndrome in a patient with COVID-19. *Am J Emerg Med* 2021;42:264.e5-264.e8.
- [13] Mekonnen ZK, Ashraf DC, Jankowski T, et al. Acute Invasive rhino-orbital mucormycosis in a patient with covid-19-associated acute respiratory distress syndrome. *Ophthalmic Plast Reconstr Surg* 2021;37(2):e40-e80.