

CLINICAL STUDY OF MANAGEMENT OF INTRACAPSULAR FRACTURE NECK OF THE FEMUR IN ELDERLY WITH BIPOLAR HEMIARTHROPLASTY

P. Pavan Kumar¹, K. Ashok Naidu²

HOW TO CITE THIS ARTICLE:

P. Pavan Kumar, K. Ashok Naidu. "Clinical study of Management of Intracapsular Fracture neck of the femur in Elderly with Bipolar Hemiarthroplasty". Journal of Evidence based Medicine and Healthcare; Volume 2, Issue 11, March 16, 2015; Page: 1630-1643.

ABSTRACT: Hemiarthroplasty is a common treatment for fracture neck of femur in elderly patients. Unipolar hemiarthroplasty has shown good results, though there is high incidence of erosion, protrusion and needs revision in future. The concept of dual bearing surfaces results in sharing of motion at the two surfaces and hence reduction of net wears at either surface, thus reducing erosion at the acetabular-joint interface. From our relatively short term prospective non-randomized study, we conclude that bipolar hemiarthroplasty gives good results.

KEYWORDS: Hemiarthroplasty bipolar.

INTRODUCTION: Femoral neck fractures, recognized since the time of Hippocrates, still remain a vexing clinical problem for orthopaedic surgeons. The fracture neck of femur is one of the commonest fractures in elderly. With life expectancy increasing with each decade, our society is becoming increasingly an active geriatric society, with significant number of hospitalized and nursing home patients with femoral neck fractures and their sequelae. It has always presented great challenges to orthopedic surgeons and even today it remains an unsolved fracture as far as treatment is concerned.^[1] Intracapsular femoral neck fractures account for about 50% of all hip fractures. The lifetime risk of sustaining a hip fracture is high and lies within the range of 40% to 50% in women and 13% to 22% in men. Life expectancy is increasing worldwide, and these demographic changes can be expected to cause the number of hip fractures occurring worldwide to increase from 1.66 million in 1990 to 6.26 million in 2050.

Various methods of treatment have been employed since ages. The prolonged immobilization in elderly, will further lead to decubitus problems and associated complications, and hence surgery was resorted to achieve early ambulation. It is known fact that the hip is a weight bearing joint performing many functions. A successful surgery at the joint should provide painless, stable hip with wide range of movements.

Several authors have considered replacement of the femoral head as an alternative due to the frequent development of nonunion, failure of osteosynthesis and avascular necrosis of the femoral head.^[2,3]

Prosthetic replacement of femoral head with hemiarthroplasty has been the gold standard now in the management of intracapsular fracture neck of femur in geriatric patients. The advantages being early weight bearing to return to activity and help avoid complications of recumbency and inactivity, and avoiding complications of the fracture healing like nonunion and osteonecrosis. Selection of the type of prosthesis is very important in hemiarthroplasty as

ORIGINAL ARTICLE

different types are available. Although the fixed head endoprosthesis like Austin-Moore Prosthesis has produced excellent results^[4,5] persistent pain and protrusio acetabuli have been associated with this device and led many surgeons to choose a bipolar system. This prosthesis is very useful and results are encouraging.^[6] Since the last two decades, bipolar replacements of the femoral head have gained popularity for treating femoral neck fractures. These devices incorporated the principles of low-friction arthroplasty including fixation with polymethyl methacrylate. In this, the majority of motion is supposed to occur between the small inner metallic head and the ultrahigh molecular weight polyethylene socket. The polyethylene socket is bonded to an outer stainless steel shell and this shell articulates with the acetabulum. The lessening of motion at the outer metallic shell-acetabular interface reduces erosion and penetration of the acetabulum.

AIMS AND OBJECTIVES OF THE STUDY: To evaluate the results of bipolar hemiarthroplasty with respect to pain, range of motion, clinical functional outcome and complications in cases of Intra capsular fracture neck of the femur treated with bipolar hemiarthroplasty.

The subjects were patients admitted to Government General Hospital, Siddhartha Medical College, Vijayawada between 01-07-2012 to 31-06-2014.

MATERIAL AND METHODS: The present study consists of 22 adult patients of Intracapsular fracture neck of the femur, who are treated with Bipolar hemiarthroplasty in government general hospital, Vijayawada from 01-07-2012 to 31-06-2014. The patients were followed up at an interval of 6 weeks, 3 months and 6 months and their functional outcome assessed using Harris Hip score.

INCLUSION CRITERIA:

1. Patients with Intracapsular fracture neck of the femur with age >60 years.
2. Patients who were able to walk and live independently prior to the fracture.
3. A hip with no or minimal osteoarthritic changes.

EXCLUSION CRITERIA:

1. Age of the patient <60 years.
2. Neurological disorders that may significantly influence walking ability.
3. Pathological fractures secondary to malignant disease.
4. Concomitant other fractures.
5. Acute infections of the hip joint or anywhere systemically.
6. Very high surgical risk.

Once the patient was admitted to the hospital, all the essential information was recorded in the proforma prepared for this study. They were observed regularly during their hospital stay till they get discharged. They were asked to come for follow up regularly to the outpatient department. The follow up summary was recorded in the follow up chart of the proforma.

FOLLOW UP: At the time of discharge the patients were asked to come for follow up after 6 weeks and for further follow up at 3 months and 6 months. At follow up, detailed clinical

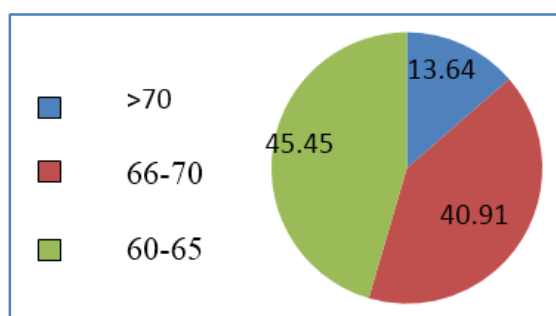
ORIGINAL ARTICLE

examination was done systematically. Patients were evaluated according to Harris hip scoring system for pain, limp, the use of support, walking distance, ability to climb stairs, ability to put on shoes and socks (in our study for some patients ability to cut toenail was enquired) sitting on chair, ability to enter public transportation, deformities, leg length discrepancy and movements. All the details were recorded in the follow up chart. The radiograph of the operated hip was taken at regular intervals, at each follow up.

OBSERVATIONS AND RESULTS: The average age of patients in our series range from 60 years to 75 years.

Age in years	No. of cases	Percentage
60-65	10	45.45
66-70	9	40.91
>70	3	13.64
Total	22	100

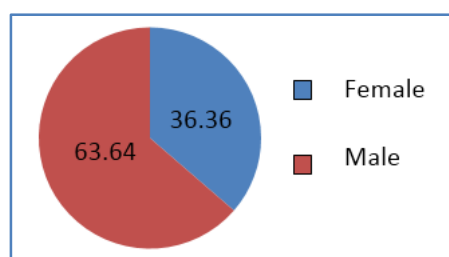
Table 1: Age incidence



Age Incidence (%)

	No. of cases	Percentage
Male	14	63.64
Female	8	36.36
Total	22	100

Table 2: Sex incidence

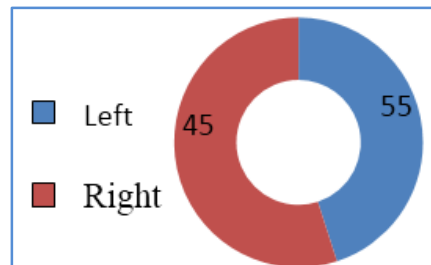


Sex Incidence (%)

ORIGINAL ARTICLE

	No. of cases	Percentage
Left	12	54.55
Right	10	45.45
Total	22	100

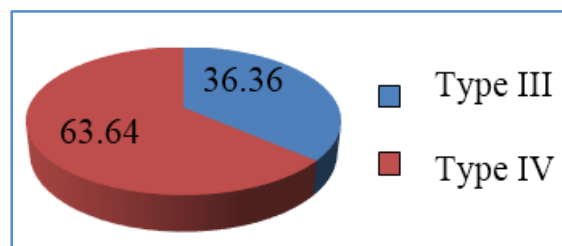
Table 3: Side Incidence



Side Incidence (%)

Type of Fracture	No. of Cases	Percentage
Type 3	8	36.36
Type 4	14	63.64
Total	22	100

Table 4: Type of Fracture (GARDEN'S CLASSIFICATION)

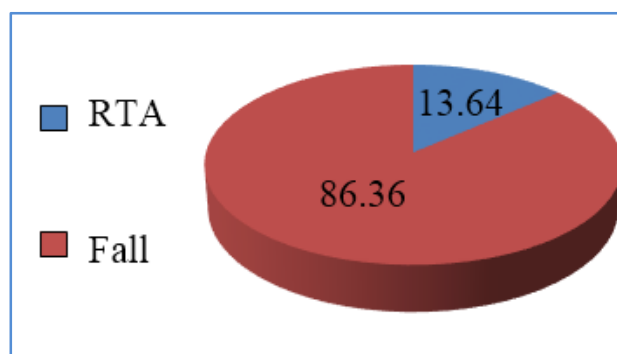


Type of Fracture

	No. of patients	Percentage
Fall due to slip	19	86.36
RTA	3	13.64
Total	22	100

Table 5: Mechanism of injury mechanism of injury

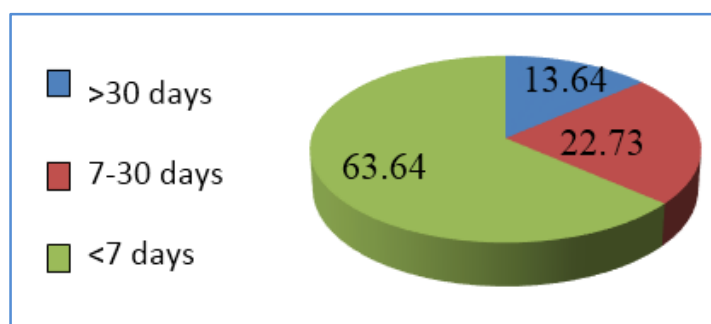
ORIGINAL ARTICLE



Mechanism of injury

Duration	No. of Patients	Percentage
<7 days	14	63.64
7-30 days	5	22.73
>30 days	3	13.64

Table 6: Interval between injury and admission

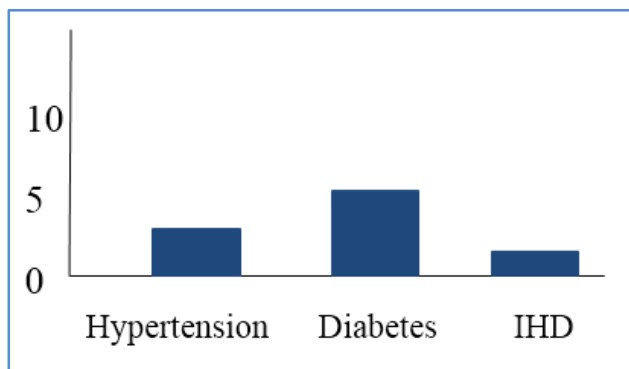


Interval of injury

Disease	No. of Patients	Percentage
Diabetes	4	18.18
Hypertension	6	27.27
Ischemic Heart disease	1	4.55

Table 7: Associated Diseases

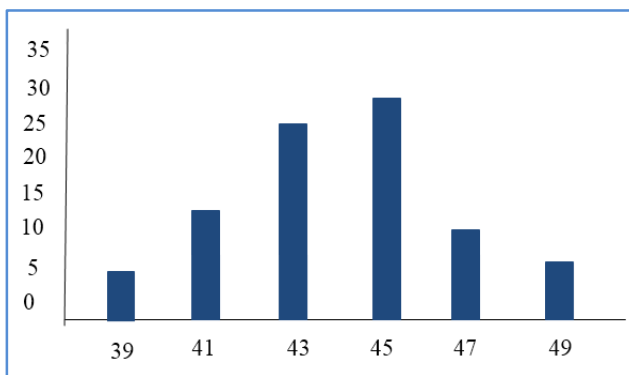
ORIGINAL ARTICLE



Associated Diseases

Head size	No. of Patients	Percentage
39	1	4.55
41	3	13.64
43	6	27.27
45	7	31.82
47	3	13.64
49	2	9.09

Table 8: Prosthesis sizes



Prosthesis sizes

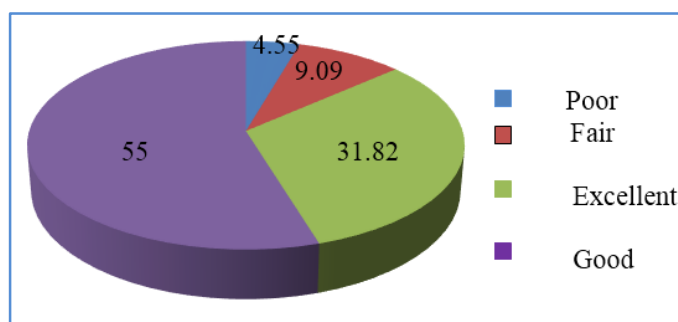
Complication	No. of Patients	Percentage
Superficial Infection	2	9.09
Deep Infection	0	0
Periprosthetic Fracture	0	0
Limb Length Discrepancy	2	9.09
Heterotopic Ossification	0	0

Table 9: Complications

ORIGINAL ARTICLE

Harris Hip score	Result	No. of cases	Percentage
>90	Excellent	7	31.82
80-90	Good	12	54.55
70-80	Fair	2	9.09
<70	Poor	1	4.54
	Total	22	100

Table 10: Outcome



Outcome

CONCLUSION AND SUMMARY:

- Hemiarthroplasty is a common procedure in the treatment of femoral neck fractures in elderly. Decision to perform hemiarthroplasty using either unipolar or bipolar prosthesis remains controversial with proponents on either side.
- Unipolar hemiarthroplasty has been shown to produce good results, though there is high incidence of erosion, protrusion and needs revision in future.
- The concept of dual bearing surfaces offers considerable advantage, it results in sharing of motion at the two surfaces and hence reduction of net wear at either surface, thus reducing erosion at the acetabular – joint interface. In addition, the total range of motion of joint is increased.
- From our relatively short-term prospective nonrandomized study, we conclude that bipolar hemiarthroplasty produces good functional outcomes with minimal complications for displaced intracapsular femoral neck fractures and has several advantages; these results are comparable to the other studies.

SUMMARY: This series consisted of 22 cases of intracapsular fracture neck femur treated surgically by Bipolar hemiarthroplasty. In the present study, out of the 22 patients 14 were females accounting to 63.64% and 8 were males making up the remaining 36.36%. Females are more affected than males. Age of all the patients in this study, ranged above 60 years. Majority of the patients were in the age group between 60 to 70 years. In this study group, left side (54.55%) was more commonly involved than the right (45.45%). The average interval between admission to the hospital and surgery was 4.5 days with a range of 2 to 15 days. The average

ORIGINAL ARTICLE

duration of hospital stay was 15 days with a range of 7 to 30 days. The commonest mode of injury occurred due to fall on a slippery floor (86.36%) and Road Traffic Accident (13.64%).

Harris hip score was used to evaluate the functional results. Using this rating scale, the functional outcome was measured. There were Seven patients (31.82%) with excellent results, Twelve patients (54.55%) with good results, Two patients (9.09%) with fair results and One patient (4.55%) with poor outcome.

DISCUSSION: In this context we undertook the present study to evaluate the immediate and early results of hemiarthroplasty in fracture neck of the femur using bipolar prosthesis keeping in view the living condition of an average Indian.

AGE DISTRIBUTION: The average age of our patients was 65.3 years. Majority of the patients were between 60-70 years. The physiological age of our patients is more than the chronological age and hence these patients are considered old for all practical purposes. Similar age distribution is reported by other authors.

STUDY	AGE DISTRIBUTION
Saxena & Saraf (1978) ^[7]	66 years
Mukherjee & Puri(1986) ^[8]	65 years
Nottage and Mc Master (1990) ^[9]	65 years
Garrahan and Madden (1990) ^[10]	66 years
La Belle et al (1990) ^[11]	72.5 years
Gallinaro et al (1990) ^[12]	75 years
Lestrangle (1990) ^[13]	79.4 years
Gupta et al (1994)	54 years

Table 11: studies showing age distribution

SEX DISTRIBUTION: In our series the intracapsular fracture of femoral neck were found to be more common in females. The elderly females are more prone to fracture neck of femur due to osteoporosis (Choudhari & Mohite, 1987).^[14] Female preponderance has been reported in several series.

Study	Percentage
Moore(1957) ^[4]	62.5%
Campbell (1960)	80.9%
Cone (1963)	73.6%
Anderson & Neilson (1972)	85%
Sikroski & Barrington(1981) ^[15]	66.7%
Arwade(1987)	68.3%
John E. Kenzora(1998) ^[16]	77.4%

Table 12: Studies showing female preponderance

ORIGINAL ARTICLE

SIDE OF FRACTURE: Left side is more affected than right in our series. Similar results were observed in several studies. Boyd and Salvatore, (1964)^[17] reported 55% fractures on left side. D'Acry and Devas, (1976)^[18] similarly found 55.4% fracture in left hip of their patients. In our series 54.55% of patients had left side fractures.

TYPE OF FRACTURE: All the fractures in our series belonged to displaced fractures of Garden Type III and IV. Depending on the anteroposterior radiographs available, we could group 8 patients (36.36%) into type III and 14 patients (63.64%) into Garden type IV. G.S. Kulkarni (1987)^[19] had grouped type III and type IV into one group of 'displaced fractures' and reported it in 82.5% of his patients. Mukherjee & Puri (1986)^[8] had 85% patients of Garden type III and IV fractures.

NATURE OF INJURY: 86.36% of our patients had trivial trauma and 13.64% of the cases of fracture were due to severe trauma like road traffic accidents. This is in accordance with majority of the series reported - [Gyepes, (1962), Solomon (1968), Evarts (1973),^[20] Seth (1987)^[21] etc.], several other authorities believe that the intracapsular fracture are stress fractures through pathological bone secondary to osteoporosis or osteomalacia.

TYPE OF PROSTHESIS: We have used the Uncemented Bipolar Hemiarthroplasty technique in all of our cases.

Some studies showed better clinical ratings with uncemented bipolar than cemented bipolar.^[22,23,24] The peri-operative variables like duration of 96 surgery, amount of blood loss, length of hospital stay and postoperative complications (DVT, chest infection, mortality) were found to be less in the uncemented prosthesis group. The size of prosthesis commonly used was 41 mm & 43 mm for female and 45 mm & 47 mm for male cases. The average duration of surgery was 75 min. The average blood loss in surgery was 300 ml. Other series show that cemented hemiarthroplasty is better than uncemented.^[25,26] These studies found that a cemented hemiarthroplasty led to less pain in the hip, improved return of mobility and a reduced hospital stay compared to an uncemented prosthesis.

HOSPITAL STAY: In our series hospital stay ranges from 7 days to 30 days with a mean average of 15 days.

We did not operate any patient as an emergency and all were thoroughly prepared before surgery. Fifty percent of our patients who had various medical problems could not be taken to surgery on the operation day available in the first week of their admission. Seventy-five percent of patients had prosthesis by first week of their admission to the hospital. Those patients who had no operative or post-operative complications were discharged once they were able to walk with support. About 70% of our patients could go home by second week. About 80% could go home within 3 weeks. Patients who developed complications such as infection, bedsores etc., in the post-operative period had to stay longer in the hospital. Early ambulation and comparatively less hospital stay following hemiarthroplasty has also been reported in other series. This is an advantageous factor in relation to economy of hospital beds and favors financial condition of the

ORIGINAL ARTICLE

patients. We also found that significant number of our patients who had come from rural areas could not come to the hospital soon after the injury. 22.73% of the patients were admitted 7 days after the fracture, where as 13.64% of the patients sought medical assistance after 1 month. Poverty, ignorance and difficulty in transportation of the patients to the hospital were the main explanations given for this delay.

COMPLICATIONS: The complications following the hemiarthroplasty for fracture neck of femur is reported in varying incidences. Moore (1957)^[5] reported 16.6% mortality; Stinchfield and Cooperman (1957) reported 4% dislocation, 6% fractures of the proximal femur. Temporary mental confusion was the commonest complication in the immediate post-operative period of Hinchey and Day (1964)^[27] series. Salvatti et al (1973)^[28] reported 14.3% mortality, 8.3% superficial infection in their patients. C. M. Robinson et al, (1994)^[26] reported 11% mortality within one year, 5% infection, 2% deep vein thrombosis and 3% dislocation in their series. We had no operative deaths in our series.

INFECTION: In our series 2 patients (9.09%) had superficial wound infection. One patient was diabetic. They developed signs of infection in the first week of operation. They were treated with proper antibiotics and dressings. These infections were found when the patients were still in the hospital and this resulted in prolongation of their hospital stay. The organisms isolated in the above cases were: *Staphylococcus aureus*. Gingras et al (1980) stated that infection was the devastating complication of hemiarthroplasty. Superficial infection could be successfully treated with antibiotics, local measures and drainage. Deep infections most of the time need removal of the prosthesis. Early deep infections may present as an acute, potentially fatal clinical course with septic shock to mild low grade pain in the thigh or groin (Salvatti et al (1974),^[29] Moore (1940),^[5] and Wood et al,(1980)^[30] have reported extremely high mortality following infection of the prosthesis. We had no mortality in our series.

DISLOCATION OF THE PROSTHESIS: Dislocation of the Bipolar prosthesis is a rare phenomenon. It has been reported in literature ranging from 1.1% at one year follow up to 5% at 20 years. However, in our series, no dislocation has occurred at final follow up. Salvatti et al. 1974)^[29] (believed that excessive postoperative flexion or rotation with hip adducted is the main cause for dislocation of the prosthesis and they also observed that dislocation was commonly caused while shifting the patients from the operation theatre to the ward. In 1998, John E. Kenzora et al.^[16] noted that all 6 dislocation in their series followed after posterior approach. Dislocation is a well-known complication of posterior approach. In our series, we had done 15 cases through posterior approach, but there was no dislocation. The dislocation rate following THR for subcapital fracture is probably of the order of 5-10% in this age group.^[31,32,33,34]

PERIPROSTHETIC FRACTURES: No patient in our series sustained Periprosthetic fracture. Hinchey and Day 104 (1964) emphasize that all fractures occur when the surgeon attempts to reduce the prosthesis.

ORIGINAL ARTICLE

PAINFUL PROSTHESIS: We observed that 16 patients (72.73%) in our series had no pain. Out of 6 patients who had slight pain, one patient had superficial infection and rest of the patients had no post-operative complication. Pain following hemiarthroplasty is a major concern. Approximately 20% of unipolar prostheses implanted in the mobile independent elderly need revising because of pain.^[31,32] Up to 50% of these revisions are required within 3 years. 115 Hinchey and Day^[27] in their series of 294 patients found pain following hemiarthroplasty in 22 patients in the early post-operative period. They could not find any definitive cause in them. They suspected poor muscle control as the probable cause of pain. The pain was mild to moderate and required 100 treatment. Lanceford, (1965)^[35] felt that the pain following hemiarthroplasty should not be the cause for condemning the procedure. He listed following causes for pain: Infection, improper prosthetic seating, metallic corrosion and tissue reaction, improper sized femoral head, contractures, periarticular ossification, toggle or acetabular wandering and redundant ligamentum teres. Pain was the main criteria for assessing the functional results in majority of the series.

Hinchey and Day (1964)^[27] reported the use of radiotherapy and intraarticular steroids. It relieved pain in 15 patients and failed to do so in 7. Intraarticular steroids gave relief in one patient. Revision arthroplasty was also reported in one patient. Active exercises of gluteal and quadriceps muscles relieved in 7 patients after a period of 8 to 20 months. Coventry (1964)^[34] recommended physiotherapy, local intraarticular steroids, revision, replacement, girdle stones arthroplasty and Milch Bachelor arthroplasty for painful prosthesis. Now total hip arthroplasty (Muller 1984) is the procedure of choice. Our 6 patients required treatment for pain. Four of them are partially relieved by analgesics. Two patients with slight pain were regularly on analgesics.

LIMPING AND USE OF CANE: Seven of our patients have varying degree of limping. All of them had slight limp. Limping is a common consequence of hemiarthroplasty in adults. Though two of them had mild limb-length discrepancy that was corrected with 101 shoe rise, the exact cause cannot be attributed to this. Alteration in the abductor mechanism due to excision of little more neck is the most probable cause [Saraf and Saxena, (1978)^[7] Hinchey and Day (1964).^[27] All the patients were asked to use a cane on the sound side regularly. This decreases load on the prosthetic head. Once the patient got enough endurance, they were advised to discard the cane. Stinchfield and Cooperman (1957) reported 14% of their patients using cane regularly. 16% of Barr and Donovan 34 (1964) series were using the cane always, 34% were using occasionally and 20% discarded it. Saraf and Saxena (1978)^[7] reported 52.7% patients using cane regularly, 23.1% occasionally and 21.8% were not using it. Our patients are comparable to this.

OTHER COMPLICATIONS: Polyethylene wear debris and metallosis causing failure of bipolar hemiarthroplasty were reported as isolated instances by Kim et al^[35] and Kobayashi et al^[36] respectively. In our study we did not find any case of Deep Vein thrombosis or Pulmonary Thromboembolism 121 and there was no mortality.

TOTAL FUNCTIONAL RESULTS: Various criteria were used to assess the functional results following hemiarthroplasty. How best the patient could be returned to the pre-fracture state has been the main criteria. In India, our customs demand squatting and sitting cross legged without

ORIGINAL ARTICLE

difficulty. To achieve this patient should have good range of flexion, abduction, adduction and external rotation at the hip and full flexion at the knee. The distance patient could walk with or without support and the amount of movements at the hip are the major factors determining results in the western series whereas ability to squat and sit cross-legged was principally emphasized by Indian series. The final results at final follow-up after hemiarthroplasty in our series were analyzed by modified Harris hip scoring system. 122 In our series, 7(31.82%) patients had excellent results with Harris Hip Score more than 90, 12(54.55%) patients had good results with 80 to 90 score, 2(9.09%) had fair results with score 70 to 80 and 1(4.55%) had poor results with score <70. The difference between excellent and good results is minimal and therefore they can be grouped together as satisfactory (good) results. The results are compared with the available western and Indian series where hemiarthroplasty was done for the treatment of fracture neck of femur in elderly patients. The satisfactory results in our series were 86.37%. Our results are comparable with other series: Hinchey and Day: 72.8%^[27]; Lanceford 81%^[35]; 80.3%; Salvatti et al: 57%^[29]; Saxena and Saraf: 90.9%^[7], Mukherjee: 78%^[8] Mean Harris Hip Score for Bateman's Bipolar prosthesis was 85 and for Unipolar hemiarthroplasty was 77 in other series 123 and in our series was 85.

REFERENCES:

1. Mark F. Swiontkowski et Al. Current concepts review of intracapsular fracture of hip. JBJs 1994; 76A: 129 -135.
2. Lu-Yao GL, Keller RB, Littenberg B, Wennberg JE. Outcomrs after fractures of the femoral neck: A meta-analysis of 106 reports. J Bone Joint Surg 1994; 76(A): 15-25.
3. Kenzora JE, Magaziner J, Hudson J, Hebel JR, Young Y, Hawkes W et al. Outcome after hemiarthroplasty for femoral neck fractures in the elderly. Clin Orthop. 1998; 348: 51-8.
4. Austin T. Moore: The self-locking metallic hip prosthesis. JBJs 1957; 39A: 811-27
5. Austin T. Moore and H.R. Bohlman: Metallic hip joint, a case report. JBJs 1963; 25: 688-92.
6. Bateman J. E: Single assembly total hip arthroplasty, preliminary report. Orthop Digest 1974; 15: 35-43.
7. Saxena P.S. and Saraf J.K. Moore Prosthesis in fracture neck of femur. Indian Journal of Orthopaedics 1978; Vol 12: 138-145.
8. Mukherjee D.L. (Col), Maj. Gen. H.C. Puri. Early hemiarthroplasty for fresh fractures of the neck of the femur in geriatric patients. Indian Journal of Surgery 1986; Vol. 48: 77-80.
9. Nottage WM and Mc Master WC. Comparison of Bipolar Iplants with Fixed – Neck prosthesis in Femoral – Neck Fractures. Clin Orthop Feb 1990; 251: 38.
10. WF Garrahan and EJ Madden, The long-stem bipolar prosthesis in surgery of the hip, Clin Orthop 1990; 251: 31.
11. LaBelle LW, Colwill JC, Swanson AB. Bateman bipolar hip arthroplasty for femoral neck fractures. Clin Orthop Relat Res. 1990; 251: 20–5.
12. Gallinaro P, Tabasso G, Negretto R, Brach del Prever EM: Experience with Clin Orthop 1990; 251: 26.

ORIGINAL ARTICLE

13. Lestrange NR. Bipolar arthroplasty for 496 hip fractures. Clin Orthop Relat Res. 1990; (251): 7–19
14. Choudhary and Mohite. Pathology of fracture neck of femur. Clinical Orthopaedics India 1987; Vol 1: 45-48
15. Sikorski J.M. and Barrington. Internal fixation versus hemiarthroplasty for the displaced subcapital fracture of femur: A prospective randomized study JBJS 1981; 63B: 357-361.
16. John E. Kenzora et Al. Outcome after hemiarthroplasty for fracture neck of femur in elderly. Clini Orthop.1998; 348:51-58.
17. Boyd H.B. and Salvatore J.E. Acute fractures of the femoral neck: Internal fixation or Prosthesis? JBJS 1964; 46A: 1066-1068. 112
18. D'Acry J., Devas M. Treatment of fractures of the femoral neck by replacement with the Thompson prosthesis. JBJS1976; 58B: 279-286
19. Kulkarni G.S. Pathology of fracture neck of the femur. Clinical Orthopaedics of India1987; Vol 1; 92-96.
20. Evarts C.M. Endoprosthesis as the primary treatment of femoral neck fractures. Clinc. Orthop.1973; 92: 69-76.
21. Seth M.K. (Col). Stress fractures of the neck of femur. Clinical Orthopaedics India1987; Vol 1: 105-109.
22. V Ramasamy; SN Sambandam et al - Comparision study of cemented versus uncemented bipolar hemiarthroplasty in fracture neck of femur Journal of Bone and Joint Surgery - British Volume, Vol 90-B, Issue SUPP_II, 302 - March 2006.
23. Hari P. Bezwada MD et al - Cementless bipolar hemiarthroplasty for displaced femoral neck fractures in the elderly - The Journal of Arthroplasty, Volume 19, Issue 7, Supplement 2, October 2004, Pages 73-77
24. M J Parker, G. Pryor, K. Gurussamy; cemented versus uncemented Hemiarthroplasty for intracapsular hip Fractures. A randomised controlled trial in 400 patients. J Bone Joint Surg [Br]. 92-B: 116-22. JANUARY 2010.
25. Parker MJ, Gurusamy K. Arthroplasties (with and without bone cement) for proximal femoral fractures in adults. (Cochrane Review). In: The Cochrane Library, Chichester: Wiley, 2008.
26. C.M. Robinson, D. Saran and I.H. Annan: Interacapsular hip fractures: Results of management adopting treatment protocol. Clini Orthop 1985; 160: 75 – 80.
27. Hinchey and Day. Primary prosthetic replacement in fresh femoral neck Fractures. JBJS1960; 42B: 633-640.
28. Salvatti E.A., Wilson P.O. Long term results of femoral head replacements JBJS 1972; 54A: 1355-1356.
29. Salvatti E.A., Artz T., Algeitti P., Asins S.E. Endoprosthesis in the treatment of femoral neck fractures. Orthop. clinc. North America 1974; 5: 757-777.
30. Wood M.R. Femoral head replacement following fractures. An analysis of the surgical approach. Injury 1980; 11: 317-320.

ORIGINAL ARTICLE

31. Lee BP, Berry DJ, Scott Harmsen W, Sim FH. Total hip arthroplasty for the treatment of an acute fracture of the femoral neck. Long term results. J Bone Joint Surg Am 1998; 80: 70–5.
32. Macted MJ, Denham RA. Failure of hemiarthroplasty for fractures of the neck of the femur. Injury. 1984; 15(4): 224–226
33. Squires B, Bannister G. Displaced intracapsular neck of femur fractures in mobile independent patients: total hip replacement or hemiarthroplasty?. Injury. 1999; 30(5): 345–348.
34. Coventry M.B. Salvage of the painful hip prosthesis JBJS 1964; 46A: 200-217.
35. H EKim KJ, Rubash HE. Et al. JArthroplasty. 1997; 12: 32-39.
36. Kobayashi S, Takaoka K, Tsukada A, Ueno M, Arch Orthop trauma Surg, 117:390-1, 1998.

AUTHORS:

1. P. Pavan Kumar
2. K. Ashok Naidu

PARTICULARS OF CONTRIBUTORS:

1. Assistant Professor, Department of Orthopaedics, Government Siddartha Medical College.
2. Post Graduate, Department of Orthopaedics, Government General Hospital, Vijayawada, Andhra Pradesh.

NAME ADDRESS EMAIL ID OF THE CORRESPONDING AUTHOR:

Dr. P. Pavan Kumar,
29-23-4, Soujanya,
Tadepallivari Street,
Surya Rao Pet, Vijayawada-520002.
E-mail: orthopavan@gmail.com

Date of Submission: 23/02/2015.

Date of Peer Review: 24/02/2015.

Date of Acceptance: 05/03/2015.

Date of Publishing: 13/03/2015.