

**CLINICAL AND ETIOLOGICAL PROFILE OF PATIENTS WITH LUNG ABSCESS AT A TERTIARY CARE CENTRE**Manoj Kumar Agrawal<sup>1</sup>, Amit Kumar<sup>2</sup>, Sanjay Bansal<sup>3</sup>, Ankit Khurana<sup>4</sup>**HOW TO CITE THIS ARTICLE:**

Manoj Kumar Agrawal, Amit Kumar, Sanjay Bansal, Ankit Khurana. "Clinical and Etiological Profile of Patients with Lung Abscess at a Tertiary Care Centre". Journal of Evidence based Medicine and Healthcare; Volume 2, Issue 44, November 02, 2015; Page: 7923-7930, DOI: 10.18410/jebmh/2015/1066

**ABSTRACT: BACKGROUND:** Lung abscess is a type of liquefactive necrosis of the lung tissue and formation of cavities (more than 2 cm) containing necrotic debris or fluid caused by microbial infection. This pus-filled cavity is often caused by aspiration, which may occur during altered consciousness. **OBJECTIVE:** To study the clinical and etiological profile of lung abscess in patients admitted at a tertiary care centre. **MATERIAL AND METHODS:** A prospective study was conducted on 142 cases with age more than 15 years, who were the suspected cases of lung abscess and the cases with evidence of lung abscess on the X-ray, CT scan presented to the OPD/ IPD clinic, Department of Pulmonary Medicine, Rohilkhand Medical College and Hospital (RMCH), Bareilly from January 2013 to December 2014 were included in the study. **RESULTS:** out of 142 patients enrolled in the study, 47(33.09%) belonged to age group of >60 years followed by 42(29.57%) belong to 41- 60 years of age. 116(81.6%) were male and 26(18.3%) were female. The most frequent symptom was cough (92.95%), followed by expectoration (91.54%), fever (87.32%) and hemoptysis (41.5%). **CONCLUSION:** In our study conducted, data collection shows that lung abscess was more seen in the elderly and male patients 116(81.6%) as compared to female patients 26(18.3%). Majority of the patients had a risk factor of smoking, dental diseases, altered sensorium, comatose patients, alcohol, diabetes, on steroid therapy and immunocompromised immune status. The following were the major symptoms in our patients:- Cough (92.95%), expectoration (91.54%), Fever(87.32%), Foul smell (66.90%), Chest pain (58.45%), Hemoptysis (41.5%), Impaired consciousness (29.57%). In our study locus of lesion was more prominently on right side i.e. 101 patients (71.12%) as compared to 36 (25.35%), while lung abscess was seen bilateral in 5 patients (3.5%). Primary lung abscess is a common presentation amongst the patients with the periodontal diseases, seizure disorders, coma patients, tuberculosis, and dysphagia. The patients are counseled for postural drainage to harbor the culture and respiratory specimens obtained from patients with cavitory lung lesions for bacteria, mycobacteria, and fungi is first wise step in assessing the etiology of a cavity. In those patients in which sputum can't be obtained can be considered for bronchoscopy for the collection of BAL for further evaluation process.

**KEYWORDS:** Lung abscess, Etiological type, Anaerobic.

**INTRODUCTION:** Lung abscess is a type of liquefactive necrosis of pulmonary tissue and formation of cavities (more than 2cm) containing necrotic debris or fluid caused by bacterial infection.<sup>[1]</sup> Lung abscesses are divided according to their duration into acute (6weeks) and chronic (>6weeks).<sup>[2]</sup> The term primary lung abscess generally used when an abscess develops in individuals prone to aspiration or individuals in relatively good health. Secondary lung abscess

## ORIGINAL ARTICLE

indicates an obstruction in the airways neoplasma, a complication of intrathoracic surgery, or a systemic condition or treatment that compromises host defense mechanisms, such as human immunodeficiency virus (HIV) infection or transplantation immunosuppressive therapy. Primary lung abscess caused by mouth flora anaerobic bacteria usually present in a sub-acute or indolent fashion with symptoms present for several weeks or longer.<sup>[3]</sup>

Poor dental hygiene allows for a high-tittered inoculum with aspiration. Anaerobic abscess is uncommon in the edentulous patient unless there is a predisposing pulmonary disorder.<sup>[4]</sup> Predisposing pulmonary disorders include bronchogenic carcinoma or other bronchial obstructions, bronchiectasis, and pulmonary infarction. Common pathogens include *Staphylococcus aureus*, *Klebsiella* species, and *Pseudomonas aeruginosa*, group A streptococcus, *Streptococcus pneumoniae*, *Nocardia*, mycobacteria, parasites and fungi.<sup>[5]</sup>

Diagnosis is by chest radiography showing a lung cavity with an air-fluid level, computed tomography(CT) is more sensitive than radiography.<sup>[6,7]</sup> The predominant organisms responsible for lung abscess are bacteria, specifically mouth anaerobes that are normal flora in gingival cervices.<sup>[3]</sup> David Smith in his classic studies of lung abscess was able to produce typical lung abscesses with an inoculum containing 4 microbes that are thought to have been an anaerobic spirochete, *Fusobacteriumnucleatum*, *Paptostreptococcus* species, and a fastidious gram-negative anaerobe (possibly *prevotellamelaninogenicus*).<sup>[8]</sup>

Hence, this study was done to evaluate the clinical and etiological profile of patients with Lung abscess.

**MATERIAL AND METHODS:** This study was conducted on patients with lung abscess visiting department of Pulmonary Medicine at OPD/ IPD of Rohilkhand Medical College and Hospital, Bareilly.

Institutional Ethical Committee permission was taken before starting the study and informed written consent was taken from every patient.

A prospective study was conducted on 142 cases with age more than 15 years who were suspected cases of lung abscess and the cases with evidence of lung abscess on the X-ray, CT scan presented to the OPD/ IPD, Department of Pulmonary Medicine, Rohilkhand Medical College and Hospital, Bareilly from January 2013 to December 2014 were included in the study.

A detailed clinical data was noted in predesigned data sheet and sputum was sent for complete analysis, to evaluate the clinical and etiological profile of lung abscess. Other relevant investigations were carried out as per need.

Results of this study were analyzed by using SPSS Software version 16.

### RESULTS:

Parameters	No. of patients (n=142)	Percentage
<b>Age group</b>		
15-20 years	17	11.97%
21-40 years	36	25.35%
41-60 years	42	29.57%
> 60 years	47	33.09%

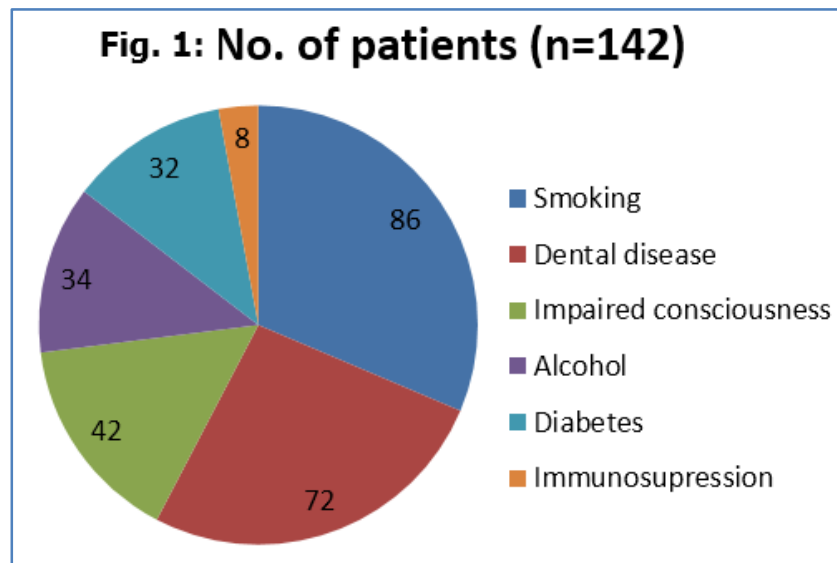
## ORIGINAL ARTICLE

Sex		
Male	116	81.6%
Female	26	18.3%

**Table 1: Demographic profile of the patients**

Risk factors	No. of patients (n=142)	Percentage
Smoking	86	60.56%
Dental disease	72	50.07%
Impaired consciousness	42	29.57%
Alcohol	34	23.94%
Diabetes	32	22.5%
Immunosuppression	8	5.6%

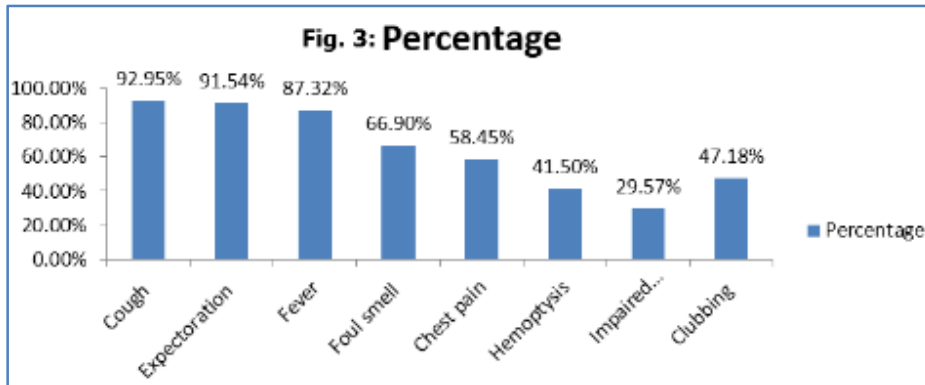
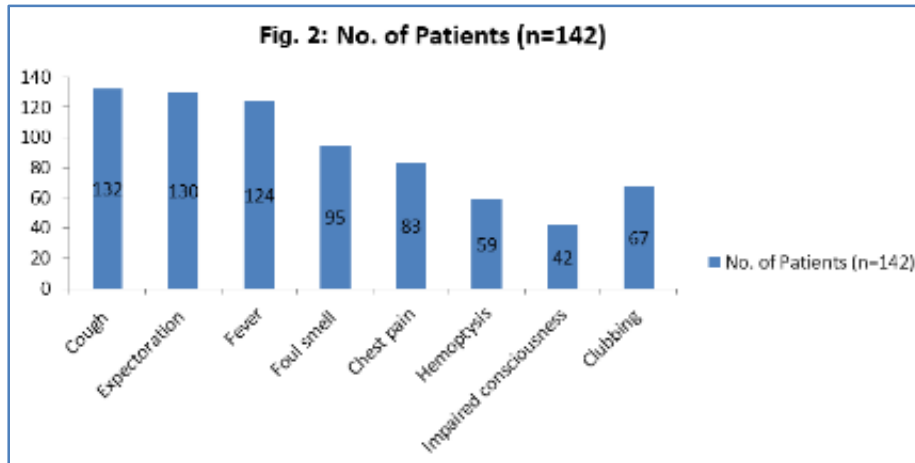
**Table 2: Risk Factors**



Symptom	No. of Patients (n=142)	Percentage
Cough	132	92.95%
Expectoration	130	91.54%
Fever	124	87.32%
Foul smell	95	66.90%
Chest pain	83	58.45%
Hemoptysis	59	41.5%
Impaired consciousness	42	29.57%
Clubbing	67	47.18%

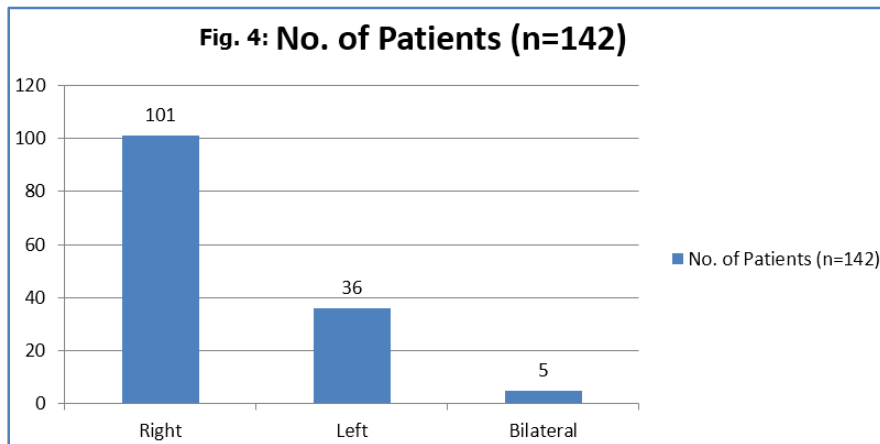
**Table 3: Clinical profile of patients with Lung abscess**

# ORIGINAL ARTICLE

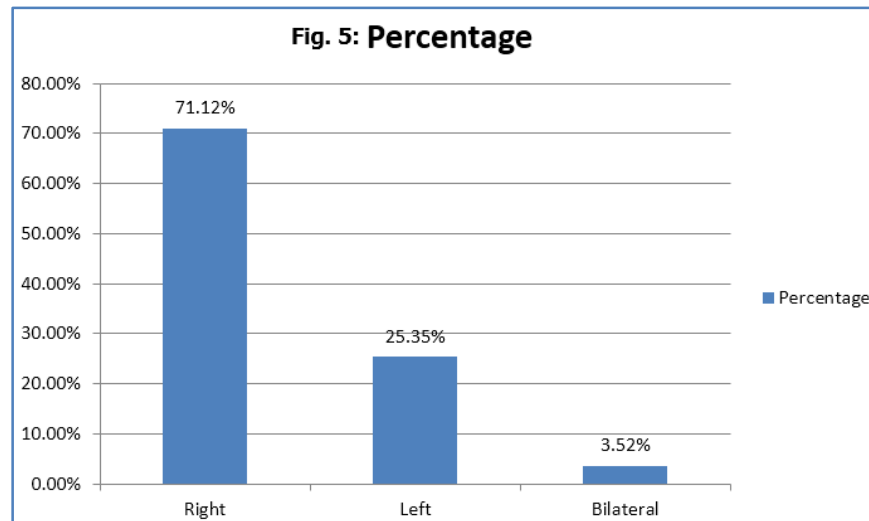


Site	No. of Patients (n=142)	Percentage
Right	101	71.12%
Left	36	25.35%
Bilateral	5	3.52%

Table 4: Site of involvement

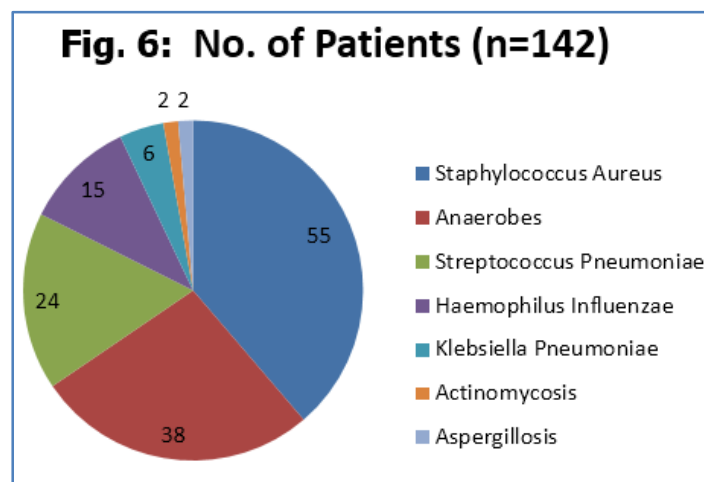


# ORIGINAL ARTICLE



Etiological Agent	No. of Patients (n=142)	Percentage
Staphylococcus Aureus	55	39%
Anaerobes	38	27%
Streptococcus Pneumoniae	24	17%
Haemophilus Influenzae	15	11%
Klebsiella Pneumoniae	06	04%
Actinomycosis	02	01%
Aspergillosis	02	01%

Table 5: Etiology of Lung abscess



## DISCUSSION:

- Primary lung abscess is a common presentation amongst the patients with the periodontal diseases, seizure disorders, coma patients, tuberculosis, Dysphagia. Other patients at high risk for developing lung abscess include individuals with an inability to protect their airways

## ORIGINAL ARTICLE

---

from massive aspiration because of a diminished gag or cough reflex, caused by a state of impaired consciousness (eg, from alcohol or other CNS depressants, general anesthesia, or encephalopathy).

- The following infectious etiologies of pneumonia may progress to parenchymal necrosis and lung abscess formation:
- *S aureus* (may result in multiple abscesses).
- *Streptococcus pneumoniae*.
- *Pseudomonas aeruginosa*.
- *K pneumoniae*.
- *Actinomyces* species.
- Fungal species.

In our study conducted, data collection shows that lung abscess was more seen in the elderly and male patients 116(81.6%) as compared to female patients 26(18.3%). Majority of the patients had a risk factor of smoking, dental diseases, altered sensorium, comatosed patients, alcohol, diabetes, on steroid therapy and immunocompromised immune status.

In our study locus of lesion was more prominently on right side ie. 101 patients (71.12%) as compared to 36(25.35%), while lung abscess was seen bilateral in 5 patients (3.5%).

In our study the etiological profile of the lung abscess in the cases studied is as follows *Staphylococcus Aureus* (39%), *Anaerobes* (27%), *Streptococcus Pneumoniae* (17%), *Haemophilus Influenzae* (11%), *KlebsiellaPneumoniae* (4%), *Actinomycosis* (1%), *Aspergillosis* (1%).

The following were the major symptoms like Cough (92.95%), Expectoration (91.54%), Fever (87.32%), Foul smell (66.90%), Chest pain (58.45%), Hemoptysis (41.5%), Impaired consciousness (29.57%).

However in the studied patients, the patients were treated with antibiotics as per the culture sensitivity, abscess resolved in the majority of the patients, thus lowering the morbidity and mortality in the patients of the lung abscess.

- An abscess may develop as an infectious complication of a preexisting bulla or lung cyst.
- An abscess may develop secondary to carcinoma of the bronchus. The bronchial obstruction causes post obstructive pneumonia, which may lead to abscess formation.

Once the Lung Abscess is suspected a complete set of Laboratory Studies has to be done. A complete white blood cell count with differential count may reveal leukocytosis and a left shift. Furthermore sputum for Gram stain, culture, and sensitivity has to be done. If tuberculosis is suspected, acid-fast bacilli stain and mycobacterial culture is requested. Purified protein derivative (PPD) skin testing, quantiferon gold testing, ANCA, and perhaps a serum ACE level and fungal serologies may also be considered. Blood culture may be helpful in establishing the etiology. Obtain sputum for ova and parasite whenever a parasitic cause for lung abscess is suspected.

On radiological examination a typical chest radiographic appearance of a lung abscess is an irregularly shaped cavity with an air-fluid level. Lung abscesses as a result of aspiration most frequently occur in the posterior segments of the upper lobes or the superior segments of the lower lobes.

## ORIGINAL ARTICLE

---

The wall thickness of a lung abscess progresses from thick to thin and from ill-defined to well-circumscribed as the surrounding lung infection resolves. The cavity wall can be smooth or ragged but is less commonly nodular, which raises the possibility of cavitating carcinoma.

The extent of the air-fluid level within a lung abscess is often the same in posteroanterior or lateral views. The abscess may extend to the pleural surface, in which case it forms acute angles with the pleural surface. Anaerobic infection may be suggested by cavitation within a dense segmental consolidation in the dependent lung zones.

Lung infection with a virulent organism results in more widespread tissue necrosis, which facilitates progression of underlying infection to pulmonary gangrene. CT scanning of the lungs may help visualize the anatomy better than chest radiography. CT scanning is very useful in the identification of concomitant empyema or lung infarction.

**CONCLUSION:** To conclude the study, we obtained a significant data depicting that the major cause for the lung abscess presenting at a tertiary health care centre is *Staphylococcus Aureus* (39%) followed by Anaerobes (27%) and *Streptococcus Pneumoniae* (17%).

It was further concluded that the spectrum of infectious and noninfectious processes associated with pulmonary cavities is confusing and a difficult task to achieve, but it is a wiser approach to narrow the differential diagnosis which can be done thoroughly investigating the patient's history and radiographic data. It is important to understand the concurrent immune status of the patient to assess the relative probability of a given process producing lung cavities.

Associated clinical and radiographic features may be helpful in moving a given process to the top of the differential. Radiographic studies must be supplemented by focused microbiological and pathological evaluations of affected sites, considering likely pathogens.

The patients are counselled for postural drainage to harbor the culture and respiratory specimens obtained from patients with cavitary lung lesions for bacteria, mycobacteria, and fungi is first wise step in assessing the etiology of a cavity. In those patients in which sputum can't be obtained can be considered for bronchoscopy for the collection of BAL for further evaluation process.

Now this specimen obtained can be further tested for bacteriological culture and sensitivity for further evaluation and Laboratory testing, including blood cultures, antigen tests, antibody tests, and nucleic acid amplification, is useful when such testing is focused on likely processes and the test characteristics are taken into consideration.

### REFERENCES:

1. Bartlett JG, Finegold SM. Anaerobic pleuropneumonia infections. *Medicine (Baltimore)*. 1972; 51(6): 413-50.
2. Doherty G, Companies M. Current diagnosis and treatment surgery. McGraw Hill Professional. 2009/ISBN: 0071590870.
3. Bartlett JG. Anaerobic bacterial infection of the lung and the pleural space. *Clin Infect Dis*. 1993; 16(Suppl4): S248-S255.
4. Finegold SM. Lung abscess. In Mandell GL, Bennett JE, Dolin R, eds. *Principles and Practice of Infectious Diseases*, 5th ed. Philadelphia: Churchill Livingstone, 2000: 751-55.

## ORIGINAL ARTICLE

5. Leatherman JW, Iber C, Davies SF. Cavitation in bacteremic pneumococcal pneumonia: Casual role of mixed infection with anaerobic bacteria. *Am Rev Respir Dis.* 1984; 129: 317-21.
6. Mansharmani N, Balachandran D, Delaney D, et al. Lung abscess in adults: Clinical comparison of immune compromised to non-immune compromised patients. *Respir Med.* 2002; 96: 178-85.
7. Stark DD, Fedrele MP, Goodman PC, et al. Differentiating lung abscess from empyema: radiology and computed tomography. *AJR Am J Roentgenol.* 1983; 141: 163-68.
8. Smith DT. Fuso-spirochetal disease of the lungs. *Tubercle.* 1928; 9: 420.

### **AUTHORS:**

1. Manoj Kumar Agrawal
2. Amit Kumar
3. Sanjay Bansal
4. Ankit Khurana

### **PARTICULARS OF CONTRIBUTORS:**

1. Assistant Professor, Department of Pulmonary Medicine, Rohilkhand Medical College & Hospital, Bareilly.
2. Assistant Professor, Department of Pulmonary Medicine, Rohilkhand Medical College & Hospital, Bareilly.
3. Professor & HOD, Department of Pulmonary Medicine, Rohilkhand Medical College & Hospital, Bareilly.

4. Junior Resident, Department of Pulmonary Medicine, Rohilkhand Medical College & Hospital, Bareilly.

### **NAME ADDRESS EMAIL ID OF THE CORRESPONDING AUTHOR:**

Dr. Manoj Kumar Agrawal,  
P-3/55, Deen Dayal Puram,  
Bareilly-243001,  
Uttar Pradesh, India.  
E-mail: drmanojtilhar@gmail.com

Date of Submission: 05/10/2015.

Date of Peer Review: 06/10/2015.

Date of Acceptance: 14/10/2015.

Date of Publishing: 28/10/2015.